GYNA 1

GYNA

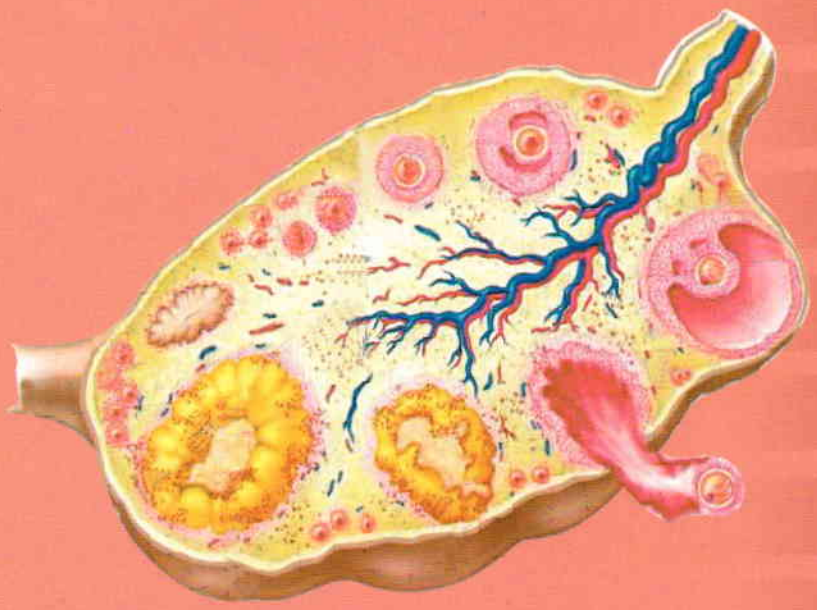

GYNA 1

CONTENTS

Amenorrhea

Endometriosis

Infertility

Anatomy of the female genital system

External Genitalia (vulva = pudendum)

The Vulva consists of 10 parts:

1- Mons Pubis (Mons Veneris نسبه الي فينوس اله الجمال عند الاغريق)

- It is **pad of fat** covered with hair over the symphysis Pubis.
- It acts as a **cushion** وساده that absorbs the pressure during sexual intercourse
- The upper limit of this hair (**the escutcheon®**)
  - ⇨ In ♀ → **straight** upper border (feminine criterion)
  - ⇨ in ♂ **extends to the umbilicus** (Δ in shape)
- Even in severe **cachexia** it doesn't disappear® .

2- Labia Majora (single: labium majus):

- **2 longitudinal elliptical skin folds (containing fat)**:
  - ⇨ ANTERIORLY: extend from the mons pubis.
  - ⇨ POSTERIORLY: extends to perineum, unite يلتقوا → **posterior commissure** الالتقاء الخلفي
- **Skin**:
  - ⇨ It is covered by hair
  - ⇨ It contains **sebaceous** & **sweat** glands (some of them are ***apocrine*** →produces characteristic odor attracts males)
- Occasionally contains the **canal of Nuck** (a fold of peritoneum)
- It corresponds to the **scrotum** in male.

3- Labia Minora (= nymphae, single labium minus):

1. 2 folds internal to labia majora of **non keratinized skin** حساس جدا
   - ✌THIN REDUNDANT (no fat خلي بالك, no hair follicle® contain sebaceous & few sweat glands)
   - ✌PINK COLORED (vascular connective tissue)
2. Anterior: divides to anterior flap (**prepuce** غطاء) & posterior flap (**frenulum**)
3. Posterior: unite to form **fourchette** (*French of fork*)
4. **Fossa navicularis** (in virgins only): between fourchette & hymen.
5. If too large = ***spanial ear nymphae*** & it is indication of **labial reduction**

4- Clitoris (2- 3 cm) (= the hidden or the key وان كان له اسماء كتير):

- **Sensitive** (↑nerve endings) & **erectile** (↑ vascular supply) tissue
- 2-3 cm above the urethra **(important relation in intersex)**

لاحظ هنا خط مستقيم

Mons pubis

prepuce

clitoris

labia majora

Frenulum

labia minora

hymen

crescentic

cribriform

septate

Fringed

The vestibule

Fossa navicularis

Fourchette

الالتقاء الخلفي

Post. Commissure

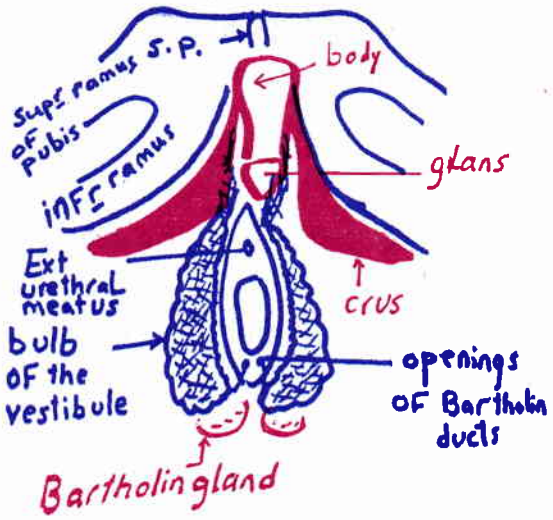

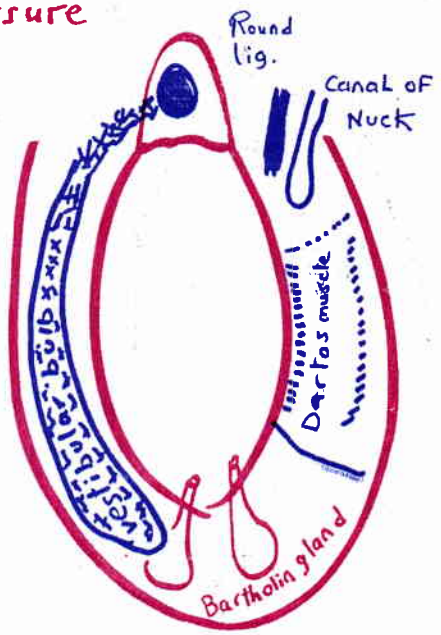

- It is formed of :
  - ⇨ 2 **crura** جذور attached to the pubis by suspensory ligaments
  - ⇨ **Body** (formed of 2 Corpora Cavernosa)
  - ⇨ ending in **Glans** (between the prepuce & frenulum)

5- The Vestibule: Labia Minora ما بين ال

- The **area®** between the labia minora
- The vagina, urethra, 2 Bartholin ducts اربع فتحات → open into it

6- External Urethral Meatus (3-4 cm)

- **Site:**
  - ⇨ Seen by separating the labia minora لازم & opens in the vestibule.
- **Lining:**
  - ⇨ **Transitional** epithelium except the distal 1/3 → **stratified sq®**.
- **Skene's glands**: two paraurethral glands open in the floor of the urethra (**1cm before the external urethral meatus**).

7- The Hymen

- A (**relatively avascular** خلي بالك) membrane.
- It is covered by stratified squamous epithelium on both sides.
- It partially closes the vaginal orifice.
- **Forms** ☺: **annular** (commonest®), crescentic, septate (biperforate), cribriform, fringed هدبي imperforate hymen or congenitally absent
- Torn with 1st coitus (with slight hemorrhage if ↑ed = **defloration injury due to injury of descending cervical artery**) unless large opening or elastic
- **After labor**; its remnant are called **Caranculae Myrtiforms**

8- Bartholin's gland مهمه نظري= the greater vestibular glands

- **Nature:**
  - ⇨ Bilateral **racemose** glands (pea sized not felt except if diseased)
- **Site:**
  - ⇨ In the **vestibular bulbs** (posterior ⅓ of labia majora on both sides)
  - ⇨ **Duct** (2-3 cm) opens in the vestibule at 5, 7 o'clock
- **Lining:**
  - ⇨ **the gland** → columnar, **the duct** → transitional epithelium
- **Function**: produces alkaline mucous during coitus for lubrication

9- The perineal body see later

urethra تفتح ال
papilla على قمة

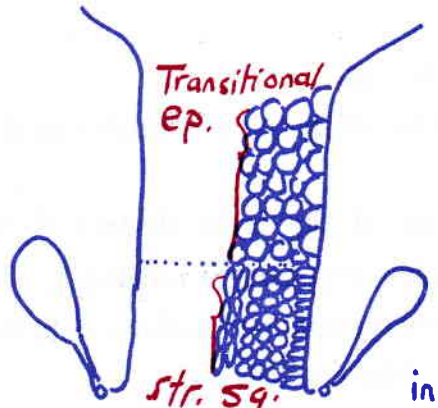

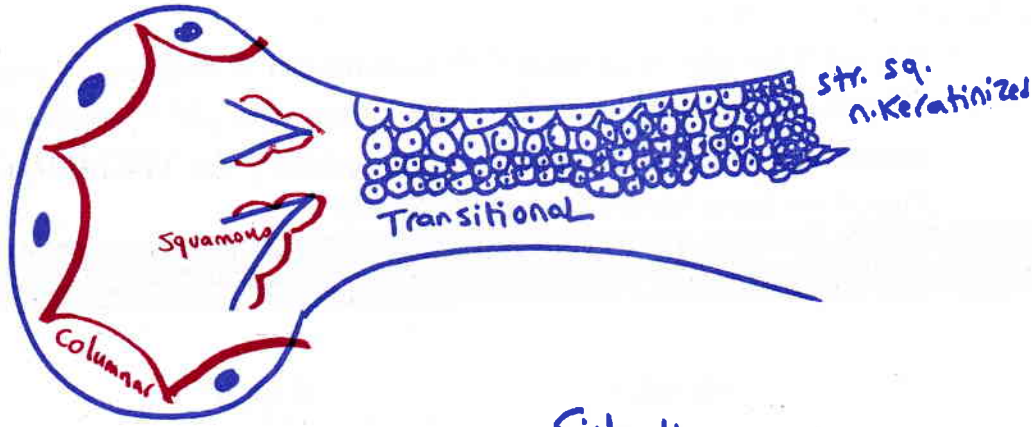

lining of Bartholin
غلاف داخلي
لبيتة
ط اسم عالم

10- Vestibular Bulbs:

- **Nature**: Two collection of erectile vascular spongy tissue
- **Site**:
  - Deep in the **labia majora** & deep to the **bulbospongiosus** muscle (=*sphincter vaginae*),
  - They are continuous above with the clitoris.
- **Function**: coital cushion.

Blood supply:

- **Arteries® ☺:**
  - **Internal pudendal (mainly) a** branch of internal iliac artery
  - **External pudendal** (superficial & deep branches) arise of femoral artery®
- **Veins:**
  - Accompany corresponding arteries
  - Join vesical and vaginal plexuses

Nerve supply® :

- **Pudendal nerve (main sensory and motor)**
- **Also sensory from:**

1- Perineal branch of lateral & posterior (not anterior®) cutaneous nerve of thigh
2- Genital branch of genitor femoral nerve
3- Ilioinguinal & iliohypogastric

Lymphatic drainage:

- It drains to the superficial inguinal → deep inguinal → deep femoral (including Cloquet LN) → external & common iliac → paraaortic LN → cisterna chyli → thoracic duct → left subclavian vein & left supraclavicular (**VIRCHOW**) LN.
- The clitoris drains into the Cloquet LN directly

list the different parts of the Vulva and their anatomical characteristics.

♀	♂
Labia Majora	Scrotum
Labia Minora	Ventral aspect of the Penis
Clitoris	Penis
Skene's gland	Prostate
Ovaries	Testes
Bartholin glands	Cowper's gland

Blood supply

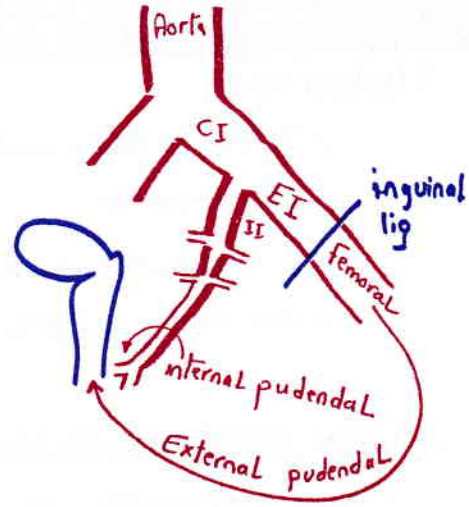

lymph drainage

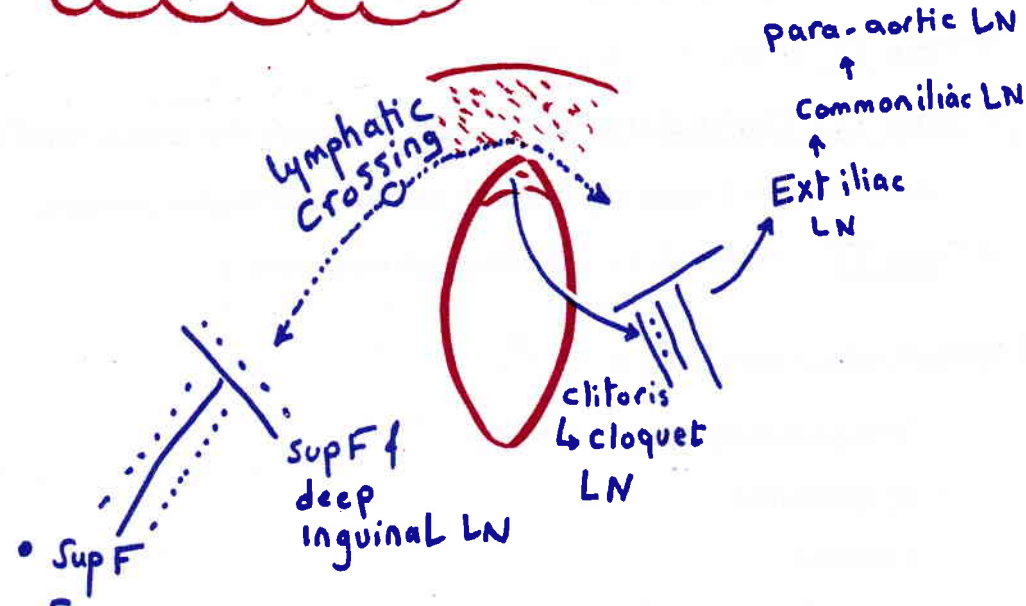

• Deep Femoral LN (inside the Femoral Sheath)

Female Circumcision اسم قديم
Female genital mutilation الاسم الجديد

Definition:

- Partial or total excision of external genitalia for
  - social or
  - religious cause
- but not due to therapeutic cause

(مازالت تجري في مصر والسودان بس وهي ممنوعه بالقانون)

Types (WHO classification)

- **Type I (True®):** only cut the Prepuce ± excision of whole or Part of the clitoris = male circumcision.
- **Type II:** as above + labia minora.
- **Type III (Infibulation®):** (Sudanese) remove the clitoris, labia minora & suture labia majora together with narrowing of vaginal introitus.
- **Type IV:** unclassified e.g piercing, tattooing, burning.

Indications: large labia cause :

- ✓ **Nymphomania** زياده الرغبه الجنسيه
- ✓ **Dyspareunia**
- ✓ **Cosmetic**

Otherwise it is totally condemned by WHO.

Complications سؤال لوحدها:

- **Immediate**: severe pain (up to neurogenic shock), hemorrhage, infection & damage to the urethra and vagina
- **Delayed**: fibrosis, **if extensive it may interfere with sexual intercourse & delivery** مهمه, dermoid cyst, neuroma, recurrent urinary tract infections & psychological.

Female Genital Mutilation

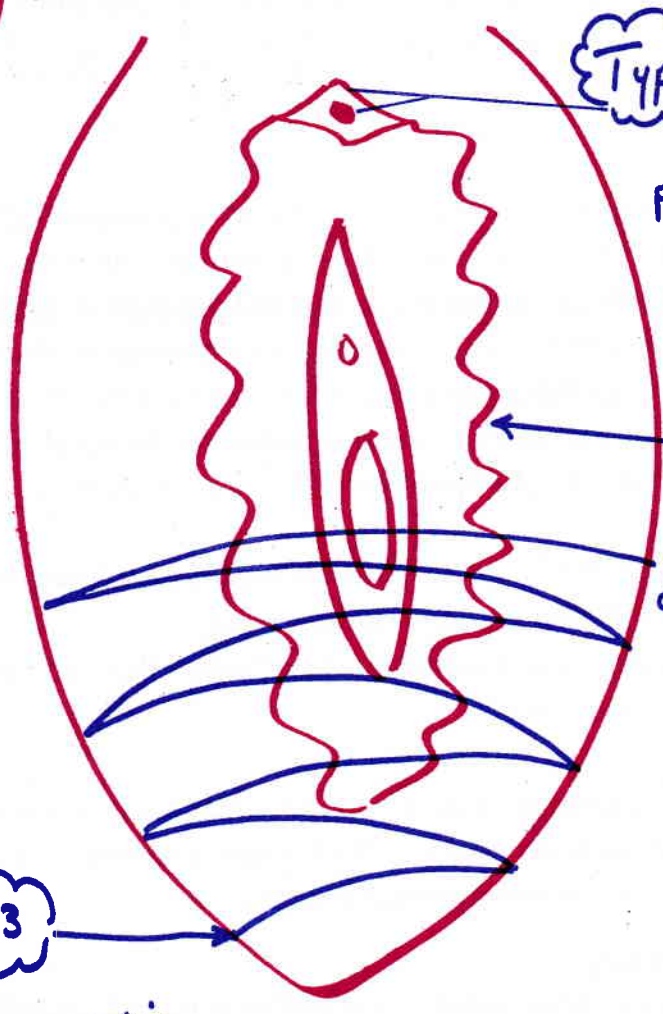

Type 1

نشيل

prepuce ± clitoris

Type 2

نشيل

Labia minora

Type 3

نشيل اللى فات

+

labia majora نخيط

Type 4

unclassified

Internal genitalia

The Vagina

- It is fibro-muscular canal, extending from the vulva to the uterus.
- It is partially closed by the hymen in virgins
- The cervix protrudes into vagina → 4 fornices: shallow anterior, deep posterior & 2 equal lateral®

STRUCTURE:

Mucosa:

- Stratified sq. nonkeratinized epith., elevated into **rugae** (allow distension) & deepens into sulci which deepen in anterior wall forming: **Submeatal sulcus**, **Transverse vaginal septum** & **bladder sulcus**
- The epithelium (under ↑ Estrogen) stores glycogen which is worked by **lactobacillus of Döderlein** to produce lactic acid (P^H 3.8-4.2).
- **The amount of glycogen is proportional to the level of estrogen:**
  - **Prepubertal & postmenopausal**: the acidity is low (PH7), no glycogen + thin
  - **In adult**: the PH is 3.8 – 4.2 (high acidity) + glycogen + thick

Submucosa: layer of elastic fibers (lamina propia).

Muscle layer: made of outer longitudinal and inner circular fibers.

Outer connective tissue sheath.

SHAPE

- **Transverse section:H** shaped in middle part (it is a potential space)
- **Longitudinal section**: inverted flask shape in young female
- Tent خيمه like in postmenopausal females

VAGINAL SECRETIONS

- Formed of **serous transudate, cervical mucus + Bartholin Secretions**
- No glands except if exposed inutero to diethylstilbosterol = vaginal adenosis®☺

RELATIONS OF THE VAGINA

- **Anterior wall (8 cm):** Bladder (upper 2/3), Urethra & Paraurethral glands
- **Posterior wall (10 cm)**
  - Upper ⅓ → peritoneum & Douglas pouch
  - Middle ⅓ → Rectum
  - Lower ⅓ → Perineal body

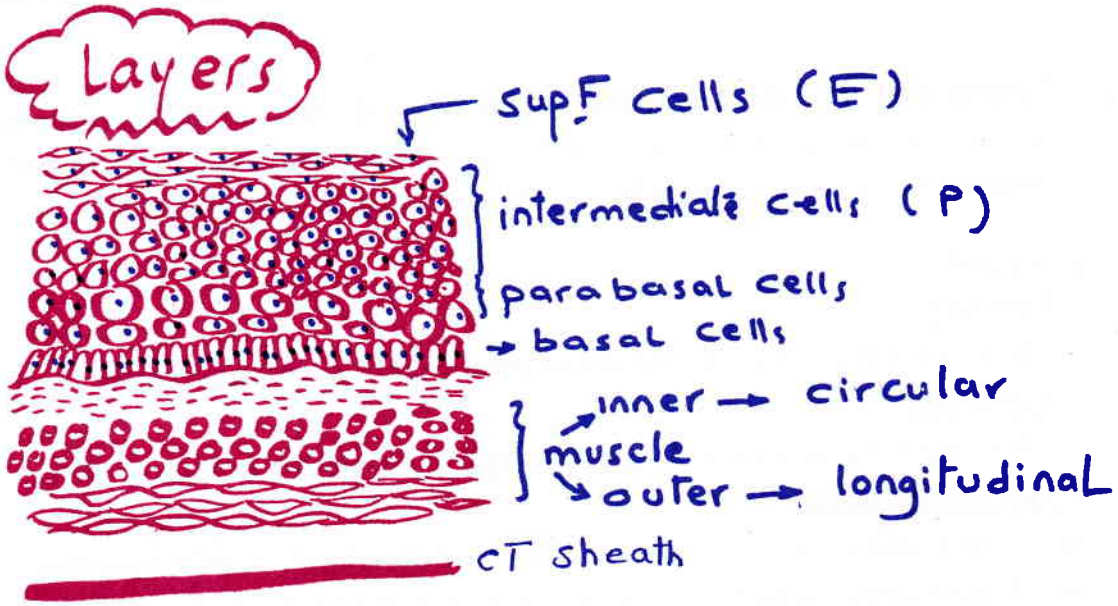

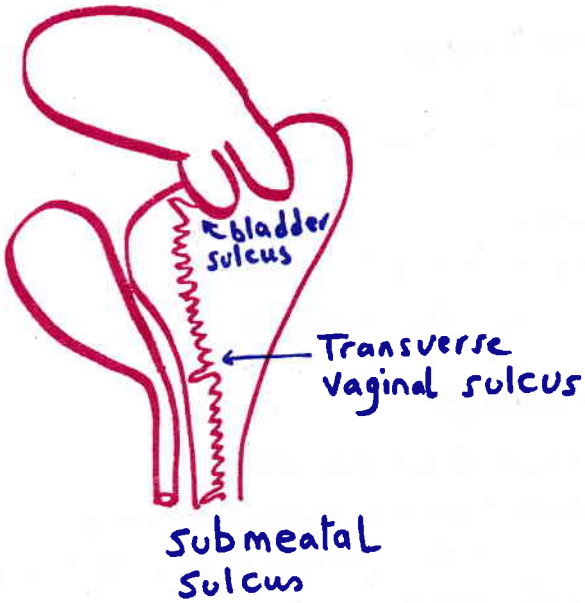

vagina لاحظ شكل
(inverted flask)

بالعرض شكل H-Shaped



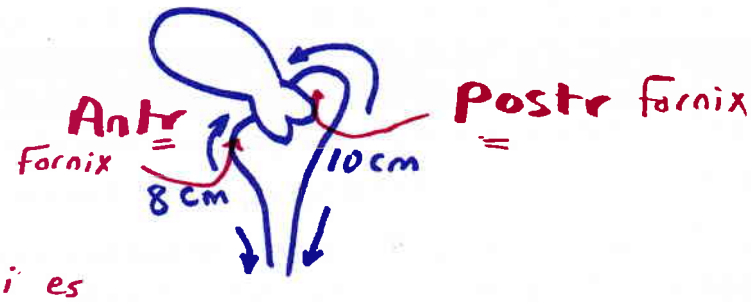

equal lateral fornices

- **Lateral wall ✍: Ureter ®** passes 1½ cm above & lateral to the lateral fornix, cardinal ligament, pelvic cellular tissue, levator-ani muscle, uro-genital diaphragm, vestibular bulb, bulbo-cavernosus muscle & Bartholin gland.

✍ SUPPORT

1. **Anterior:**
   - ♣ Attachment to the Cx, Pubocervical ligament & urinary bladder
2. **Posterior:**
   - ♣ Attachment to the Cx, Uterosacral lig. & Pelvic floor "levator ani"
3. **The vaginal axis:**
   - ♣ **Lower part**: passes upward & backward making 45°with the horizon.
   - ♣ **Upper part:** turns backward & horizontal resting on the levator ani.

✍ LYMPHATIC DRAINAGE OF THE VAGINA

- ⊙ **Upper 2/3 of the Vagina** → as Cervix.
- ⊙ **Lower 1/3 of the Vagina** → as Vulva.

✍ NERVE SUPPLY TO THE VAGINA

- ⊙ **Upper 2/3 of the Vagina** → insensitive as uterus.
- ⊙ **Lower 1/3 of the Vagina** → as Vulva (Pudendal nerve)

✍ ARTERIAL SUPPLY OF THE VAGINA

- **Internal iliac artery: Vaginal, middle rectal artery.**
- **Internal Pudendal artery & its branch inferior rectal artery**
- **Uterine a.** gives circular artery of the cx → ant. & post. Azygos arteries &descending cervical a (**cervicovaginal a.**).
- All are branches of anterior division of internal iliac, so in uncontrollable hemorrhage, bilateral ligation of internal iliac artery is done.

✍ **VENOUS DRAINAGE:** Plexus of veins communicate with the vesical & hemorroidal plexuses and drains into the iliac veins.

What is Di-Ethyl Stilbosterol ?

It is 1st synthetic E, it was given to pregnant female having abortion, DM, PE to ↓ fetal losses. 2-3 millions pregnant female received this drug 1950- 1970

At 1971 was proved that this drug is teratogenic &carcinogenic (produces vaginal clear cell adenocarcinoma peak at 19 y old.)

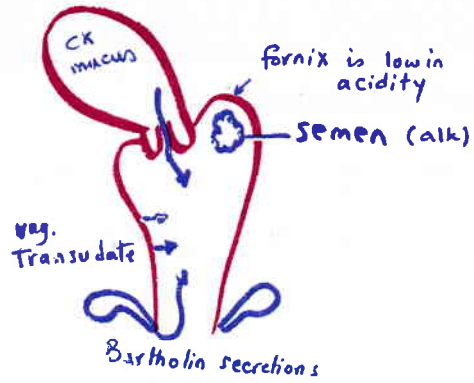

(How to combat vaginal acidity)

(Source of vaginal Secretions)

Relations of The vagina

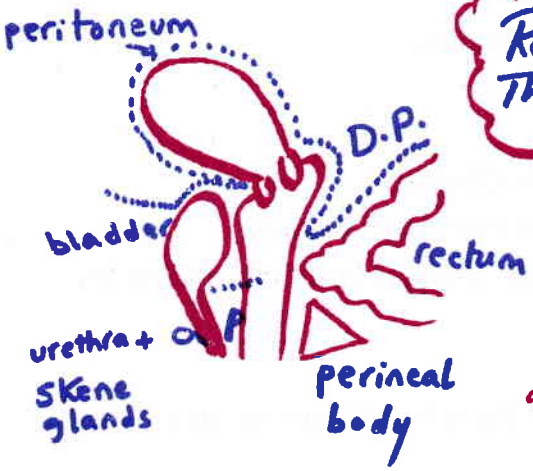

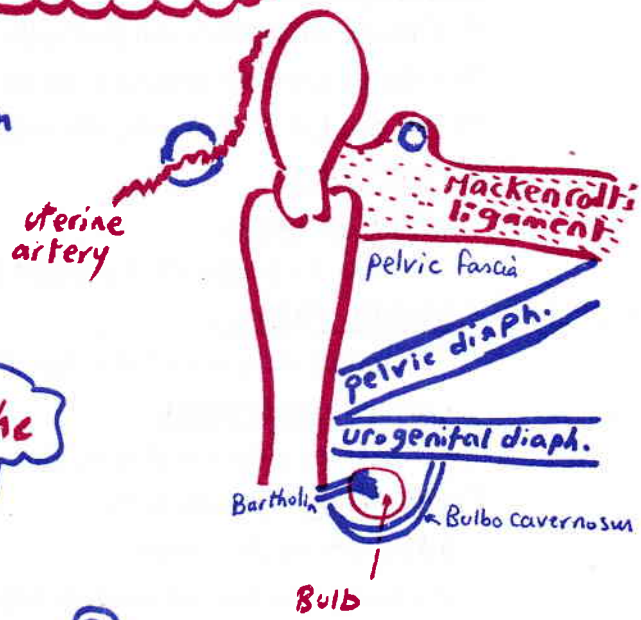

Support of the vagina

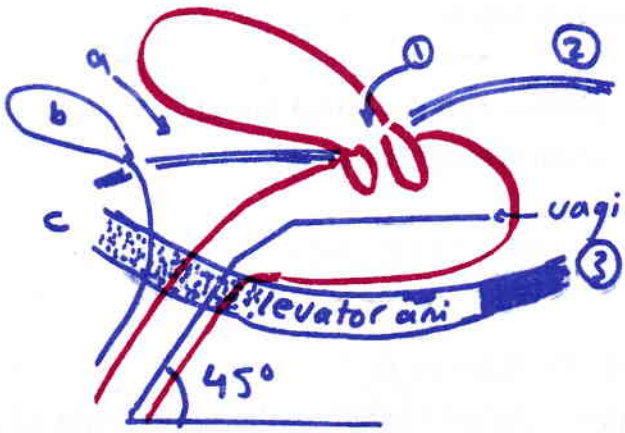

Antr support

a. pubo cx lig & cx
b. bladder
c. L. ani

posty support

1- cx
2- utero sacral lig
3- L. ani

- The Uterus -

- **Hollow pear shaped muscular organ flattened A-P**

- **Dimensions:**
  - NG 3 x 2 x 1 inches (= 50 g)®
  - MP 3½ x 2½ x 1½ inches (= 75 g)®

- **Formed of three parts:**

  - ***Body (upper 2/3 = corpus = 2 inches = الجسم)***

- **Cornu** is the site of insertion of the tube
- The part above the cornu, is called the **fundus**
- **LAYERS OF THE WALL ARE:**
  - **Endometrium:**
    - Columnar epithelium partially ciliated
    - Glands (simple tubular), stroma & blood vessels
    - All are E& P sensitive →cyclic changes (endometrial cycle)
  - **Myometrium**

    Inner circular:
    - Acts as a sphincter around the tubes & internal os (3 sites)

    Middle oblique:
    - makes a figure of 8 around vessels→ hemostatic

    Outer longitudinal:
    - acts as a pacemaker of the uterus
  - **Perimetrium** = peritoneum
    - **adherent** to the corpus
    - It covers the corpus **completely®** اماما وخلفا.
    - It is reflected :

      a) anteriorly on the bladder (**uterovesical pouch**)

      b) Reflects on the rectum (**Douglas pouch**)

  - ***The Isthmus 3-5 mm المضيق***

- **IT LIES BETWEEN**
  - **Anatomical internal OS**(Above) &
  - **Histological internal OS**(below) which is the upper limit of the endocervical mucosa

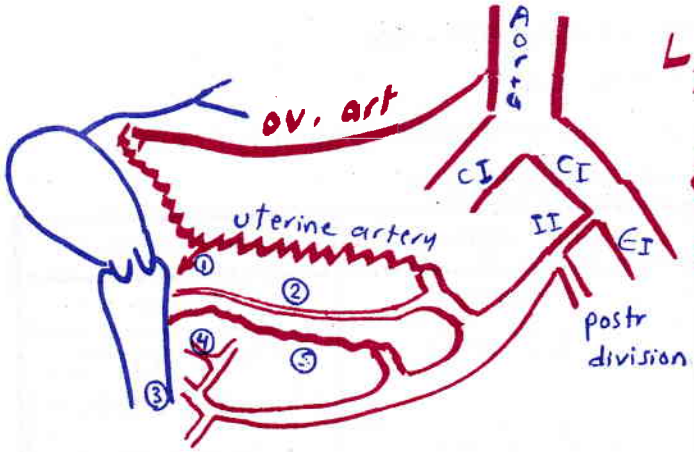

Blood supply of the vagina

1- vaginal branch of uterine a.
2- vaginal artery of int. iliac a.
3- internal pudendal a.
4- inferior rectal a.
5- Middle rectal a.

Antr division of Int. iliac artery

الخمسه طالعين من

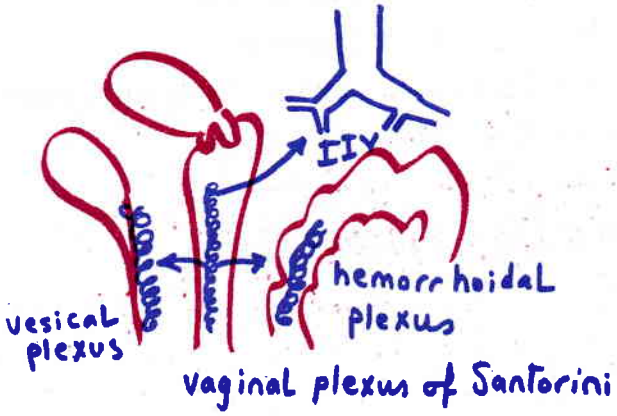

The uterus

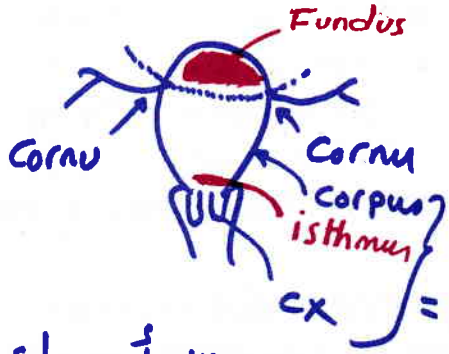

Cornu الجزء اللي موجود

Fundus اسمه

= uterus ٣ أجزاء خلي بالك

- It's lined by **modified endometrium** ضعيف
- It is covered by **loose** peritoneum☺
- It forms the **lower** uterine segment during pregnancy (10 cm)
- IT DIFFERS FROM THE UPPER SEGMENT IN

	Upper segment	Lower segment
Peritoneum	Adherent	Loose
Muscle	Thick (3 layers)	Thin (2 layers) No middle oblique®
Deciduas	Well developed	Less developed
Membranes	Firmly adherent	Loosely adherent
Action	Active in labor (contracts & retracts)	Passive (dilates & stretches)

- PHYSIOLOGICAL RETRACTION RING:
  - It is a **groove** between:
    - The **upper** (thickened) upper uterine segment &
    - **Lower** (stretched & thinned) uterine segment.
  - **Normally**, it is not felt or seen because it`s below the symph. pubis.
  - **D.D**.: pathological retraction ring & contraction ring.

○ *The Cervix (lower 1/3 = 1 inch عنق الرحم)*

- Fusiform in shape

✌ 2 OS:
- Internal OS 3-4 mm®
- External OS:
  - It is at the level of ischial spine®,
  - Shape مهم جدا:
    - Rounded in nullipara
    - Slit in MP

✌ THE CERVIX IS DIVIDED INTO 2 PARTS BY THE ATTACHMENT OF THE VAGINA
- **Supravaginal part** = endocervix,
  - The epithelium:
    - Tall columnar partially ciliated epithelium
    - Interrupted by low cuboidal cells.

Layers of the Corpus

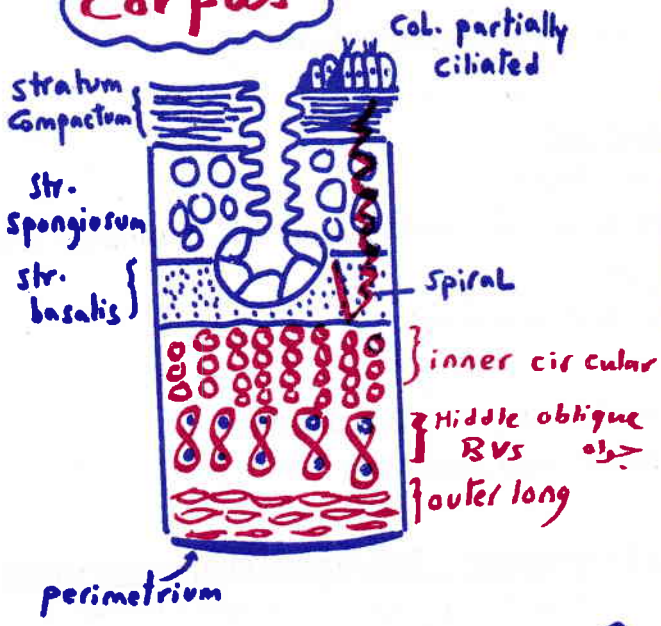

The perimetrium

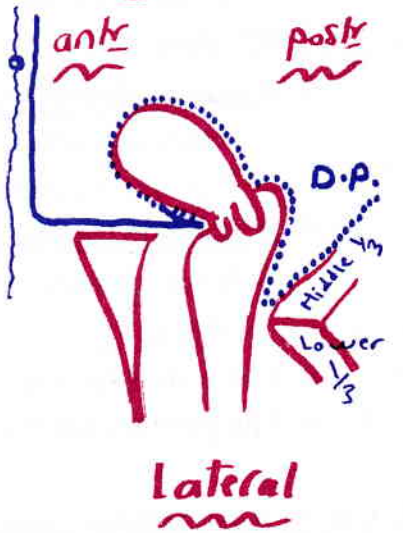
<antr
postr
D.P.
Middle 1/3
Lower 1/3
Lateral

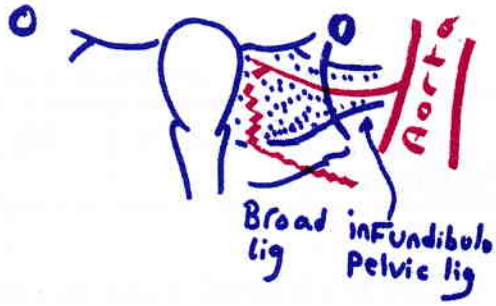
<antr>
Aorta
Broad lig
infundibulo Pelvic lig

The cervix

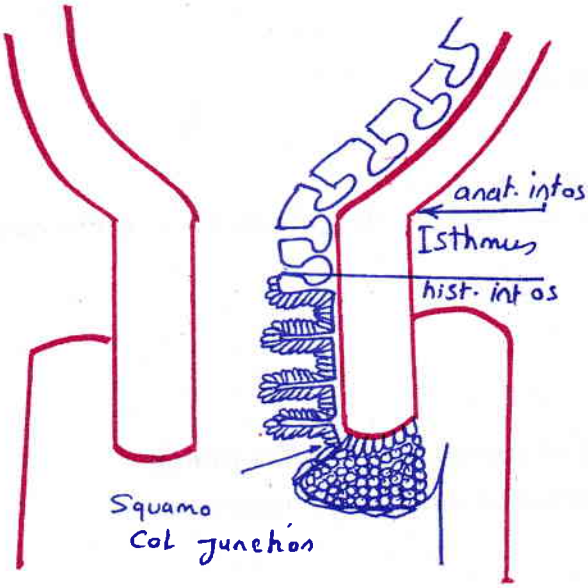
anat. intos
Isthmus
hist. int os
Squamo Col junction

Arbor vitae: a median vertical ridge from which Tr. Folds radiate on both the antr & postr surfaces of the canal.

- ⇨ The mucosa is folded (**arbor vitae** شجره الحياه= grooves & crypts) forming the cervical glands.

- **Portio-vaginalis** = ectocx
  - ⇨ lined by stratified squamous epithelium

2 JUNCTIONS:

- **Squamocolumnar junction:**
  - ⇨ Between ectocx & endocx
  - ⇨ It is not a constant point بتطلع وتنزل→ forms transformation zone
- **Histological internal os:**
  - ⇨ Between endocx & endometrium

2 STRUCTURES

- **The wall** is formed of 90% collagen & 10% muscles
- **The peritoneum** ® covers it only posteriorly مهمه

N.B. Cervix is not sensitive except to dilataion → Neurogenic shock (vasovagal)

في البنج بيدوا Atropine قبل التوسيع في D & C

❖ The relation between the body & the cervix

	Intrauterine	*Child*	*Before puberty*	*adult*	*menopause*
CX: uterus	5:1	2:1	1:1	1:2	Corpus shrinks > CX

❖ The peritoneal coat of the uterus

- **Anterior**:
  - ⇨ Not covering the vagina or cervix
  - ⇨ Loose on the isthmus
  - ⇨ Firmly attached to the corpus.
  - ⇨ Reflects on the superior surface of the bladder → **utero-vesical pouch**
- **Posterior** :
  - ⇨ Covers the cx,
  - ⇨ Upper 1/3 of the vagina
  - ⇨ Reflects on the middle 1/3 of rectum → **Douglas pouch**
  - ⇨ The lower 1/3 of rectum is not covered by peritoneum.
- **Laterally:**
  - ⇨ It forms the broad ligament

Functions of cervical mucus :-

1- Bacteriostatic

2- prevents ascending infection

3- During pregnancy → cx plug

4- Sperm Capacitation.

5- Tests of Ovulation.

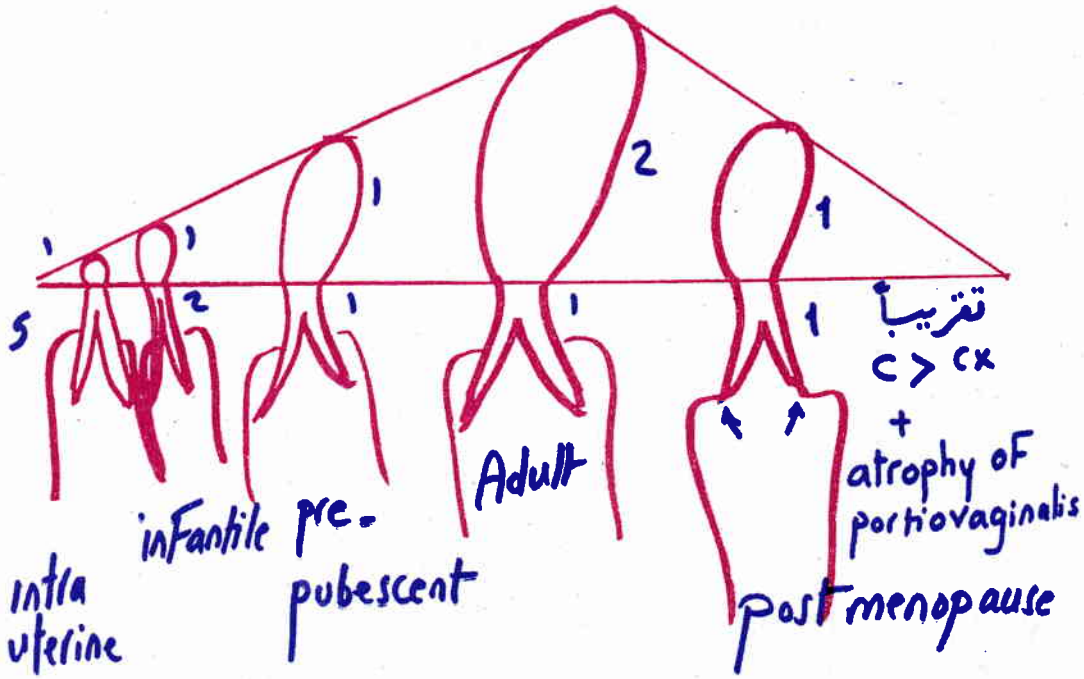

❖ BLOOD SUPPLY OF THE UTERUS

⇨ ARTERIAL SUPPLY

Uterine Artery حفظ صم:

- Branch of the anterior division of **Internal Iliac Artery**
- Crosses in front of the ureter **(water under the bridge** مهمه) lateral to the supra-vaginal cervix
- Then runs upwards to the lateral border of the uterus till **cornu** to anastomose with the **ovarian arteries**.
- Uterine arteries are **tortuous** (to allow ↑ in size of uterus during pregnancy without decrease in blood flow).
- Branches:
  1. Vaginal branches.
  2. Cervical branches which meet in midline to give
     - A. **Anteriorly**: anterior azygos
     - B. **Posteriorly**: posterior azygos
  3. Uterine (ascending) branch → arcuate → perforating branches → straight & spiral arteries of the endometrium.

Ovarian Artery: Anastomoses with the uterine artery at the cornu.

⇨ Venous drainage:

- **Pampiniform plexus** in broad ligament → uterine & ovarian veins

❖ LYMPH DRAINAGE OF THE UTERUS مهمه جدا

⇨ The cervix:

1. Para-cervical nodes.
2. Internal & external nodes.
3. Sacral nodes.
4. Obturator nodes.
5. Then to 2nd relay LN (common iliac) then to para-aortic LN.

⇨ The body:

1. Lower 1/3: as cervix
2. Middle 1/3: Internal iliac lymph nodes.
3. Upper 1/3: The fundus drains to the para-aortic.
4. The cornu drains to the inguinal LN.

❖ NERVE SUPPLY OF THE UTERUS

- **Para-sympathetic (pelvic nerves):** sacral 2, 3, 4
- **Sympathetic (hypogastric plexus):** T5-L1

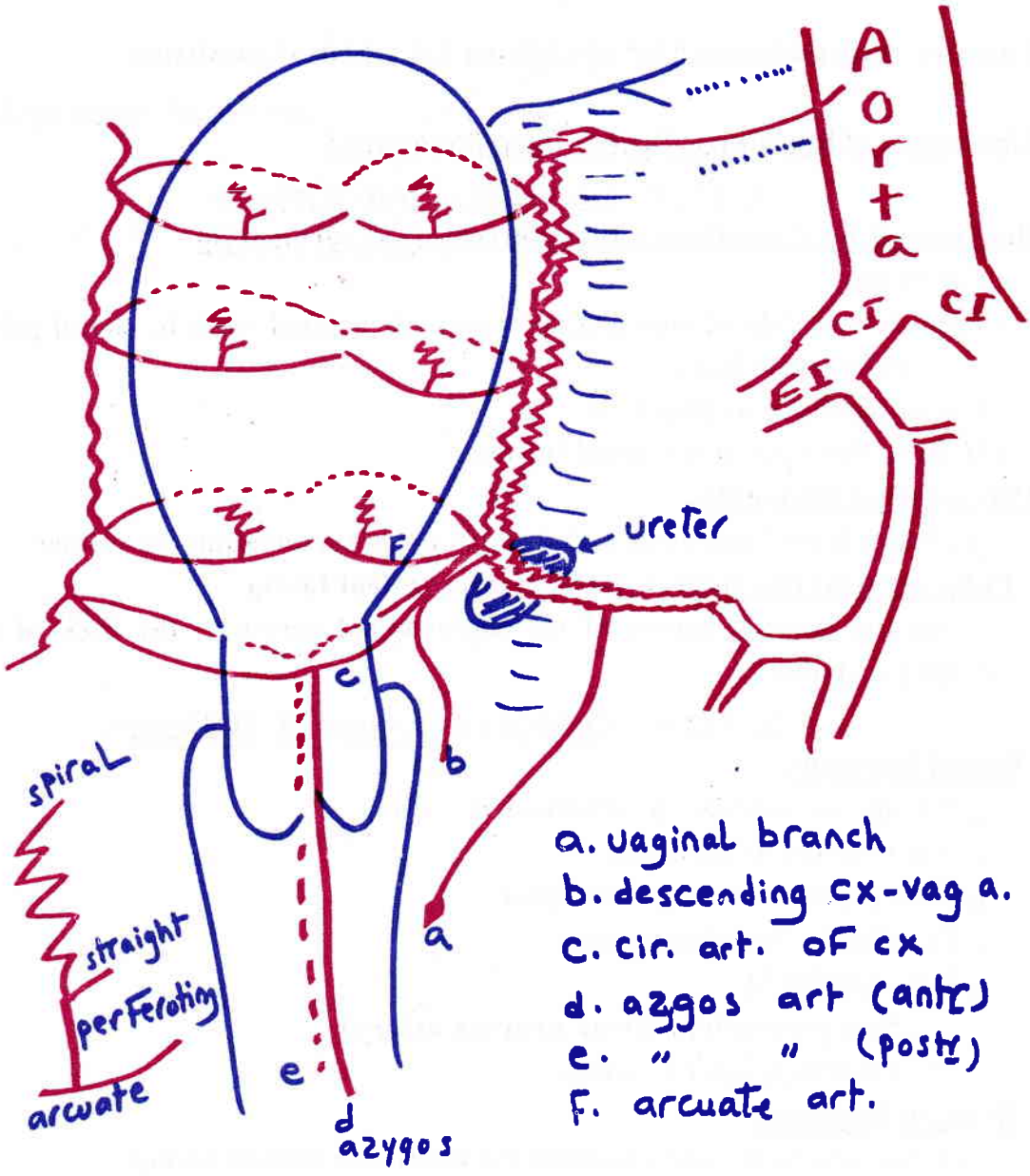

a. vaginal branch
b. descending cx-vag a.
c. cir. art. of cx
d. azygos art (antr)
e. " " (postr)
f. arcuate art.

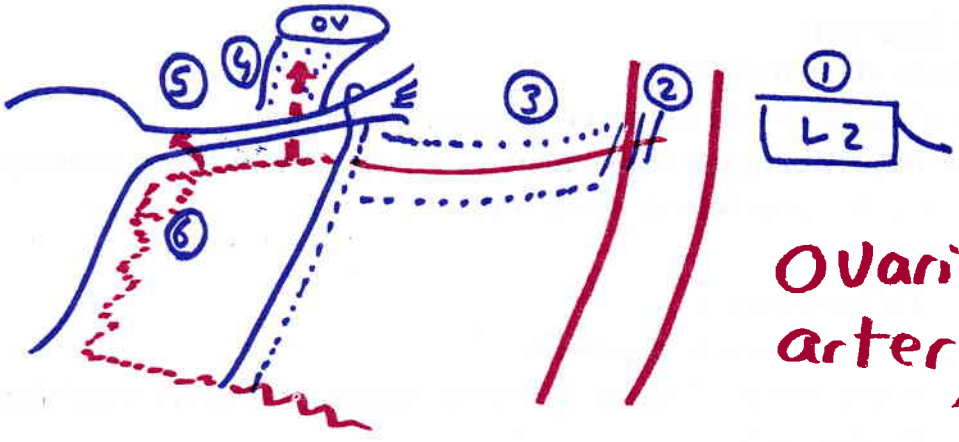

Ovarian artery

Factors maintaining the uterus in its normal position

سؤال مهم وتجميعه خلي بالك منها

1- Ligaments of the uterus (true & false ligaments):

A. TRUE (CERVICAL) MAIN SUPPORT

i. Mackenrodt lig = cardinal = transverse= great cervical lig

- Fan shaped
- From lateral side of supravaginal cervix & vaginal vault to lateral pelvic wall (**white line**).
- Ureter passes in a canal in it
- It forms the base of the broad ligament

ii. Utero-sacral ligaments:

- 2 bands from back of cx to 3rd sacral piece surrounding the rectum.

iii- Pubo-cervical ligaments = pubo cervicovesical fascia

- from the anterior aspect of the supravaginal cervix to the back of the Symphysis pubis

B. FALSE (CORPOREAL) MINIMAL SUPPORT

I. Round ligament:

- It keeps the anteversion anteflexion
- It is attached to the cornu
- Then passes in the inguinal canal
- To insert in the labium majus
- It is supplied by
  - **Sampson artery (from ovarian artery)**
  - inferior epigastric artery.

II. Ovarian ligament:

- Fibro-muscular bands between the ovaries & uterine cornua

III. Broad ligament:

- **2 folds of peritoneum**
- From the side of the uterus to the lateral pelvic wall.
- The **infundibulopelvic ligament** is the part between infundibulum of the fallopian tube & pelvic wall.
- **Contents:**
  - Fallopian tubes
  - Round & ovarian ligaments
  - Blood vessels (Uterine & ovarian vessels), Nerves & lymphatics
  - Parametrium
  - Remnants of Wolffian system (paroophoron & epoophoron).

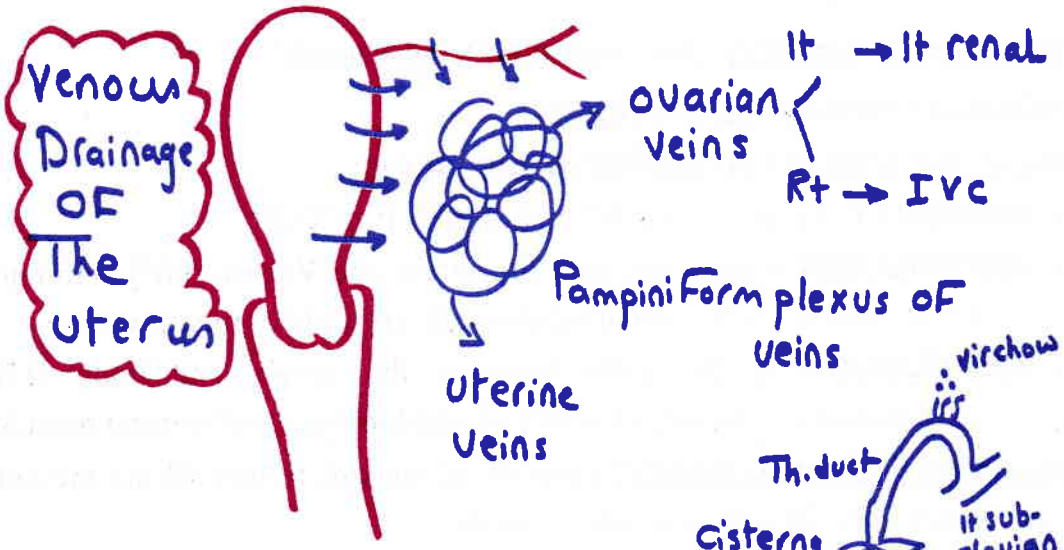
Venous Drainage OF The uterus
ovarian veins
lt → lt renal
Rt → IVC
Pampiniform plexus of veins
uterine veins

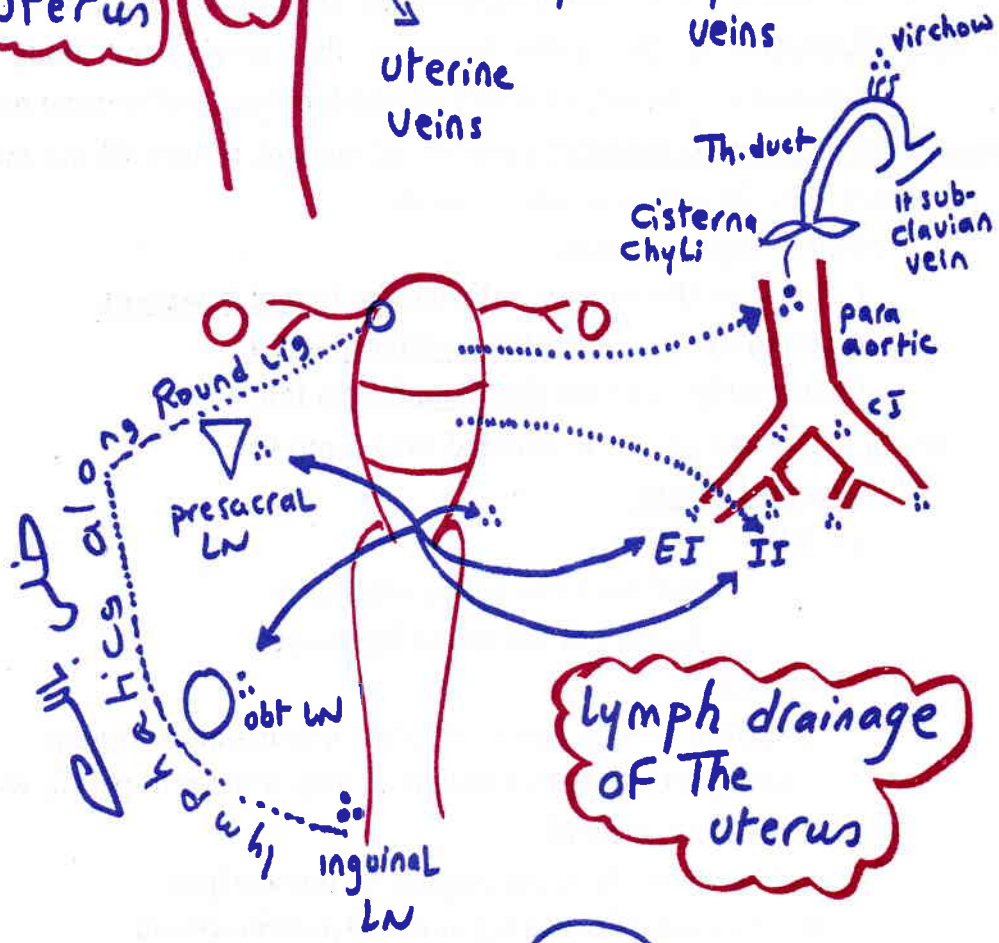
virchow
Th. duct
Cisterna chyli
lt sub-clavian vein
para aortic
CI
Round lig.
presacral LN
EI
II
obt LN
inguinal LN
lymph drainage OF The uterus


Nerve supply of Corpus, cx & upper 2/3 of vagina
parasymp.
S2,3,4
symp
T5 - L1

2- The peritoneal reflection (utero-vesical & Douglas pouch)

3- Position of surrounding structures.

4- Anteverted ante flexed position of the uterus:

- ★ **NORMALLY** the uterus is AVF but in 20% it is RVF.
- ★ **ANTEVERSION** = angle between the cervix and Vagina (90°) maintained by the utero-sacral, round ligament & intra-abdominal pressure.
- ★ **ANTEFLEXION** is the angle between the cervix and body (170°) maintained by the same factors of version + tone of uterine muscles.

5- Pelvic floor (indirect support®) consists of the soft tissues filling the outlet of the bony pelvis اهم سؤال:

A) PELVIC PERITONEUM:

- **Lateral to the uterus**: it forms the **broad ligament**.
- **Anteriorly**: it forms **utero-vesical pouch**
- **Posteriorly**: it forms **the Douglas pouch.**

B) PELVIC FASCIA: it is divided into 2 parts

Visceral fascia:

- It fills:
  - Between the pelvic organs +
  - Layers of the broad ligament.
- Function:
  - Loose areolar tissue → allow expansion of organs
  - Support the pelvix organs & attach them to pelvic wall
- It condenses around:
  - The cervix & upper vagina → **paracolpos**.
  - The base of broad ligament → **parametrium**.
  - Between the vagina & rectum → **rectovaginal fascia**
  - The cervical ligaments are condensations of this fascia i.e. the cardinal, Pubo-cervical & utero-sacral ligaments.

Parietal fascia:

- Covers the muscles of pelvis
- It's extra-peritoneal
- It is continuous with
  - The fascia of the thigh through the obturator foramen,
  - The fascia of the buttocks through sacro-sciatic foramen
  - The peri-renal fascia.

True ligaments:-

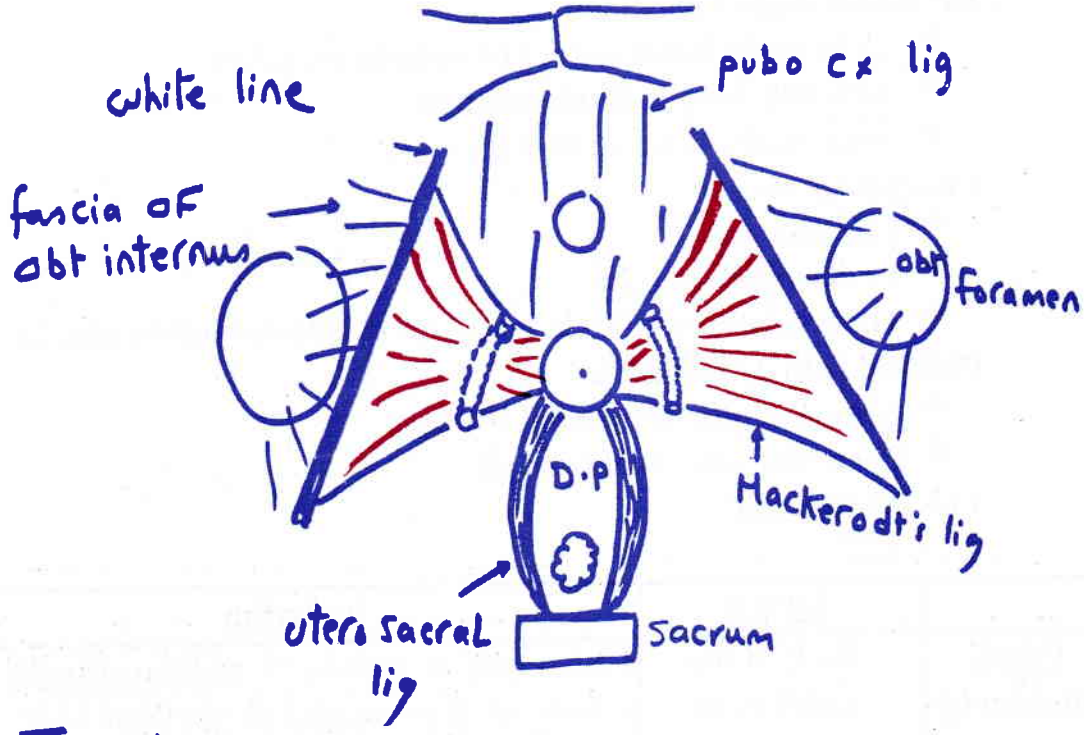

False ligaments

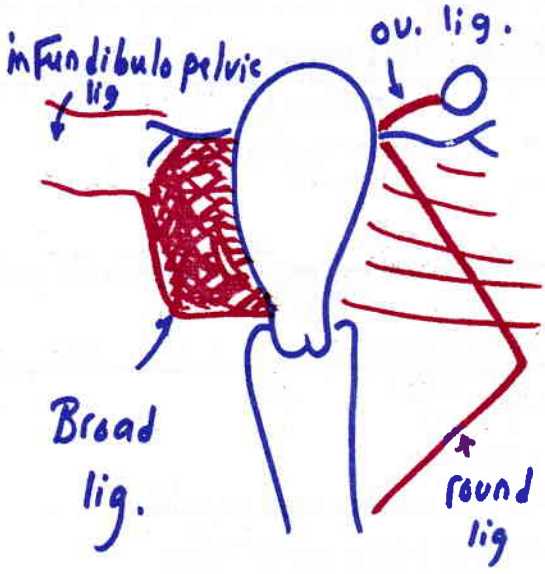

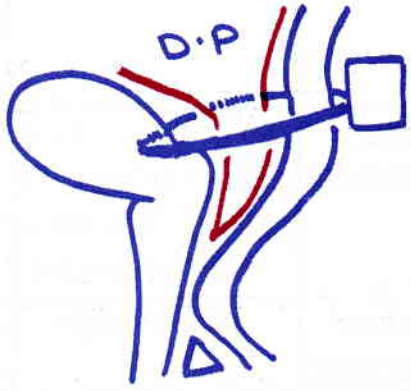

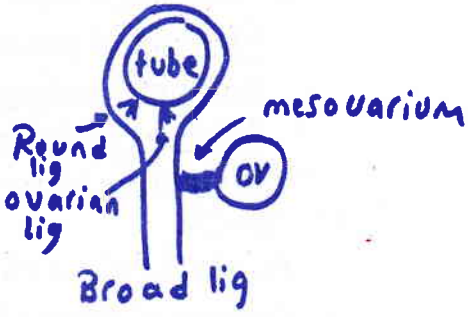

○ THE PELVIC DIAPHRAGM:

- Fibromuscular funnel shaped sheet
- **Diamond** shaped extends:
  - anterior to lower border of symphysis pubis
  - laterally to ischial tuberosities
  - posteriorly to tip of coccyx
- **Composed of:**
  - 2 levator ani
  - 2 coccygeal muscles
  - Their supporting fascia (superior & inferior pelvic fascia)
- **Divided into 2 triangles:**
  - **Anterior one**: urogenital triangle
  - **Posterior one**: anal triangle
- **The levator ani:**
  - **Parts:**

	Origin	insertion
Pubo-coccygeus	back of the pubic bone	♦ Side wall or urethra → **pubourethralis** ♦ Side walls of vagina & perineal body → **pubovaginalis** (fibers of Lushka) ♦ Side walls of rectum → **puborectalis** ♦ Tip of coccyx and anococcygeal raphe → **pubococcygeus proper**
ileo-coccygeus	White line (thickening of the obturator internus fascia)	➢ Coccyx ➢ ano-coccygeal raphe
Ischio-coccygeus	ischial spine	coccyx

  - **Functions of the levator ani:**
    1. **Support** of pelvic organs.
    2. **Sphincter action** for the rectum and vagina.
    3. **Internal rotation** during 2nd stage of labor.
    4. **Maintains intra-abdominal pressure**
  - **Nerve supply:**
    1. **Pudendal nerve** ($S_{2, 3, 4}$)→ perineal surface
    2. **Coccygeal** nerve (S 3&4)→ pelvic surface.

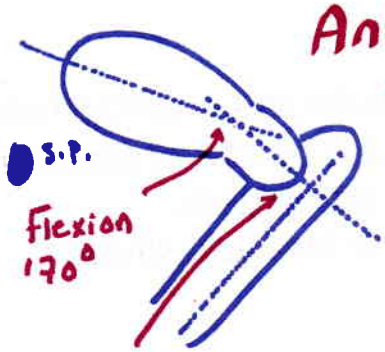

Ante version
≡ Ante Flexion

version
90°

The pelvic Floor

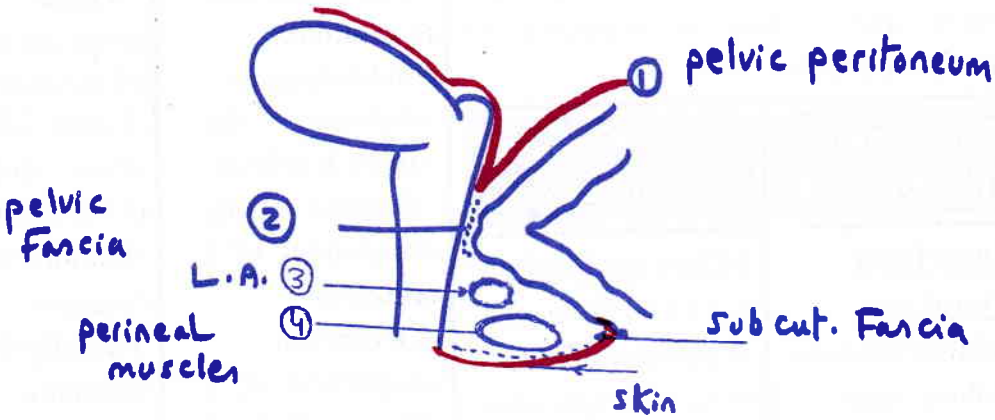

Pelvic Fascia :-
- Parietal
- Visceral

True ligs

perivesical Fascia

Para
- metrium
- colpos (vag)

peri-rectal

sciatic Foramina

obt. Foramina

D) THE PERINEAL MUSCLES:

- **Transverse perineal muscles:**
  - **Deep transverse perineal m**: from pubic arch to perineal body.
  - **Superficial tr. perineal m**: from ischial ramus to perineal body.
- **Bulbocavernosus**: from clitoris to the perineal body.
- **Ischiocavernosus**: from ischial ramus to base of the clitoris.

E) PERINEAL SKIN + COLLE'S FASCIA

N.B. للاوائل فقط

TEE PERINEUM (2-5 CM)		PERINEAL RODY	ISCHORECTAL FOSSA
-Area between skin below & L. ani above -Divided into 2 pouches separated by perineal membrane		**-Fibromuscular pyramidal condensation** -Between the vagina & rectum **-Formed by attachment of 9 muscles:** -2 levator ani -2superficial & 2 deep tr. Perineal ms -2 bulbospongisus ms -External anal sphincter	**-Wedge** shaped space on either side of the anal canal -Filled with **fat** to allow distinsibility of the rectum **-Boundaries:** • Superior & medially→L. ani • Medially → rectum • Lat→ obturator m. & fascia containing the Alcock`s canal • Inferiorly→skin
Superficial Perineal pouch	**Deep Perineal pouch**		
1-Superficial perineal ms: • Ischiocavernosus • Bulbospongisus • Superficial tr.perineal m. **2-Crura of clitoris** **3- vestibular bulb** **4-Bartholin gland**	**1-Deep perineal ms:** •Deep tr. Perineal m. •Sphincter urethrae •Ext. anal sphincter **2-Dorsal nerve of clitoris** **3-Artery of the bulb** **4-Internal pudendal vessels**		

The Fallopian Tube

- **STRUCTURE:** It is about 10 cm (4 inches) long, divided into:
  - **Interstitial portion (1cm x < 1mm):** acts as a sphincter
    - Preventing retrograde menstruation &
    - Delay the fertilized ovum for 3 days for maturation
  - **Isthmus (2 cm x 2mm):** straight, narrow with thick wall.
  - **Ampulla (5cm x 5mm):** tortuous widest part with a thin wall.
  - **Infundibulum (2 cm x trumpet):** it opens into the peritoneum & surrounded by fimbria, the longest is fimbria ovarica

The levator ani:-

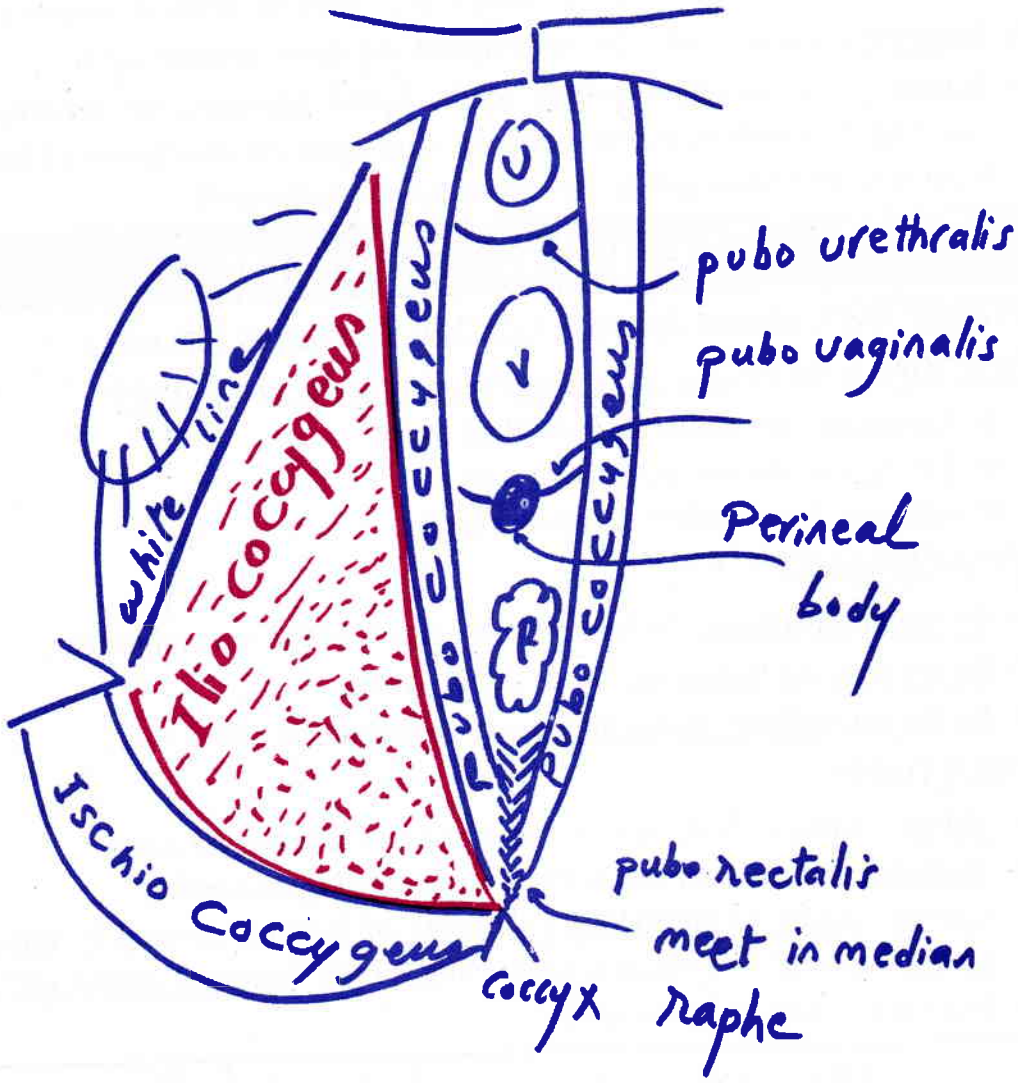

levator ani

- pubo coccygeus
  - pubo urethralis
  - pubo vaginalis
  - pubo rectalis
- Iliococcygus
- Ischio-coccygeus

LAYERS:

- **Mucosa "endosalpinx"**: It forms longitudinal folds "plicae". It is lined by a columnar cells (ciliated & secretory), peg cells (immature or reserve).
- **Muscles:** It consists of outer longitudinal and inner circular layers.
- **Serosa:** it is the upper margin of the broad ligament, the peritoneum covering is complete except a narrow strip opposite attachment of broad ligament, interstitial part & fimbrial end (intraperitoneal).

The gonads = Ovaries

DESCRIPTION: almond shaped 3 x 2 x 1cm & weighing 5gm each.

POSITION: in the fossa ovarica (depression in lateral pelvic wall)

- Anteriorly: the obliterated umblical artery
- Posteriorly: the ureter, internal iliac a.
- Lateraly: the obturator nerves & vessels.

ATTACHMENTS

- **By the mesovarium:** To the posterior surface of the broad ligament.
- **By the ovarian ligament:** To the uterine cornu.
- **By the infundibulo-pelvic ligament:** To the lateral pelvic wall.

STRUCTURE:

- **Hilum:** through which vessels & nerves enter & leave the ovary.
- **Medulla:** It is the connective tissue surrounded by the cortex.
- **Cortex (MAIN COMPONENT):** formed of follicles covered by tunica albuginea, lined by a single layer of cubical cells "germinal epithelium".
- It is not covered by peritoneum

	Blood supply	Lymph drainage	Nerve supply
Ovary	**Ovarian a.** branch of the aorta (L2) **Ovarian vein:** ★ Right: drains in inferior vena cava. ★ Left: drains in the left renal vein.	Para-aortic LN	▪ autonomic (ovarian plexus) formed of o symp: T10,11 o parasymp S2,3,4
Tube	**Arteries:** Ovarian & uterine arteries (double blood supply so gangrene is rare). **Venous drainage:** Into the ovarian vein.	Para-aortic LN	o As the ovary

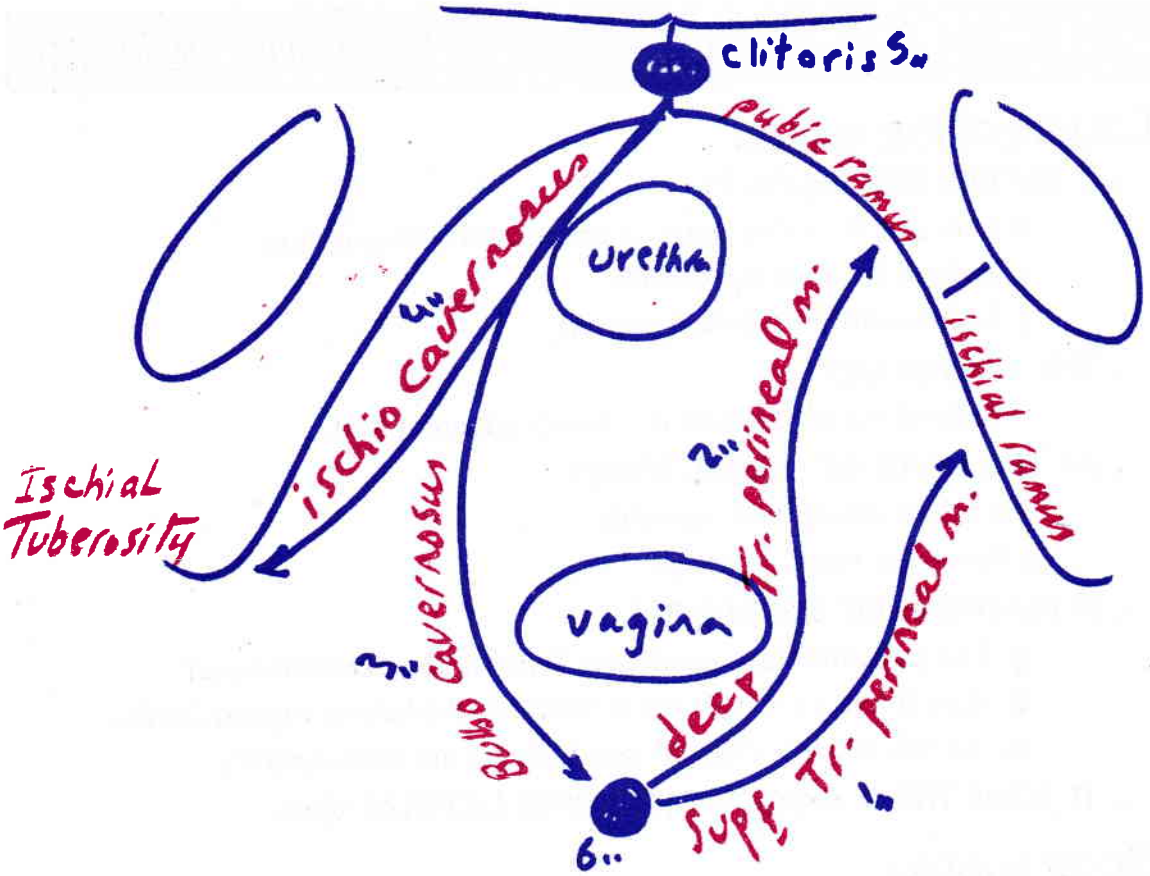
clitoris 5..
pubic ramus
ischio cavernosus 4..
urethra
ischial ramus
Ischial Tuberosity
2.. Tr. perineal m.
vagina
3.. Bulbo cavernosus
deep
6..
Supf. Tr. perineal m. 1..

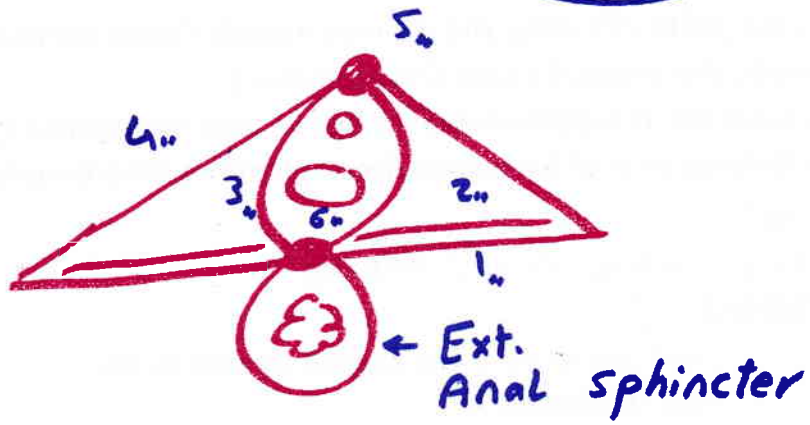
5..
4..
3..
6..
2..
1..
Ext. Anal sphincter

Anatomy of the pelvic Ureter (whole 20cm, pelvic part 10 cm)

Course of the ureter:

- IT ENTERS THE PELVIS BY
  - Crossing the bifurcation of the **common iliac artery**
  - Behind the **ovarian vessels**
  - In **infundibulopelvic ligament**.
- THE URETER LIES
  - ✓ Behind the peritoneum & Closely adherent to it.
- AT THE LEVEL OF ISCHIAL SPINES,
  - It runs medially and forwards
  - Below the broad ligament
- IN MACKENRODT LIGAMENT:
  - The **parametrium** condenses forming the **ureteric canal**
  - Here it lies 1.5 cm above & lateral to the lateral vaginal fornix.
  - At this site it is crossed anteriorly by the uterine artery.
- IT JOINS THE BLADDER AT ITS UPPER LATERAL END.

Blood supply:

- **Branches From**
  - Internal iliac artery
  - Uterine artery
  - Vaginal artery
  - Inferior vesical arteries.

>>>>>>>>>>>>>>>Injuries of the ureter<<<<<<<<<<<<<<<

Site:

- **At the point crossing the uterine vessels** (most common)
- **Beside the vaginal vault** (2nd common)
- **Behind the infundibulopelvic lig:** in total abdominal hysterectomy
- **At bifurcation of Common iliac artery:** at iliac lymph adenectomy

Type:

- **Direct :** cutting, crushing, suturing
- **Indirect :**
  - Devascularization in radical hysterectomy
  - Post irradiation
    - → Hydro-ureter, Hydro-nephrosis & Fistula

Ischio rectal Fossa

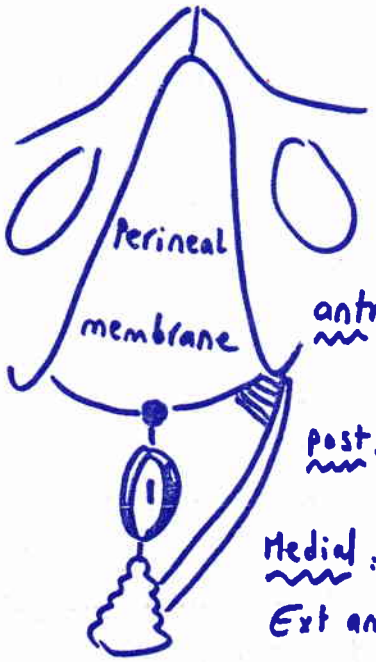

antr:- perineal membrane

post:- Sacro tuberous lig.

Medial:
Ext anal sphincter

P.C. = Pudendal = Alcock's canal

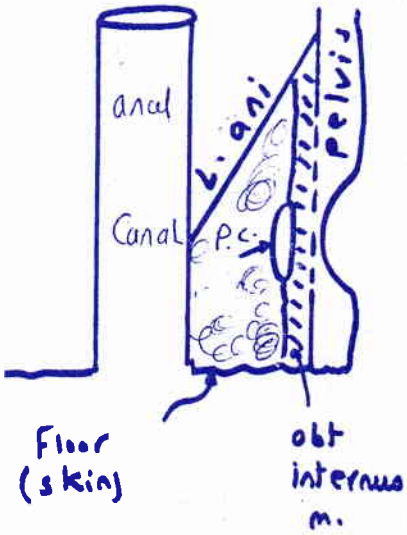

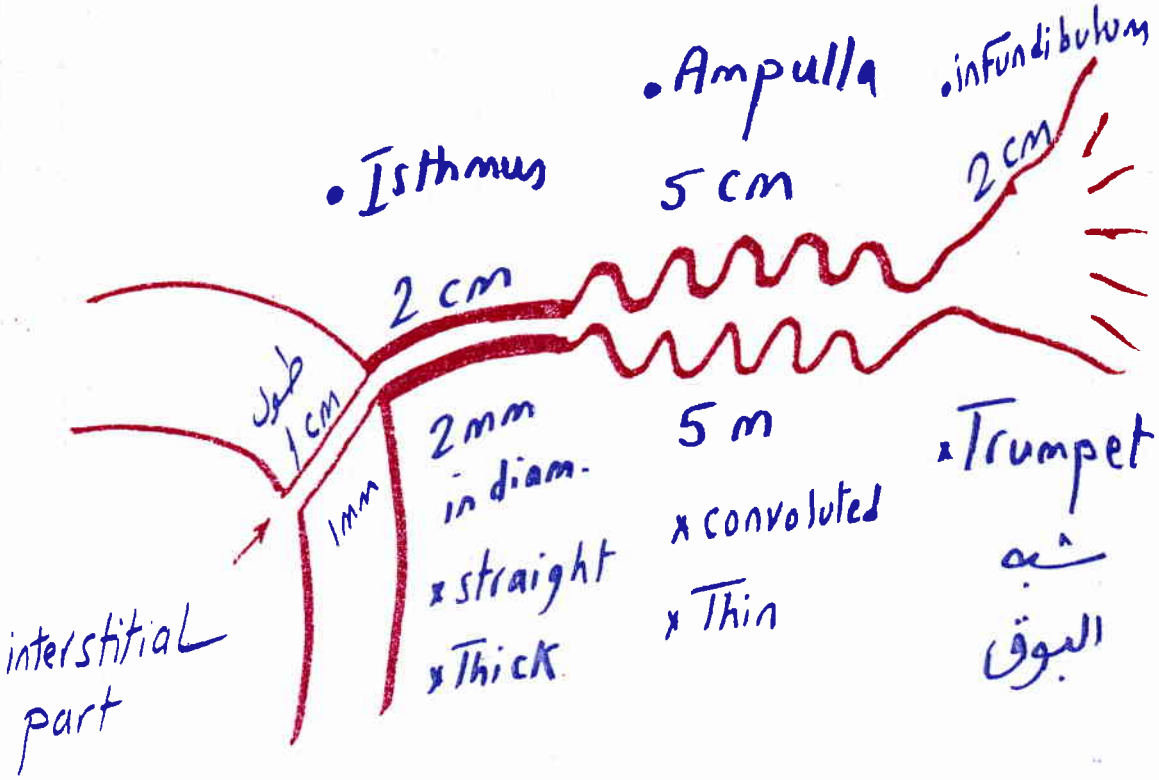

Predisposing factors:

- abnormal course
- abnormal anatomy: cervical fibroid, cancers or extensive adhesions
- Intraoperative uncontrollable hemorrhage

Methods to avoid injury:

- **Preoperative**: IVP.
- **Intraoperative**:
  - Ureteric catheter → if suspected injury
  - Exposure of the whole course
  - Pedicles & clamps should be clamped under vision
  - Mobilization of the bladder
  - Sub capsular removal of fibroids as the ureter is close to the capsule

BRANCHES OF THE INTERNAL ILIAC ARTERY

posterior division	anterior division		
1. Ilio lumbar 2. Two lateral sacral art. 3. Ends by becoming the superior gluteal artery	*1. Visceral branches (4)* • **Superior vesical.** • **Middle vesical.** • **Middle rectal** (hemorroidal) • **Uterine artery** which gives ✓ Tubal & ovarian branches. ✓ Vaginal artery. ✓ Cervical artery which gives: a. Anterior vaginal b. Coronary artery of the cervix which gives anterior & posterior azygous	*2. Parietal branches (4)* • Obturator artery. • Obliterated hypogastric artery (umbilical artery). • 2 terminal branches: -Inferior gluteal artery -Internal pudendal artery which gives : ✓ Clitoridal artery. ✓ Perineal branches. ✓ Inferior rectal (inferior hemorroidal artery).	*3. Ureteral branches*

- **The superior rectal artery** is the continuation of inferior mesenteric a.
- **The middle rectal artery** is a branch of the internal iliac artery
- **Inferior rectal artery** is a branch of the internal pudendal artery
- **Median sacral artery** is a small artery from the posterior surface of aorta.

Course of ureter

bifurcation ورا
ov. a. قدام
① إسالندوتش

Ischial spine
ureteric canal
uterine artery

IIA Branches

ilio lumbar
فوق
supr. glut.
ورا
lat sacral
تحت
I nfr gl.
Middle rectal
I nt. pudendal
. Supr
Middle rectal
. uterine art
. vaginal art
O bt. unb art
O bt. art

Branches From

1. renal art
2. ov art
3. I I A
4. ut. art.
5. Vag. art.
6. Vesical art.

Blood supply of ureter

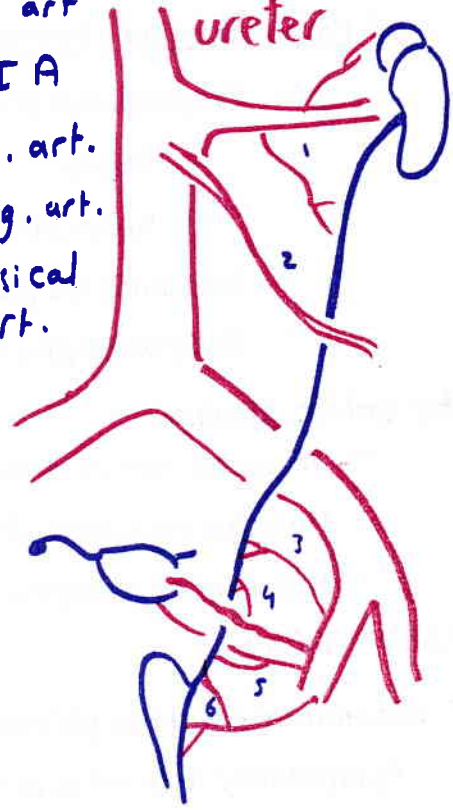

Nerve supply

- **VULVA, PERINEUM + LOWER 1/4 VAGINA**
  - **All somatic**
- **UTERUS, CERVIX, UPPER ¾ VAGINA:**
  - **autonomic nervous system**

    1-Sympathetic (T7 to L2)

    - **Motor** (T 7,8)
    - **Sensory** (T10-L2)
    - **Sympathetic fibers** (postganglionic)
      - Pass in the superior hypogastric plexus over the promontory of sacrum
      - Divides into right & Left presacral nerves on both sides of rectum.

    2-Parasympathetic (sensory + motor) S 2, 3, 4

    - Preganglionic fibers
      - Pelvic
      - Splanchinic nerves
    - Pass along the pudendal nerves
    - Relay at ganglia or near wall of viscera

- **The pelvic plexus:**
  - Presacral nerves + pelvic nerves join to form pelvic plexus (inferior epigastric plexus),
  - It lies in the endopelvic fascia supplying the whole viscera
- **OVARY + TUBES**
  - **autonomic (ovarian plexus) formed of**
    - **Sympathetic** from celiac & renal ganglia (with ovarian vessels T10,11)
    - **Parasympathetic** from S2,3,4

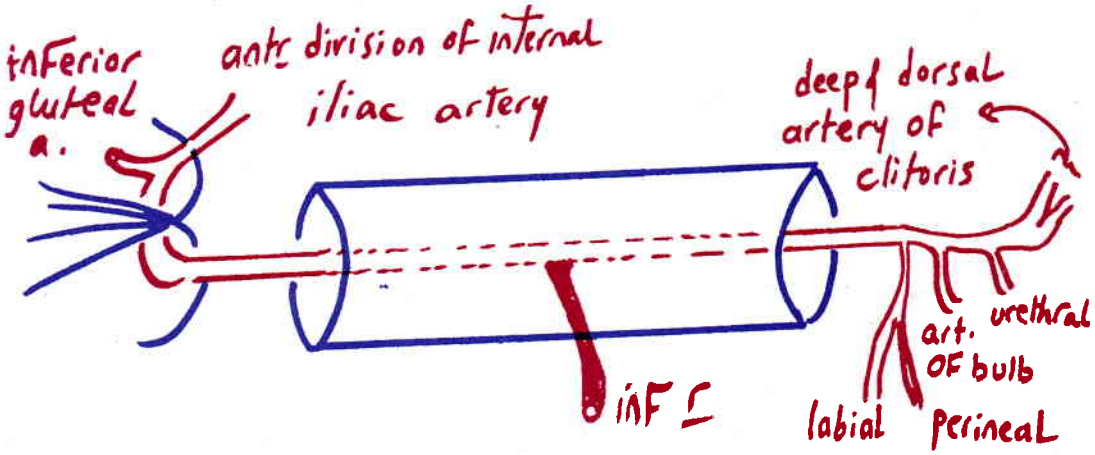

The internal pudendal artery

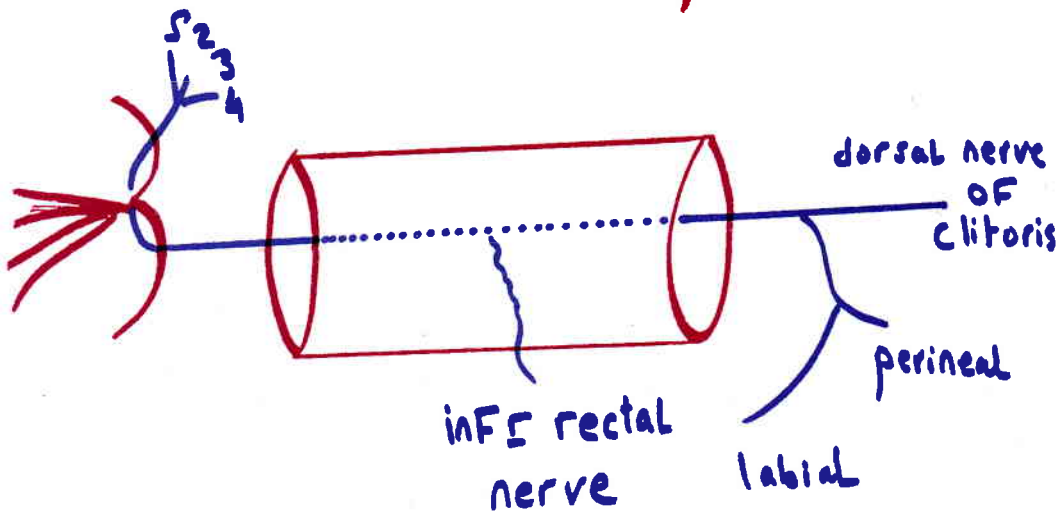

The pudendal nerve

EMBRYOLOGY

®EMBRYOLOGY☺

DEVELOPMENT OF GONADS

⊙INTRAUTERINE:

◈ **3rd weeks:**

- Germ cells appear in the hind gut
- Then migrate by ameboid movement through the dorsal mesentery to the genital ridge.

◈ **5th – 6th weeks:**

- Ovaries appear in the **genital ridge** (medial thickened part of the urogenital ridge) opposite the **upper lumbar vertebrae** ®
- Then descends ☺ into the pelvis due to:
  - ❖ **Uunequal growth** (trunk > rest of the body)
  - ❖ Not hormone dependent (unlike the testis).

◈ **The ovary is formed of the 3 germ layers:**

- **Mesenchyme**
  - Form **sex stroma** → **theca cells**
- **Cœlomic epithelium (ectodermal)**
  - Form **sex cords** (down growth of the surface epithelium into the substance of the ovary) → **granulosa cells**
- **Germ cells (endodermal in origin)**

◈ **At 20 weeks:**

- Number is 6-7 million by mitosis.
- Then stop mitosis → (1ry oocytes) & start meiosis to stop in the prophase of 1st meiotic (M1).
- Granulosa & theca cells envelop the germ cells → primordial follicles.

⊙AT DELIVERY:

- Number of oogonia at delivery is 1-2 million (↓ number is by **shedding**)

⊙AT PUBERTY:

- The no. at puberty is 300,000-400,000 (reduction of number is by **atresia**).
- Every month 1000 follicles regrow & only 1 becomes **Graffian follicle**.

⊙JUST PREOVULATORY:

- 1ry oocyte finishes M1→ (2ry oocyte) & start 2nd meiotic to finish it just after fertilization → mature ovum & 2nd polar body.

* Then migrate by _____ movement to settle in The G R by weeks of Intrauterine life

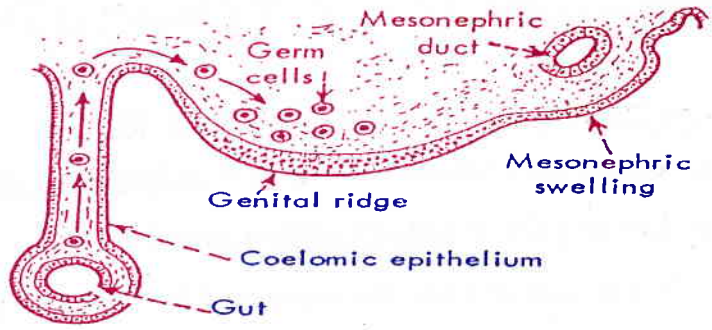

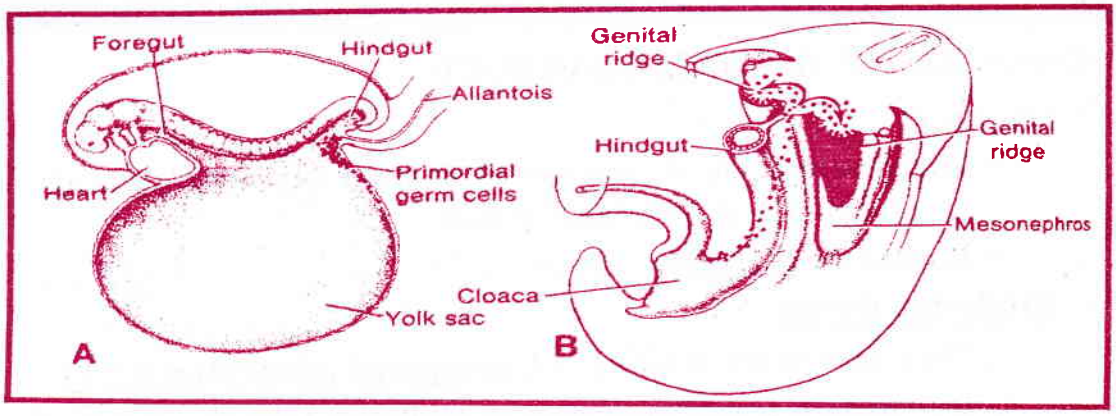

Formation of GR & UGR & migration of Germ cells

The 3 germ Layers

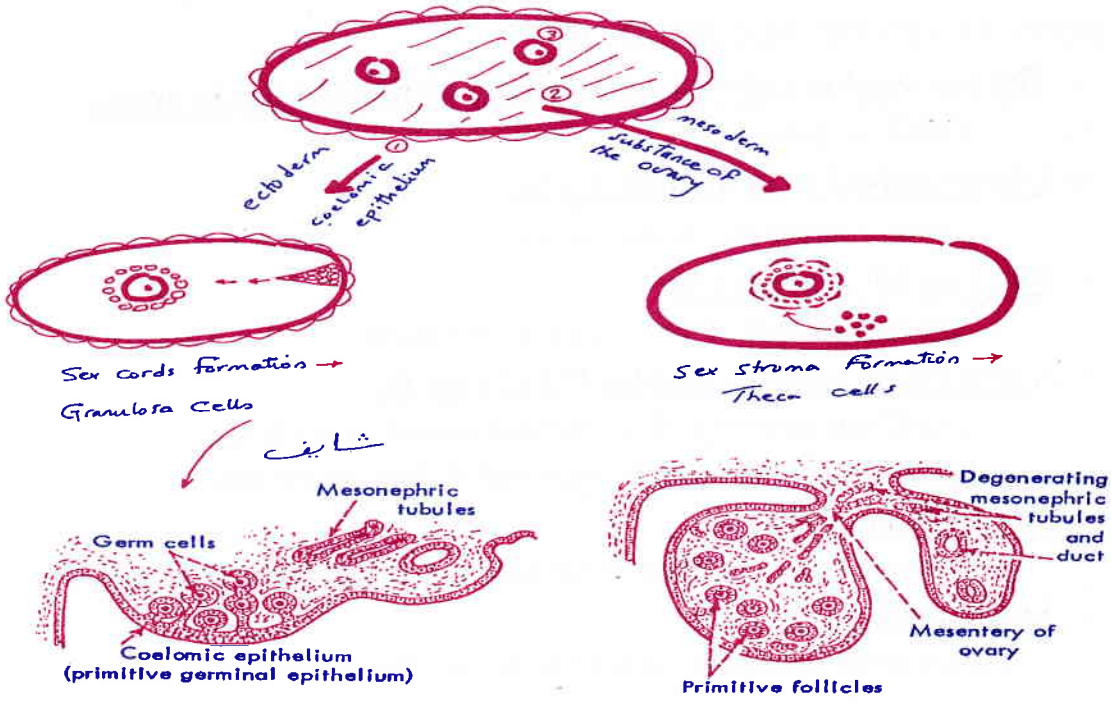

⊙ DERIVATIVES OF THE GENITAL RIDGE:

- **Upper part** (above the ovary) → **infundibulo-pelvic ligament**.
- **Lower part** → **gubernaculum ovarii**☺
  - The part between the **ovary** and the **cornu** → **ovarian ligaments**.
  - The part between the **cornu** and the **labia majora** → **round ligaments**.

DEVELOPMENT OF INTERNAL GENITALIA

⊙FORMATION OF THE MÜLLERIAN DUCT:

- **5th week:**
  - Invagination of the cœlomic epithelium in the mesoderm lateral to ✌ genital ridge & Wolffian ♂ system
  - & forms the **Müllerian** ♀ **ducts**.
- **Müllerian ducts:**
  - They fuse in the midline → **Uterovaginal primordium (UVP)**
  - UVP projects in urogenital sinus by **Müllerian tubercle** (eminence)
- **This contact:**
  - Induces UGS to from the vaginal plate (endodermal origin)
- **at 20 weeks:**
  - canalization of the vaginal plate occurs

⊙DERIVATIVES OF MÜLLERIAN DUCT

- **The horizontal unfused parts of the Müllerian ducts gives:**
  - Fallopian Tubes.
- **Utero-vaginal primordium gives:**
  - Uterus + upper part of the vagina.
- **The vaginal plate gives:**
  - Sinovaginal bulb → lower part of the vagina.
- **A uro-rectal septum divides the cloaca to:**
  - **Two Compartments** → Urogenital sinus & anal canal
  - **Closed by 2 membranes** Urogenital & anal membranes
- **The UGS gives**💣
  - Urinary bladder, Urethra & the genital part will form the vestibules.
- **The hymen:**
  - arise at the junction between Mullerian tubercle & vaginal plate

THE FORMATION OF THE UTERUS AND VAGINA

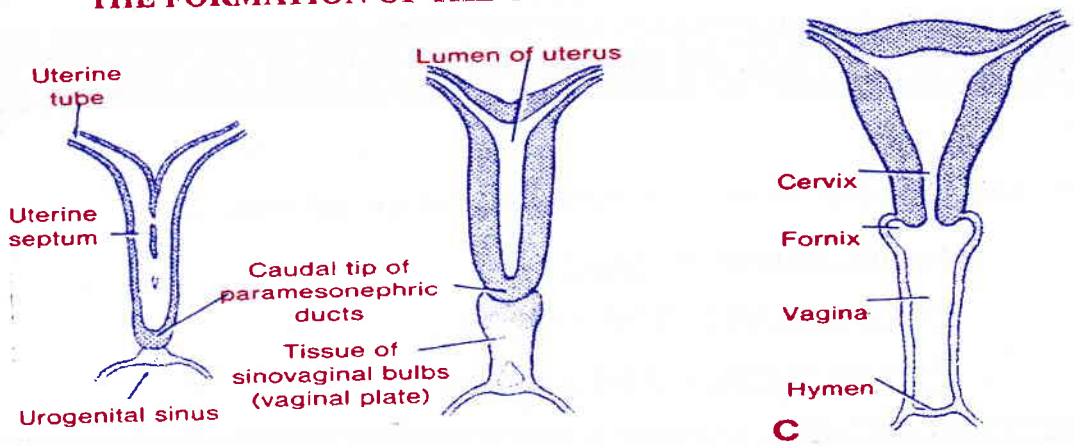

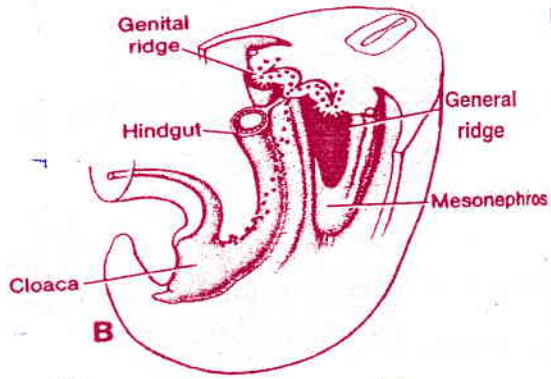

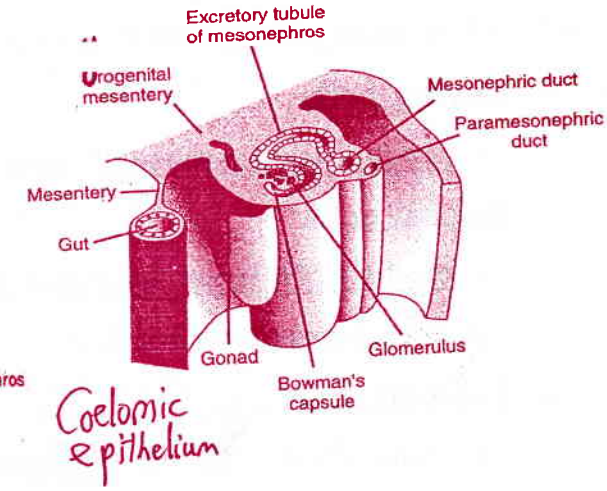

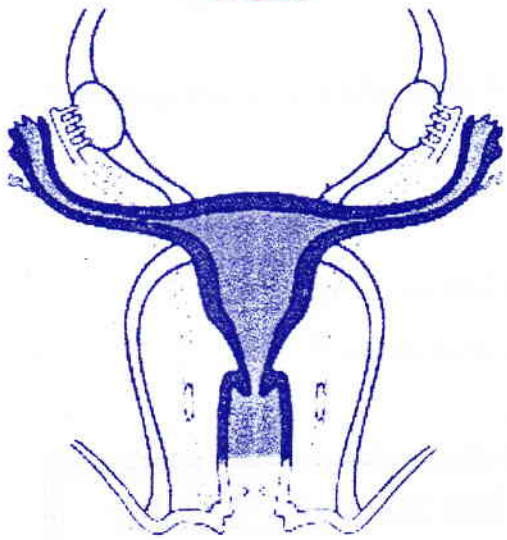

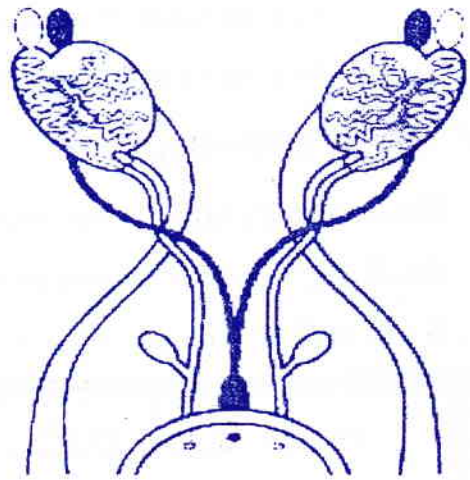

derivatives of the genital ridge

DEVELOPMENT OF THE EXTERNAL GENITALIA

b) At 4th week:

- swellings appear on the surface around the urogenital sinus:
  - **Genital tubercle → clitoris**
  - **Urogenital folds → labia minora.**
  - **Genital swellings → labia majora.**

SEXUAL DIFFERENTIATION & DEVELOPMENT

c) IN XY → under effect of SRY (sex determining region of Y chromosome) :

- **Leydig cells**
  - **produce testosterone (50th day)** → stimulates Wolffian
- **Sertoli cells**
  - **produce Müllerian inhibition factor** → degeneration of Müllerian duct (paramesonephric duct)
- **Testosterone**
  - Transformed to **Dihydrotestosterone** in external genitalia cells **by 5 α-reductase** which stimulates the growth of:
    - The **phallus** into **penis**,
    - **Genital folds** → ventral aspect of **penis** (floor of penile urethra)
    - **Genital swelling** → **Scrotum.**

d) IF NO Y CHROMOSOME:

- **No testosterone** → degeneration of Wolffian duct.
- **No M.I.F** → growth & development of Müllerian duct.
- **No D.H.T** → feminine external genitalia.

feminity is a neutral state but masculinity is the superimposed character

Development of The External genitalia

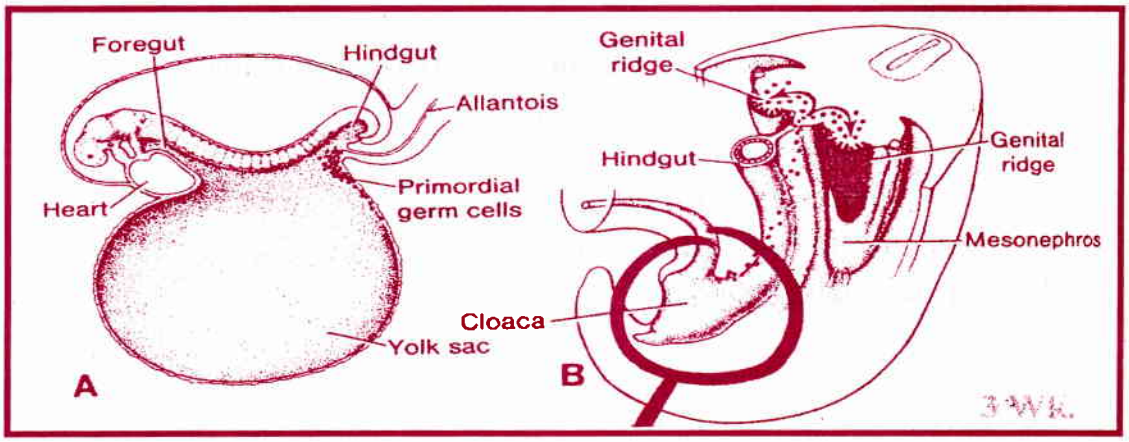

sexual differentiation & development

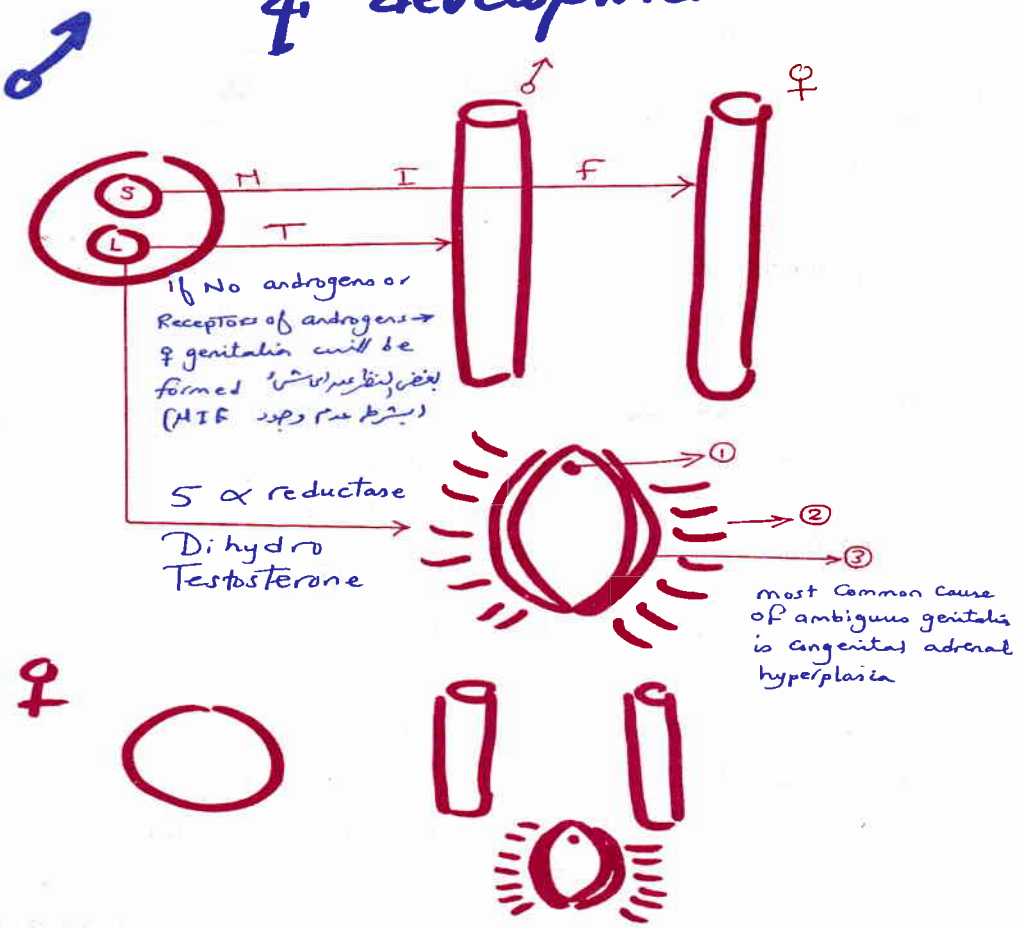

DEVELOPMENT OF THE KIDNEY بتمر بثلاث مراحل

PRONEPHROS (1ST KIDNEY)

- **Tubules:**
  - Appear at the **thoracic region** of the **urogenital ridge**
  - Open into the **pronephric duct**
  - Then atrophy leaving
    - **Hydatid of Morgagni** (near tubal fimbria) &
    - **Koblet's tubules** (at outer part of broad ligament).
- **Pronephric duct**: persists.

MESONEPHROS (2ND KIDNEY)

- **Tubules**
  - Appear at the abdominal region of the urogenital ridge
  - Open into the mesonephric (Wollfian) duct
  - Then atrophy leaving
    - **Epoophoron** (between the ovary & the tube),
    - **Paroophoron** (between the ovary & the uterus)
- **Mesonephric duct gives:**
  - **ureteric bud** which forms:
    - Ureters
    - Renal pelvis
    - Calyces
  - **In** ♂ they produce the ♂ **duct system**
  - **In** ♀ gives the ureter only & atrophy→**Gartner's duct** which runs
    - **Medially** below the fallopian tube
    - **Lateral** to the uterus, cervix & vagina
    - **Ends** at the clitoris (may form a cyst)

METANEPHROS (DEFINITIVE KIDNEY☺ سؤال مهم)

- **The ureteric bud:**
  - Will join the metanephros → Permanent kidney
- **Mesonephric duct**
  - Below the ureteric bud forms the **trigone** of the bladder.
  - The rest of the **bladder & urethra** arise from the urogenital sinus.
  - Buds from the urogenital sinus arise in the urethra → **Skene glands**

Development of the urinary system

The nephrogenic unit consists of:
- Excretory tubules: Bowman's capsule, convoluted tubules and loop of Henle.
- Glomerulus
- Collecting system

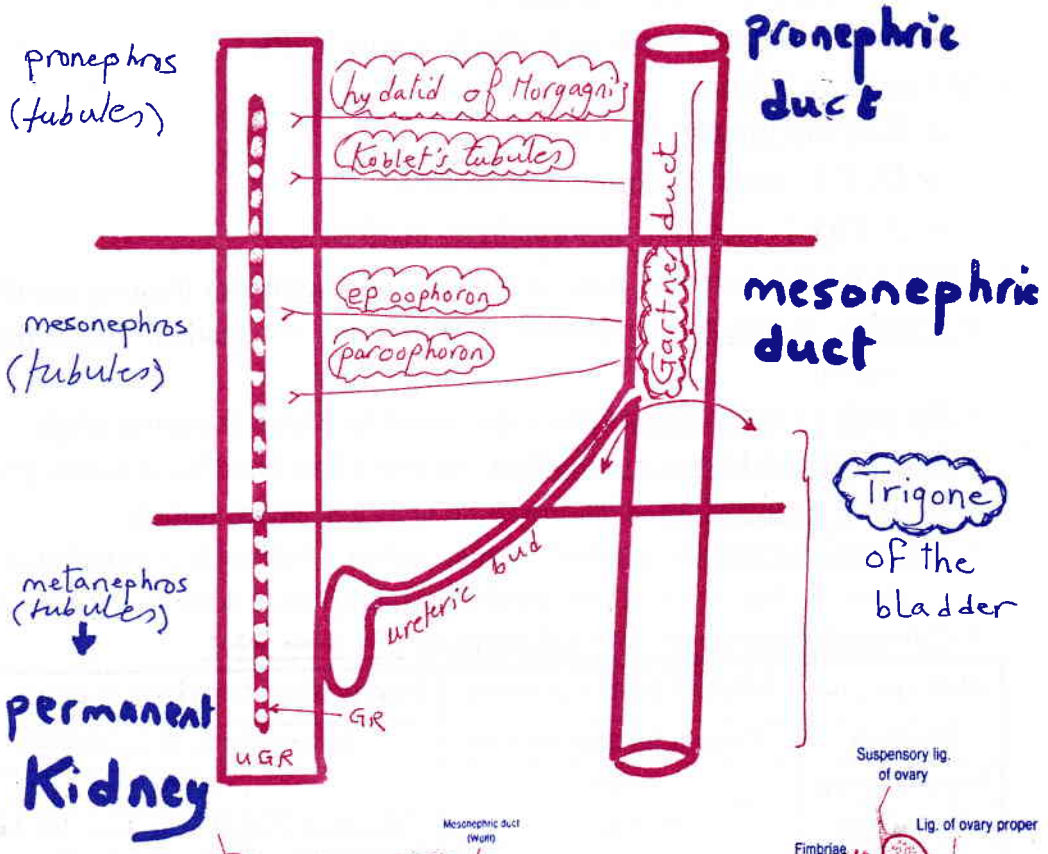

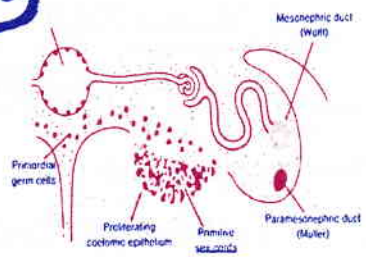

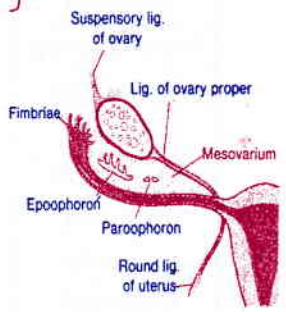

VAGINAL MALFORMATIONS اهم واحدة حفظ

APLASIA (RARE)

- **Types:**
  - **Complete** Müllerian agenesis = (absent uterus + vagina)
    = **Mayer-Rokitansky-Küster-Hauser syndrome**
  - **Partial** (the uterus may be present).
- **Symptoms:**
  - 1ry amenorrhea
  - Apareunia
- **Signs:**
  - Normal 2ry sexual characters
  - Small vaginal pouch with absent uterus by PR
- **Investigations:**
  - **Karvotyping:** 46 XX
  - **IVP :** Renal abnormalities in 50%
  - **X ray :** vertebral abnormalities in 15%.
- **Treatment:** (aims to make a functioning vagina not treating sterility).
  - **Frank's method:** dilatation & moulding → gradual deepening of vagina.
  - **Mc-Indoe's operation:** open a gap lined by a skin from the thigh.
  - **Modified Mc-Indoe's operation:** as above but lined by Amnion graft.
  - **William's operation:** creation of an artificial labial pouch.
  - **Vachetti operation:** gradual traction using a ball with a transfixing tape done by laparotomy (the modified operation is done by laparoscopy)
  - **Colovaginoplasty or iliovaginoplasty** احدث عمليه الان.

جدول مهم للحفظ	Mullerian agenesis	Testicular feminization$
Etiology	Congenial abnormality	Insensitivity to androgens
Karyotyping	46xx	46xy
Phenotype	Normal ♀	Normal ♀ (tall + no hair مهمه جدا)
Gonad	Ovary	Testis in inguinal canal
Hormones	Normal estrogen level	Normal ♂ androgen
Internal genitalia	Small vaginal pouch (نقره)	
External genitalia	Normal vulva	Complete type: normal vulva Incomplete type: ambiguous genitalia

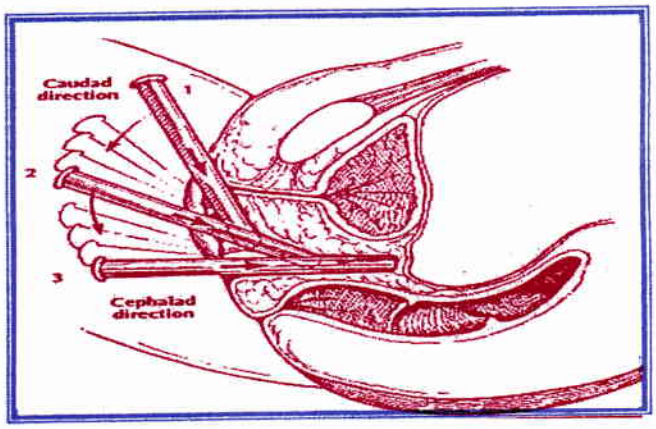

Frank's Method

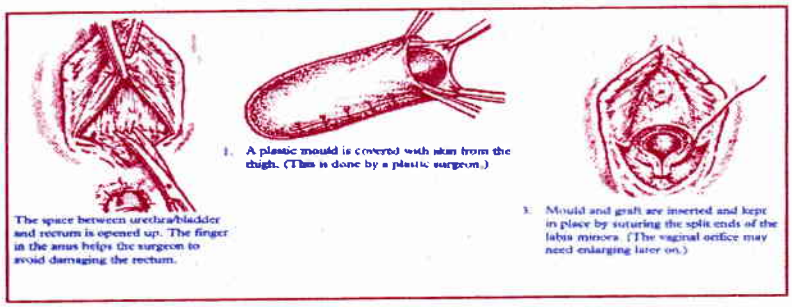

Mcindoe

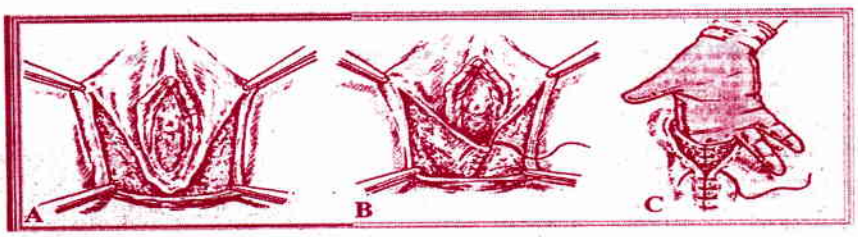

William op

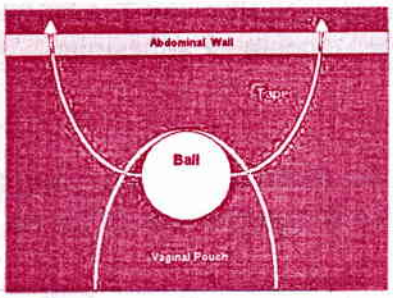

Vachetti op

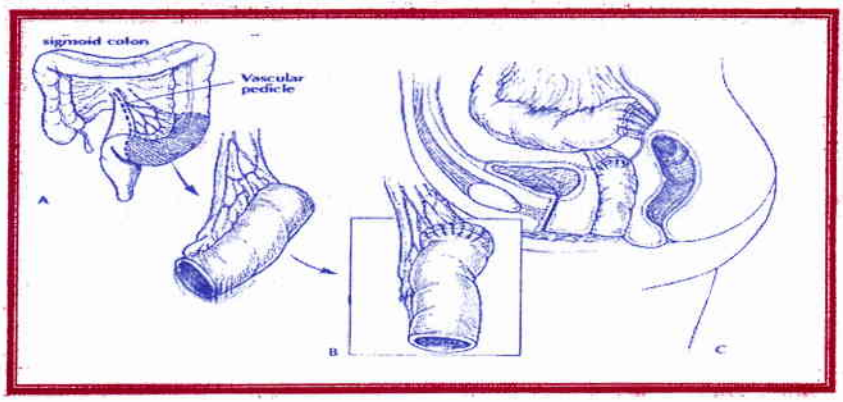

Colovaginoplasty Op

⊙ HYPOPLASIA

- Small vagina.
- Treatment → repeated dilatation.

⊙ DUPLICATION

- **Longitudinal septum ± duplication of the uterus:**
  - **Complaint**:
    - asymptomatic,
    - Dyspareunia
    - Obstructed labor if breech delivery (overrides the septum)
  - **Treatment**: Surgical excision ± skin graft to avoid readhesions
- **Transverse septum:**
  - **Upper**: common between upper & middle 1/3
  - **Lower**: junction of Mullerian duct & UGS(upper 4/5 & lower 1/5)
  - **D.D** → imperforate hymen.
  - **Treatment** →surgical excision ± skin graft to avoid readhesions

Imperforate hymen

◈ PATHOGENESIS + PATHOLOGY:

- After puberty the blood is retained in the vagina "hematocolpos" then fills the uterus "hematometra" & the tubes "hematosalpinx".
- And it becomes dark & chocolate-like due to absorption of some fluid. The blood passes to the peritoneum → adhesions.

◈ SYMPTOMS:

- Delayed menarche.
- Cyclic lower abdominal pain recurring monthly (molimina).
- Dysuria or retention (stretch & compression of the urethra).
- Abdominal enlargement.

◈ SIGNS:

- General examination: Well-developed breast.
- Abdominal ex: reveals a pelvi-abdominal mass i.e. hematocolpos.
- PV reveals a bulging bluish imperforate hymen.
- P.R. reveals a cystic swelling anterior to the rectum

◈ TREATMENT: (Paternal Counseling & documented certificate)

- Under general anesthesia & aseptic precautions >> Hymenotomy (more accepted) or hymenectomy. Donot press on the abdomen or introduce any instrument inside the vagina to avoid infection.
- Antibiotics

UTERINE MALFORMATIONS مهم جدا جدا

APLASIA (MRKH SYNDROME): تشرح بالتفصيل

- Extremely **rare** leads to **1ry amenorrhea & infertility**.

HYPOPLASIA: KNOWN BY UTERINE INDEX→

- corporeal length/cervical length
  - Solid rudimentary uterus: **Solid nodule on the vagina.**
    - Corporal: cervical length 1: 2 - 5.
  - Infantile uterus: **Arrest of development at birth**
    - Corporal : cervical length is 1:2
  - Pubescent uterus: **Arrest of development at Puberty**
    - Corporal: cervical length is 1:1.

- **Symptoms**
  - **Menstrual symptoms**: Hypo-menorrhea, Dysmenorrhea
  - **Infertility**
  - **Habitual abortion** in ascending manner.
- **Signs**
  - **Sound** for Uterine index, the corpus is small (<2.5 inches)
- **Investigations**
  - US, HSG, Hysteroscopy & laparoscopy.
- **Treatment**
  - If pregnant → vaginal cerclage
  - If not pregnant →cyclic E+P

SYMMETRICAL DUPLICATION:

- **Cause:**
  - Lack of fusion of Müllerian ducts.
- **Types**

1. **Uterus didelphys:** 2 bodies, 2 Cx, 2 vaginas, 2 Cx (at least 2 cm apart)
2. **Uterus bicornis bicollis:** 2 bodies, 2 Cx attached together & 1 vagina
3. **Uterus bicornis unicollis**: as above but 1 Cx
4. **Arcuate uterus = uterus cordiformis:** a depression at the fundus
5. **Septate & sub-septate**

HYSTEROSALPINGOGRAPHY

UNICORNUATE UTERUS



A

B

Uterus Bicornis unicollis

C

D



E

Arcuate uterus (corditiformis)

F

- The most common types are:
  - Subseptate
  - Bicornuate unicollis

C/O

- May be **asymptomatic**
- **Menstrual symptoms**: Menorrhagia, dysmenorrhea,
- **Infertility**
- **Recurrent abortions** due to
  - Abnormal muscular arrangement
  - Patulous os
  - Poor vascularity of the septum if implantation occurs on it
- **Malpresentations** (transverse lie or breech) → obstruction
- **Morbid adherence** of the placenta.

Signs:

- Uterus may be markedly tilted to one side

Differentiated by:

- External configuration by depression between 2 uteri,
- **3D U/S**,
- **Laparoscopy**
- But **not noticed on HSG or hysteroscopy**

Treatment:

- **Septate:** combined hysteroscopy + laparoscopy for resection of Septum
- **Bicornuate:** Strassman's metroplasty.
- **Delivery after correction is by C.S.**

COMBINED ANOMALIES

Rudimentary horn:

- **Definition**:
  - **Failure of fusion + hypoplasia of one side**
- **Symptoms:**
  - **Asymptomatic but:**
    - If lined by functioning endometrium + non communicating → hæmatometra.
    - If lined by functioning endometrium + communicating → Ectopic pregnancy.
- **Treatment: Excision**.

"STRASSMAN'S TECHNIQUE

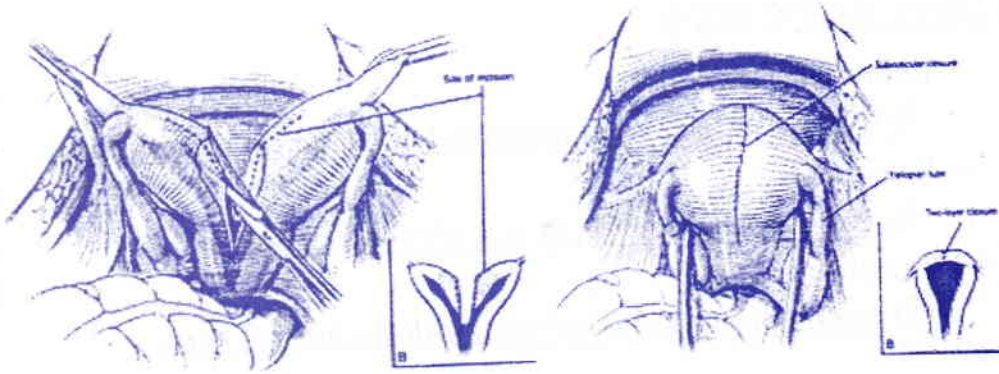

Hysteroscopy

HSG

Septate Uterus

Wedge of fibrous tissue dividing uterine cavity.



Bicornuate Uterus

Incomplete uniting of uterus.

By HSG or Hysteroscopy it's difficult to differentiate

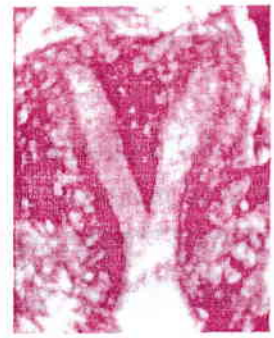

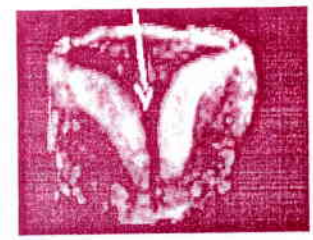

COMPLETE UTERINE SEPTUM

3-D ULTRASOUND SCAN

SUBSEPTATE UTERUS

HYSTEROSALPINGOGRAPHY

3 D-ULTRASOUND SCAN

❖ Blind uterine horn:

- **Definition:**
  - **Failure of fusion + symmetrical development of both horns.**
- **Symptoms:**
  - **cyclic dysmenorrhea, ↑ risk of endometriosis.**
- **Treatment:**
  - **anastomosing the blind horn with the normal horn.**

VULVAL MALFORMATIONS مش مهمه

⊙ HYPERTROPHY OF LABIA MINORA OR CLITORIS

- **Treatment:**
  - Labial reduction (**Circumcision**) if causing
    - Dyspareunia
    - Nymphomania
    - Bad cosmetically.

⊙ FUSION OF LABIA

- **Causes**:
  - **Congenital**
  - **Acquired** (more common) due to:
    - Inflammation postnatal
    - Postmenopausal☺®.
- **Treatment:**
  - Separation of labia
  - Treatment of infection
  - Application of ointment ± local E.

⊙ OTHERS

- Ambiguous genital (intersex), bifid clitoris (with ectopia vesica), vestibular anus, aplasia of the vulva (in dead monsters) & double vulva

FALLOPIAN TUBE MALFORMATIONS طفش

1- **Aplasia**: leads to infertility (± uterine aplasia)
2- **Hypoplasia** (طويله ورفيعه long, tortuous & narrow)
3- **Accessory ostium, diverticulum** → infertility & ectopic pregnancy

- Combined anomaly

Rudimentary horn

(Rudimentary ut. ليه)

* failure of fusion في الاثنين

+

hypoplasia

مسمه بيتحس ويكتشف

* بالصدفه في منظار

* either

non Communicating (الاغلب)
↓
if lined with Functioning end
↓
hematometra
(→ enlarging mass)

Communicating
↓
Ect. preg

Tt:. Excision

Blind uterine horn

+

normal development of both horns

بس المشكله انه واحد منهم مسدود واصل للـ vagina ⇐ blind
= non Communicating

Symptoms: mass + الام

- Dysmenorrhea
- Enlarging mass (hematometra)

D.D. pelvic mass e.g. Complicated fibroid

Tt:. unification

CERVICAL MALFORMATIONS مقفول - واسع - طويل

	Atresia	Congenital elongation	Patulous internal os
CP	Cryptomenorrhea & molimina	Dyspareunia	Habitual abortion
Diagnosis	Inability to pass sound	Sound: ↑ portio vaginalis	
Treatment	Dilatation if failed hysterectomy	Amputation	Cerculage

OVARIAN MALFORMATIONS

⊙ ACCESSORY OVARY

- ✓ Asymptomatic.

⊙ SUPERNUMERARY OVARIES

- ✓ Accounts for menstruation after removal of both ovaries.
- ✓ The ovarian tissue is found in the broad ligament or retroperitoneal.

⊙ OTHERS:

- ✓ Abnormal descent (may be abdominal), aplasia or hypoplasia or dysgenetic (as Turner look amenorrhea for details اكتبها من هناك)

	FEMALE	MALE
GONAD	Ovary	Testis
GENITAL RIDGE	Infundibulopelvic lig, Ovarian lig & Round lig	Gubernaculum
MULLARIAN DUCT	Tubes, Uterus Upper part of vagina	regress by MIF …remnants (appendix of testis)
WOLFFIAN DUCT	-All regresses except ureteric buds ….ureter -Remnants	-Ureteric bud -Epididymis, Vas , ejaculatory duct, seminal vesicle
PRONEPHROS …….MESONEPHROS …….METANEPHROS ……KIDNEY		
CLOACA : -UROGENITAL SINUS	-lower vagina, hymen, vestibule, Bartholin glands, urethra &paraurethral gland	-prostatic utricle, seminal colliculus, -Cowper gland,urethra
-ANAL CANAL	-bladder -anus	- bladder - anus

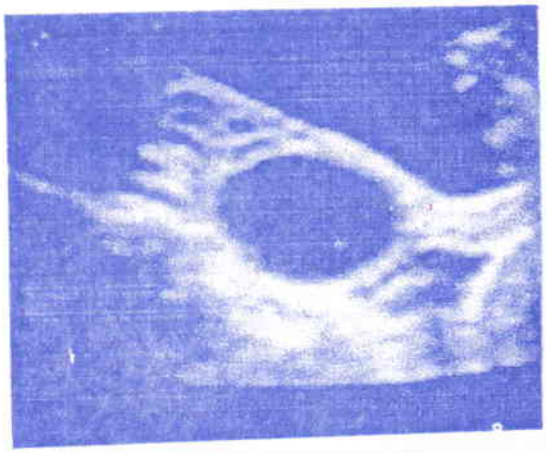

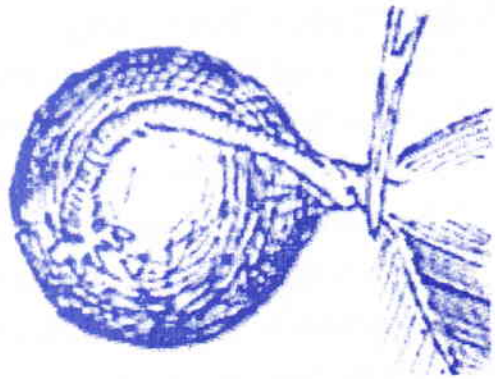

EXT GENITALIA 1-GENITAL TUBERCLE	-clitoris -corpus cavernosum -bulb of the vestibule	-penis -corpus cavernosum -corpus spongiosum
2-GENITAL FOLD	labia minora	-penile urethra (venteral aspect of penis)
3-GENITAL SWELLING	labia majora	-scrotum

Q: Summerize the posible clinical picture of congenital malformation of the female genital system سؤال مهم جدا

- **Asymptomatic** with minor malformation.
- **Menstrual irregularites:**
  1. 1ry amenorrhea solid rudimentary terus.
  2. Cryptomenorrhea: imperforate hymen, transverse vaginal septum, vaginal aplasia, cervical stenosis & cervical atresia.
  3. Dysmenorrhea: hypoplastic uterus, uterus subseptus
  4. Menarrhagia: bicoruate uterus.
  5. Hypomenorrhea: infantile uterus.
  6. Premature ovarian faliure.
- **Sexual proplem:** dysparunia as in vaginal hypoplasia
- **Infertility** e.g oviduct hypoplasia.
- **Pelvic endometriosis** e.g neglected imperforate hymen
- **Pelviabdominal mass** e.g imperforate hymen.
- **Urinary symptoms** &urinary malformation.
- **Pregnancy complications:**
  1. Abortion, ectopic, malpresentation, placental insufficency as implantation on a uterine septum.
  2. dystocia (faliure of cx dilatation, P.P.H & retained placenta)
- **Contraception:** inter fere with intrauterine device in abnormal shape of the uterine cavity.

Reproductive Endocrinology

CONTROLS OF THE REPRODUCTIVE AXIS ®

GNRH → FSH + LH → E + P

1) -VE FEEDBACK

- **Long -ve feedback**: E + progesterone → inhibit Gn RH.
- **Short -ve feedback**: FSH, LH → inhibits Gn RH.
- **Ultra-short -ve feedback**: self inhibition of Gn RH

2) +VE FEEDBACK مهمه جدا جدا

- E (>200 pg/ml, > 50 hr بشرطين) →**LH surge.**
- Progesterone (**small level** بشرط) → **FSH surge.**

3) CNS CONTROL ON THE HYPO-THALAMUS مهم لفهم اللي بعد كده

Stimulatory neurotransmitters

- **Catecholamines (CA):** released from mesencephalon.
- **Catecholesterogen** (= Combination of E & CA مش معروف الهدف منه ايه).
  - ↑ In **starvation** & **hyperthyroidism**
  - ↓In **obesity** & **hypothyroidism.**

Inhibitory neurotransmitters

- **Dopamine**
  - **Inhibits GnRH** (hypothalamus).
  - **Inhibits PRL** (pituitary).
- **Opioids**
  - **Types: ENCEPHALIN, DYNORPHINS & ENDORPHINS☺.**
  - **Play a role in**
    - Stress induced amenorrhea,
    - Premenstrual tension syndrome.
    - Menopausal symptoms
    - Pre- pubertal quiescence. **(GnRH → inhibit FSH & LH)**
- **Serotonin**
  - Inhibits GnRH pulse secretion
- **Melatonin**
  - Released from **pineal body**
  - May play a role in **onset of puberty.**

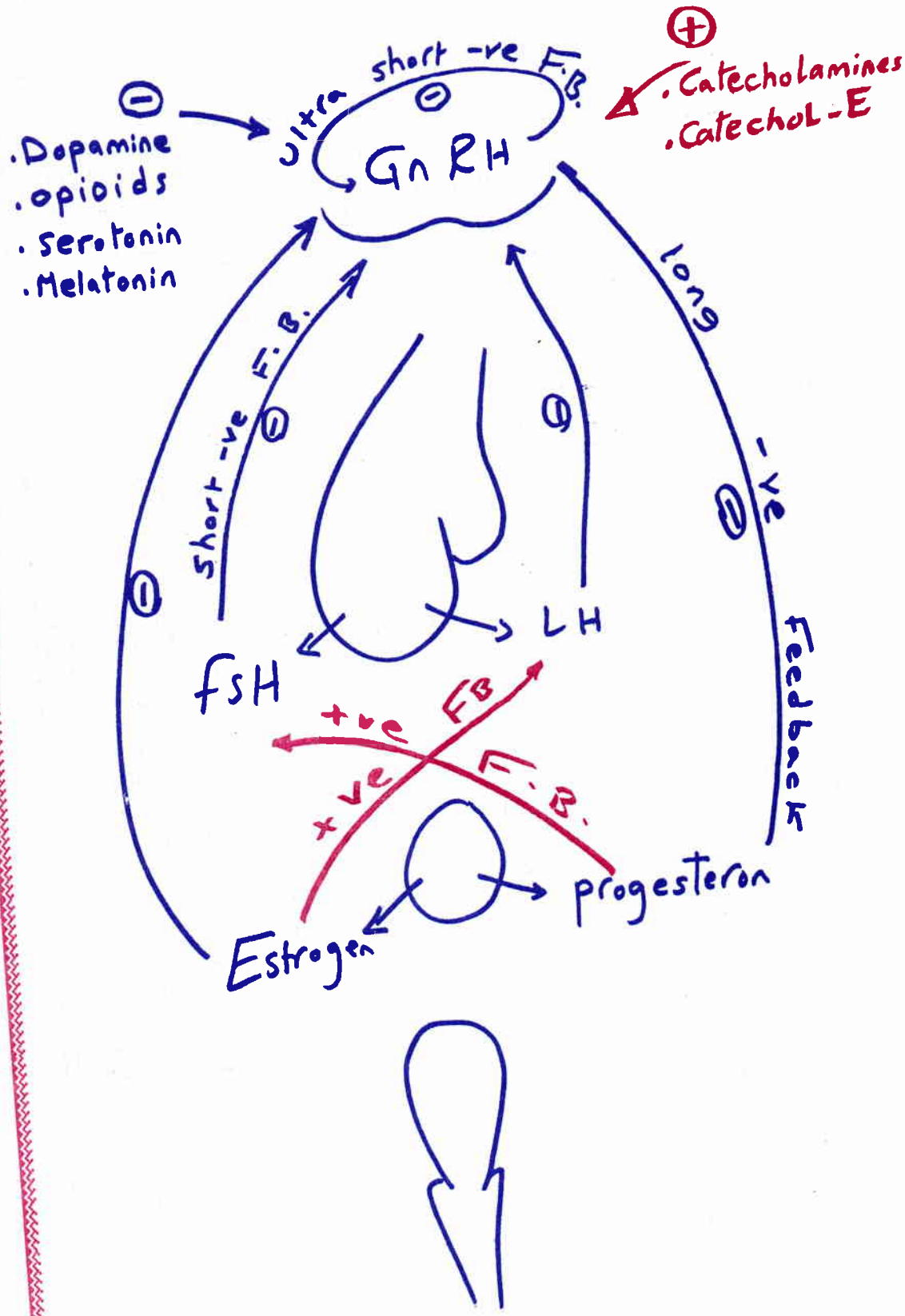
short -ve F.B.
ultra
GnRH
.Dopamine
.opioids
.serotonin
.Melatonin
.Catecholamines
.Catechol-E
short -ve F.B.
long -ve Feedback
FSH
LH
+ve FB
+ve F.B.
Estrogen
progesteron

	GnRH (LHRH اسم قديم)	FSH	LH	HCG
Source	Hypo thalamus	Pituitary (basophils), **placenta®**		Placenta
Nature	➢ **Decapeptide** ➢ **Released from arcuate nucleus of the hypothalamus by:** • Critical amplitude • Critical frequency (70- 200 min) • Critical duration (2-4 min)	➢ **Alpha: 92 aa** ➢ **Beta: 118 aa** -**Glycoprotein** (water soluble) ***CHO part:** glucose, fructose, fructosamine & Sialic acid (→↓ **met. Clearance & ↑ ½ life)** ***Protein part:** α & β	**-Alpha not specific** **-Beta:112aa**	➢ **Alpha not specific** ➢ **Beta:145 da**
Mechanism of action	Horm-Rec. Complex →Internalization→ + Adenyl cyclise →↑cAMP	membrane receptor→stimulate adenyl cyclase →↑cAMP→↑E +P		
Action	➢ Synthesis & storage of FSH & LH ➢ Transform from storage form to releasable one. ➢ Release of FSH & LH	➢ ↑ Its & LH receptors ➢ ↑ follicular size ➢ ⊕Maturation of granulosa cells ➢ FSH surge→ ovulation	➢ LH surge → ovulation **(how?)** ➢ Responsible for luteinisation ➢ ⊕Steroido-genesis by theca cells	➢ Maintains CL of preg. till the placental development ➢ Immuno-modulation during pregnancy ➢ Proper male development
Metabolism	Control: Feedbacks & neurotransmitters	➢ Starts at the receptor by desensitization ➢ Liver ➢ 20 % are excreted in urine unchanged (HMG)		

Clinical uses of GnRH :-

If used in pulsatile manner:

Induction of ovulation

Advantages: no risk of OHSS (as pit-ovarian feedback is working)

If used in continuous manner

Inhibition of FSH &LH → decrease E (medical castration)

So used for:

Superovulation: in the start of invitro fertilization

Inhibiting the ovaries before stimulation by FSH)

Pulse of GnRH :- اي لعب فيه يعمل inhibition



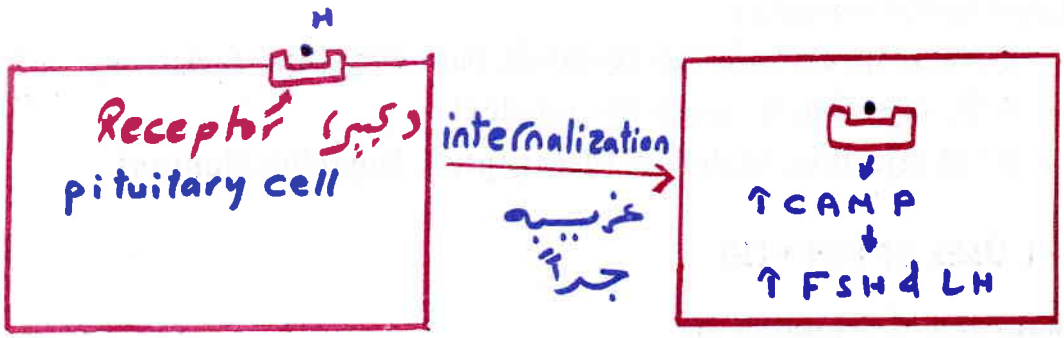

Hormones of The pituitary

مهم جداً

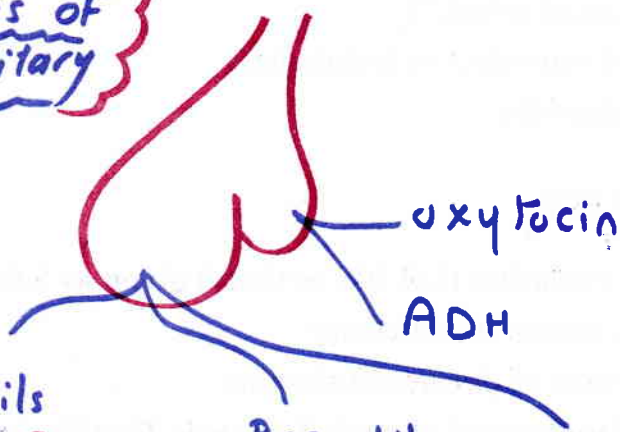

Acidophils
- GH
- PRL

Basophils
- FSH, LH
- ACTH
- TSH
- MSH

chromophobes
- stem cells
- may produce PRL

→ ↓ Premature ovulation (no cancellation of cycles, improving ova quality, ↓premature LH surge)

- ✓ **Contraception**
- ✓ **Some E dependent tumors**: fibroid, endometrial hyperplasia.
- ✓ **Dysfunctional uterine bleeding**
- ✓ **Idiopathic precocious puberty**, idiopathic hirsutism

Side effect: pseudomenopause & osteoporosis: give add back E+P

Uses:(GnRH analogues)

- **Nasal spray**: nafarelin (**synarel**), buserelin (**superfact**)
- **SC injection ®**: goserelin (**zoladex**)
- **IM injection**: triptorelin (**decapeptyl**), leuprolide (**lupron**)

CLINICAL USES OF FSH + LH:

Induction of ovulation in:

- Hypothalmic- pituitary faliure ,
- Clomiphene induction faliure
- Unexplained infertility
- Assisted reproductive techniques
- Male infertility

CLINICAL USES OF HCG:

Induction of ovulation (LH like activity) given as 5.000-10.000 IU/IM

- Corpus luteum insufficiency
- Some cases of threatened abortion

Treatment of undescended testis & male in Fertility

Diagnosis of pregnancy, ectopic pregnancy, aborhon, vesicular male & sone ovarian tunors

ESTROGENS (18 C STEROID)

TYPES:

Natural:

- **Estrone (E1): less potent** (Main E in menopause)
- **Estradiol (E2): most potent** (Arise from the ovary)
- **Estriol (E3): less potent** (↑1000 x during pregnancy.)
- **Estetrol (E4): very weak**, from the fœtal liver

SOURCE:

- Ovary (2 cell theory): follicles & corpus luteum

THE TWO-CELL THEORY غايه في الاهميه

- LH →↑ androgen production by theca cells
- FSH → aromatization of thecal androgen by granulose cells →↑ E

- Adrenal cortex.
- Placenta.
- Extragonadal (peripheral conversion) → 30-40% of E
  - Fat, muscles, brain, intestine, liver (action of aromatase).
  - Androgen→E (most of E in postmenopause)

Semisynthetic

- **Ethinyl Estradiol** (potent, effective orally)
- **Mestranol** = Methylester of ethinyl estradiol

Synthetic :

- **Stilbesterol**
- **Diethyl stilbosterol** not used any more as it is teratogenic مشاكله مهمه

MECHANISM OF ACTION

- Diffusion of E across the cell membrane & nuclear membrane
- Then binds to its receptor on DNA → mRNA → protein synthesis.

ACTIONS:

GENERAL (ANABOLIC + PROLIFERATIVE):

1-BONE & SOFT TISSUE

A. Growth spurt فوران then closure of epiphysis.
B. Protection against osteoporosis
C. Deposition of fat in feminine areas

2-KIDNEY: Salt & water retention.

Two Cell Theory

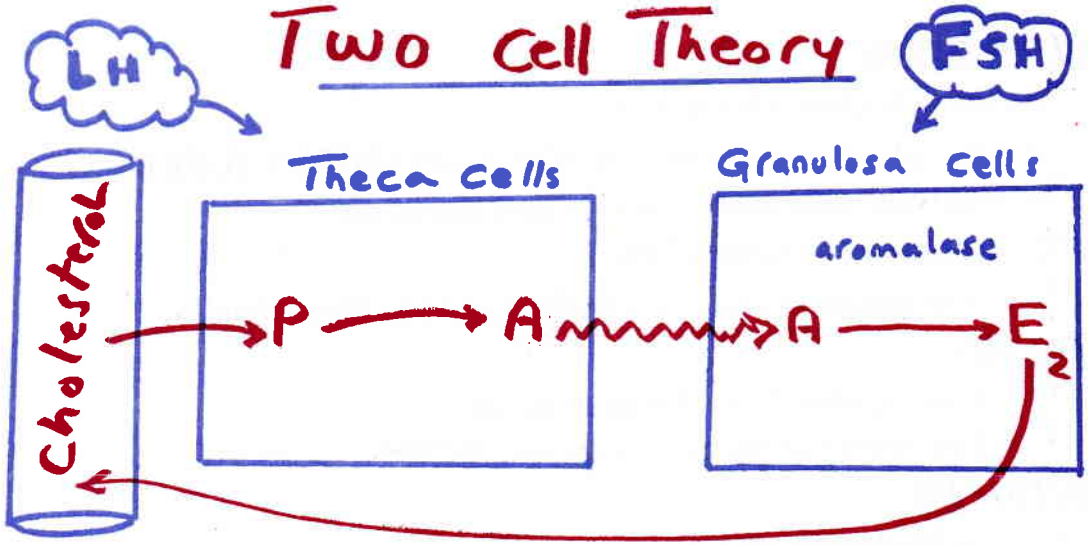

نباتي

- What are phyto Estrogens ?
  - different types as isoflavones
  - Foods as soya beans, vegetables Apples, tomatoes, Carrots, Garlic.

Mechanism of action:-

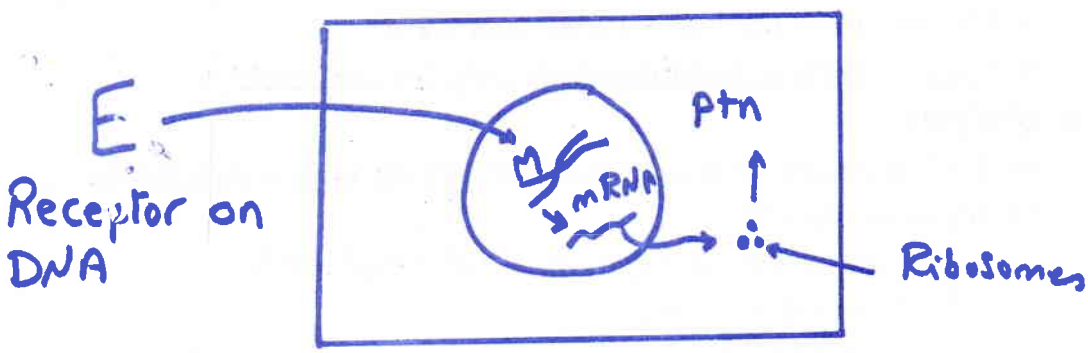

3- **METABOLISM:**

- **CHO**: anti-insulin action
- **Fat**: prevents ischemic heart diseases (↑HDL+ ↓LDL)
- **Protein**: anabolic, +ve nitrogen retention
- ↑ Globulins (SHBG,TBG)
- ↑ Coagulation factors, ↓fibrinolysins (↑ thrombosis).

4- **BREAST:**

- ↑Duct system☺ & Fat deposition
- ↑Prolactin but blocks its action مهمه جدا.

5- **PITUITARY**

- -ve **feedback** on FSH
- > 200 pg/ml >50 hr → **LH surge** فاكر

LOCAL: ↑ VASCULARITY IN ALL GENITAL ORGANS ESP. DURING PUBERTY + PREGNANCY

1. **VULVA:**
   - **Jacqumeir** sign لونها ازرق (congestion)
   - ↑ size & fat deposition
2. **VAGINA:**
   - **Chadwick** sign لونها ازرق
   - Increase thickness of epithelium
   - ↑**Superficial cells**: acidophilic, pyknotic, polygonal
   - Deposition of glycogen in cells +↑ lactobacilli → PH (3.8 – 4.2) = **acidic** (protects against infection)
3. **CERVIX:**
   - **Goodell** sign لونها ازرق
   - Mucus: more profuse (runny clear مائي)
   - Positive **fern** & **spinnbarkeit** tests مهمين جدا جدا
4. **UTERUS:**
   - Endometrium → proliferation & hyperplasia ± carcinoma
   - Myometrium.→
     - ↑sensitivity to oxytocin له دور في بدء الولاده
     - ↑ tone & motility
     - ↑ fibroid size
5. **TUBE:** ↑ vascularity, hypertrophy of muscles & ↑ peristalsis
6. **OVARY:** inhibition of ovulation

Actions of E

bone
pit
breast

3 B

B

+ genitals

SHBG

↑ E

- hyperthyroidism
- starvation

↓ A

hypothyroidism

obesity

♥ USES: سؤال نظرى قبل كده

1-Improve vulval & vaginal atrophic changes and to ↑ healing power :

- Prepubertal & postmenopausal vulvovaginitis
- Vulval dystrophy or pruritis vulvae
- Trophic ulcers in prolapse
- Before & after vaginal surgery in menopause

2-ERT(estrogen replacement therapy)

- Ovarian failure e.g aplasia ,hypoplasia
- Menopausal $
- Some cases of amenorrhea (ut. Hypoplasia)

3-Some menstrual disturbances :

- Dysfunctional uterine bleeding
- Dysmenorrhea

4-Infertility to improve cervical mucous

5-contraception in contraceptive pills

♥ METABOLISM:

- 1% free (THE ACTIVE FRACTION)
- 99% →
  - SEX HORMONE BINDING GLOBULINS
    - ↑SHBG: In hyperestrogenism, hyperthyroidism, starvation
    - ↓SHBG: hyperandrogenism, Hypothyroidism, obesity
  - ALBUMIN
- **Excretrion** mainly by:
  - The liver
  - Kidney

PROGESTERONE (21 STEROID)

TYPES:

Natural (21c) (Uterogestan, Duphaston الاسماء التجاريه):

- 17α OH progesterone (adrenal source.)
- 17β OH progesterone (Pure ovarian source→reflects CL function).

SOURCE:

- **Ovary**: corpus luteum (main site)
- **Adrenal cortex**.
- **Placenta**.

Synthetic (progestins or progestogen) الاسماء مهمه:

- **1st generation:**
  - **ESTRANE** (19 nor-progesterone) similar to testosterone as:
    - norethindrone, norgestrel, norethisterone
  - **PREGNANE** (17 acetoxy) similar to progesterone as:
    - medroxy progesterone acetate
- **2nd generation**: Levonorgestrel
- **3rd generation (new progestins):** ↑ potency + ↓ androgenic effects
  - DESOGESTREL (**Marvelon** اقلهم تاثيرا علي القلب)
  - NORGESTIMATE (**Cilest**)
  - GESTODINE (**Gynera**).

MECHANISM OF ACTION

- **Diffusion** of progesterone across the **cell** & **nuclear membrane**
- Then binds to its **receptor on DNA** → **mRNA** → **protein synthesis**.

ACTIONS:

GENERAL

1-BRAIN:

- Thermogenic (↑ basal body temperature).
- ⊕ Respiration (especially in pregnancy ↑ **depth not rate** مهمه جدا)

2-KIDNEY: Salt & water retention.

3- MUSCLES:

- Relaxes smooth muscle (GIT, ureter)

4-BREAST:

- ↑Alveolar system☺
- Blocks the action of prolactin مهمه جدا.

5- **PITUITARY**

- -ve **feedback** on FSH& LH
- Small level → **FSH surge** فاكر

LOCAL (PREPARE FOR PREGNANCY)

ONLY IF TISSUES ARE PREVIOUSLY RESPONDED TO OESTROGEN

1. **VAGINA:**
   - ↓Thickness
   - ↓ acidity
   - ↓ Maturation (↑ intermediate cells →folded basophilic cells)®
2. **CERVIX:**
   - Mucus: ↓ amount (viscid) & cellular
   - Negative **fern** & **spinnbarkeit** tests مهمين جدا جدا
3. **UTERUS:**
   - ENDOMETRIUM:
     - **In luteal phase**: secretory
     - **In pregnancy**: decidua & atrophy لو استخدم لفتره طويله
   - MYOMETRIUM →
     - ↓sensitivity to oxytocin له دور في بدء الولاده
     - ↓tone & motility
4. **TUBE:** ↓ peristalsis
5. **OVARY:** inhibition of ovulation

♥ **USES:** سؤال نظري

OBSTETRIC	GYNECOLOGY	+/- ESTROGEN
-Threatened abortion - habitual abortion -CL insufficiency -Surgery in pregnancy	-Endometriosis -Endometrial hyperplasia & carcinoma	- some cases of amenorrhea - HRT -Dysfunctional uterine bleeding -premenstrual tension. -Contraceptive pills

♥ **METABOLISM:**

- 1% free (THE ACTIVE FRACTION)
- 99% → Bound to SHBG, Corticosteroids binding globulins
- Metabolized mainly in **liver**

ANDROGENS (19 C STEROID)

- **TYPES:**
  - **Natural (19c)**
    - **Dehydroepiandrosterone (DHEA)**: ↑ in adrenal tumors
    - **Androstenedione**: major androgen of the ovary
    - **Testosterone:** ↑ in ovarian tumors

OVARY		ADRENAL
25%	TESTOSTERONE	25%
50%	ANDROSTENEDIONE	50%
10%	DHEA	90%
0%	DHEA-SULPHATE	100%

SOURCES: (They are intermediate steps in synthesis of estrogens)
- OVARY (theca & stroma cells)
- SUPRARENAL CORTEX
- PERIPHERAL CONVERSION (Testosterone → dihydrotestosterone)

- **Synthetic**
  - Methyl Testosterone (oral).
  - Testosterone propionate (injection)

- **MECHANISM: AS OTHER SEX HORMONES**

- **EFFECT:** Too low to cause any effect → if ↑ as in PCO or TUMORS →
  - An-ovulation
  - Defeminization followed by virilization & hirsutism.

- **USES** Not preferred because of above side effects:
  - -Vulval dystrophies (atrophic types)
  - -Menopause (usually in combination with estrogen)
  - -Endometriosis (progesterone better)
  - -Premenstrual tension (not acceptable) & decrease libido

- **METABOLISM:**
  - 99% bound to SHBG & 1% free.
  - Metabolism occurs in the liver mainly & peripheral tissues.

- **N.B.** Wolffian system depend on T while UGS depends on DHT

THE OVARIAN CYCLE

THE FOLLICULAR PHASE

- **Every month:**
  - **400 -1000** follicle grow
  - Only **4 -10** continue to grow & the others atrophy
  - At last **1** succeeds to ovulate.
- **The primordial Follicles (50 micron):**
  - It is :
    - **Oocyte** in the prophase of 1st meiotic®
    - Surrounded by single layer of **granulose cells**
  - the **1ST VISIBLE SIGN** that they will resume growth يعاودوا نشاطهم is the change of granulosa cells **from squamous to cubical**☺
  - it is **IRREVERSIBLE** stage (**continuum**) either:
    - Ovulate or
    - Atresia occurs
- **Pre-antral Follicles (200 microns)**
  - **The granulosa cells:**
    - Proliferate under FSH & produce estrogen (E2 النوع القوي)
    - E →↑FSH receptors with ↑ follicular growth (snow balling effect)
  - **Theca cells**
    - **Differentiate** from surrounding stroma (باكد عليك انها جايه من stroma)
  - **The Two-cell theory®** مهمه جدا
    - **LH** →↑ androgen production by theca cells
    - **FSH** → aromatization of thecal androgen by granulose cells →↑ E
- **Antral Follicles**
  - **The granulosa cells**
    - More mitosis
    - Form Call-Exner bodies →coalescence→ antrum (rich in FSH, E).
  - **The theca cells** are differentiated into
    - Theca interna &
    - Theca externa
  - **The oocyte**
    - It is surrounded by Cumulus Oophorus

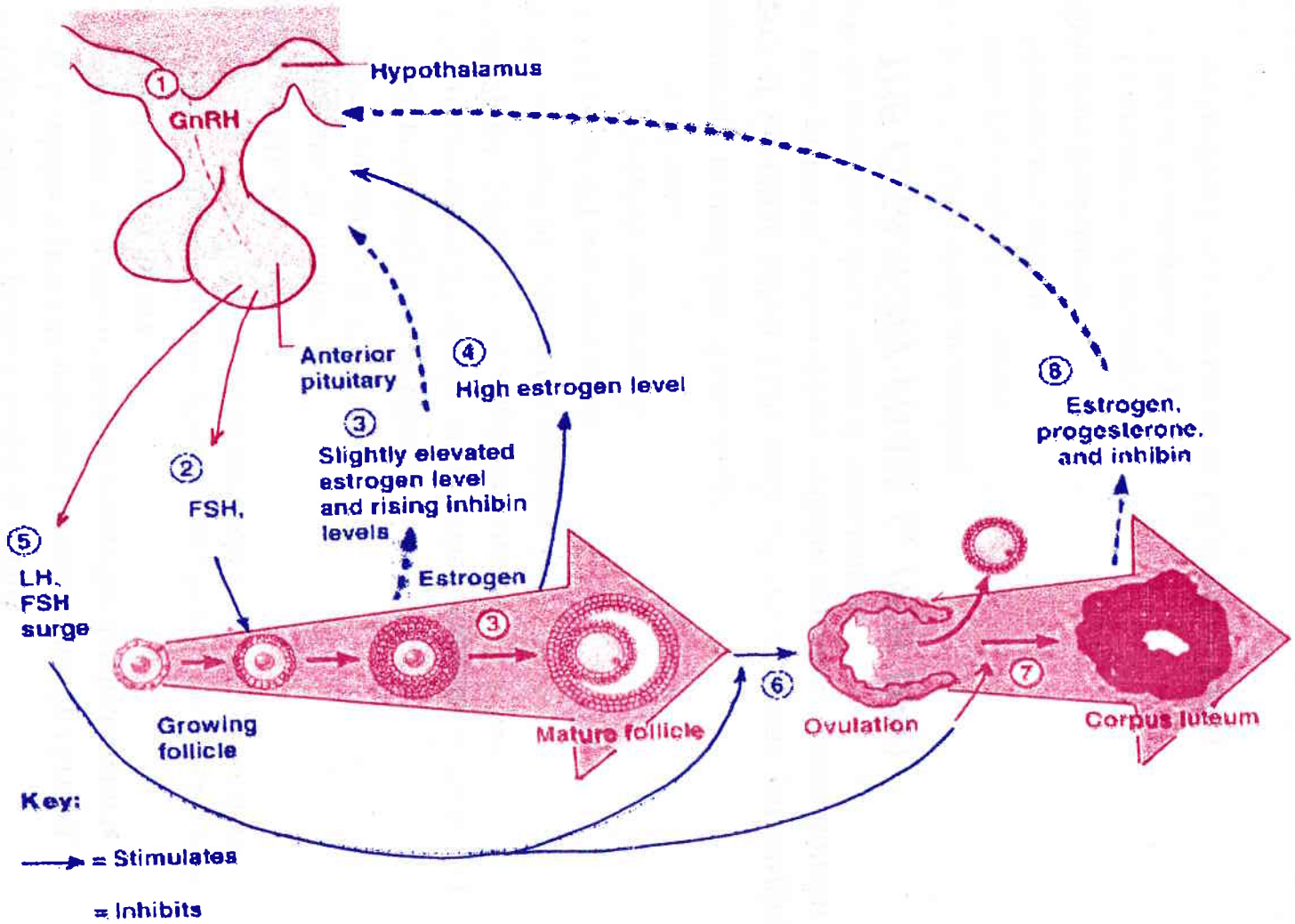
Hypothalamus
1
GnRH
Anterior pituitary
4
High estrogen level
3
Slightly elevated estrogen level and rising inhibin levels
2
FSH,
5
LH, FSH surge
Estrogen
3
Growing follicle
Mature follicle
6
Ovulation
7
Corpus luteum
8
Estrogen, progesterone, and inhibin
Key:
= Stimulates
= Inhibits

- **Pre-ovulatory Follicle (18 – 24 mm☺)**
  - **The granulose (G اختصار مقبول) cells**
    - **More mitosis** → produce more E & inhibin
    - **E & inhibin**→↓FSH→↑androgen (↓aromatization in G-cells)
    - **↑androgen** → atresia of follicles except the dominant follicle
    - **The dominant follicle**
      - Has the highest number of receptors تشعر باقل مستوي من الهرمون
      - It is evident in the 7th day of the cycle نشوفها بالسوناراكبر واحده.
  - **1ry Oocyte (46 XX واخد بالك)**
    - Completes 1st meiotic →
      - 2ry oocyte (23 X واخد بالك) &
      - 1st polar body in perivitelline space
    - 2ry oocyte enters 2nd meiotic (stops at the metaphase مش حتكمله الان)
  - **E2** >200Pg/ml >50 hrs (*1 - 1½ d before ovulation* مهم هذا التوقيت)
    - →LH surge (*10 – 12hrs before ovulation* مهم هذا التوقيت)
    - LH surge →↑ androgen which
      - Completes the atresia &
      - ↑ libido
  - **Progesterone in small dose** →FSH surge
  - **Layers of Graafian follicle (±20 mm)** من جوه لبره: ovum, perivitelline space, zona pellucida, corona radiate, cumulus oophorus, antrum folliculi, membrana granulosa, theca interna & theca externa.

THE OVULATORY PHASE (± 14TH DAY)

1. **LH surge** → ↑c-AMP which antagonizes:
   - Oocyte maturation inhibitor
   - lutenization inhibitor.
   - **It is short lived due to:**
     - Consumption of pituitary stores
     - Loss of +ve feedback by E
     - -ve feedback by progesterone on LH & LH on GnRH
2. **FSH surge**
   - ↑ LH receptors
   - Stimulate *plasminogen activator* → plasmin → separation of the oocyte cumulus cell moaa from the rest of the follicle

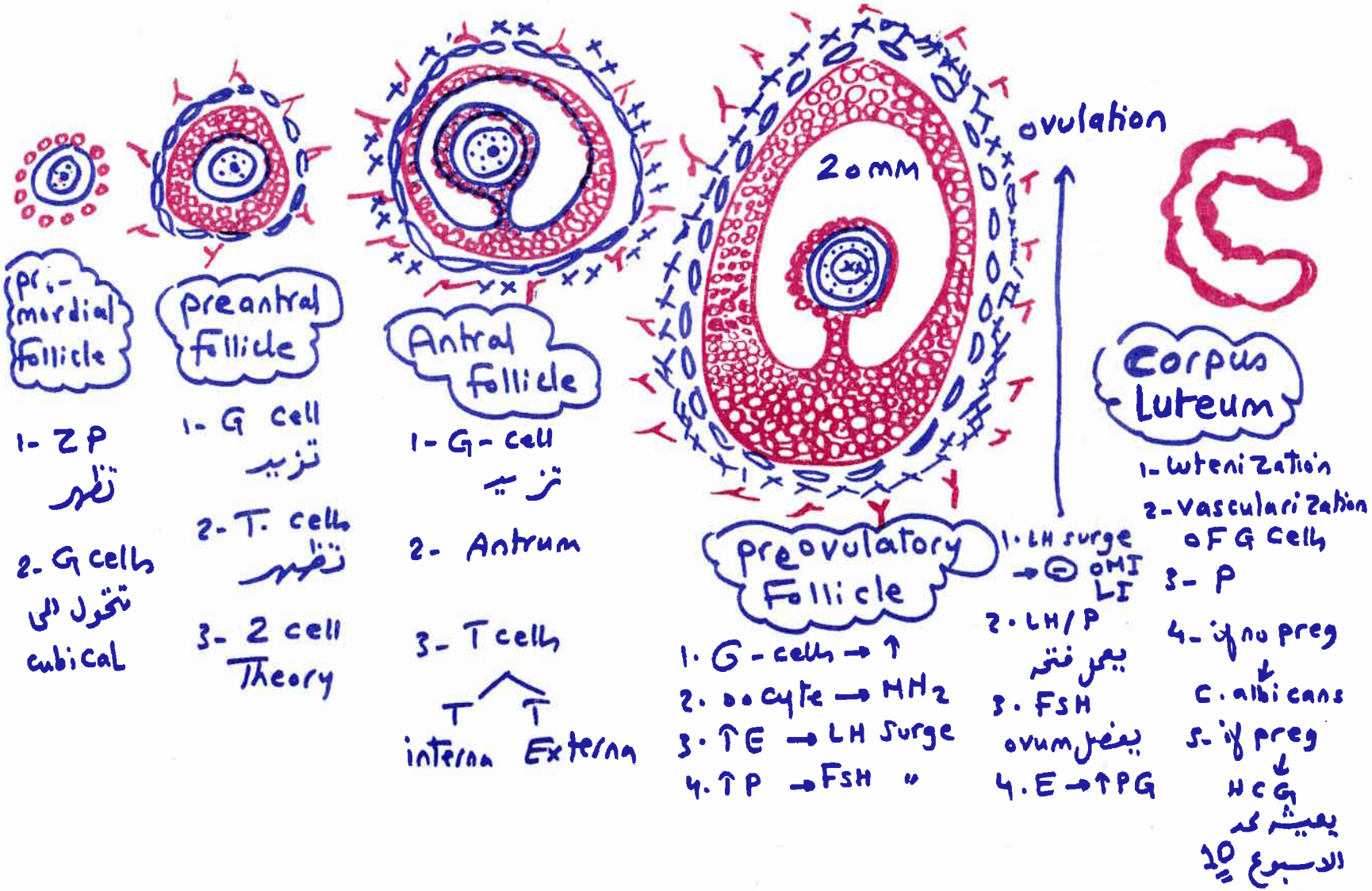
ovulation
20mm
Primordial follicle
1- ZP
تظهر
2- G cells
تتحول الى
cubical
preantral follicle
1- G cell
تزيد
2- T. cells
تظهر
3- 2 cell Theory
Antral follicle
1- G- cell
تزيد
2- Antrum
3- T cells
T T
interna Externa
preovulatory Follicle
1. G-cells → ↑
2. oocyte → MH2
3. ↑E → LH surge
4. ↑P → FSH "
1. LH surge
→ ⊖ OMI
LI
2. LH/P
يعمل فتحة
3. FSH
ovum يفصل
4. E → ↑PG
Corpus Luteum
1- luteinization
2- vascularization
of G cells
3- P
4- if no preg
↓
C. albicans
5- if preg
↓
HCG
يعيش لحد
الاسبوع 10

3. **LH & progesterone:** ⊕plasmin & collagenase → **degeneration of collagen**
4. **PG:**
   - It arises under the effect of E
   - It stimulates contraction of smooth ms of the ovary → **ovum expulsion.**

THE LUTEAL PHASE (14 DAYS زي الساعه فتره ثابته)

1.Corpus luteum:

- it is formed by deposition of lutein (rich in cholesterol & carotene) in
  - **Granulosa cells** → lutein cells
  - **Theca cells** → paralutein cells

2.Vascularization of granulosa cells لاول مره

3.Progesterone:

- Peak 7-8th day post ovulatory
- It acts:
  - CENTRALLY→↓ LH
  - LOCALLY→ inhibits other follicles

4.E →↑ PG's →**luteolysis**→ corpus albicans

5.If pregnancy occurred → **HCG** →maintains corpus luteum

Hormonal changes during the menstrual cycle

- LH: 1 peak just preovulatory
- Progesterone:- has one peak at day 21
- FSH:- has 2peaks 1st at the start of the cycle & 2nd just pre-ovulatory
- Estrogen: 2peaks 1st pre-ovulatory & 2nd at day 21

مهم جدا للحفظ	Follicular phase	Luteal phase
Estrogen	30-75 pg/ml	200-300 pg/ml
Progesterone	<1ng/ml	>12 ng/ml
Testosterone	0.2-0.8 ng/ml	
Gonadotrophins	♂FSH: 5-30 mIU/ml	♂LH: 5-20 mIU/ml
Prolactin	2-20 ng/ml	

The pituitary cycle

Can be divided into 3 phases:-

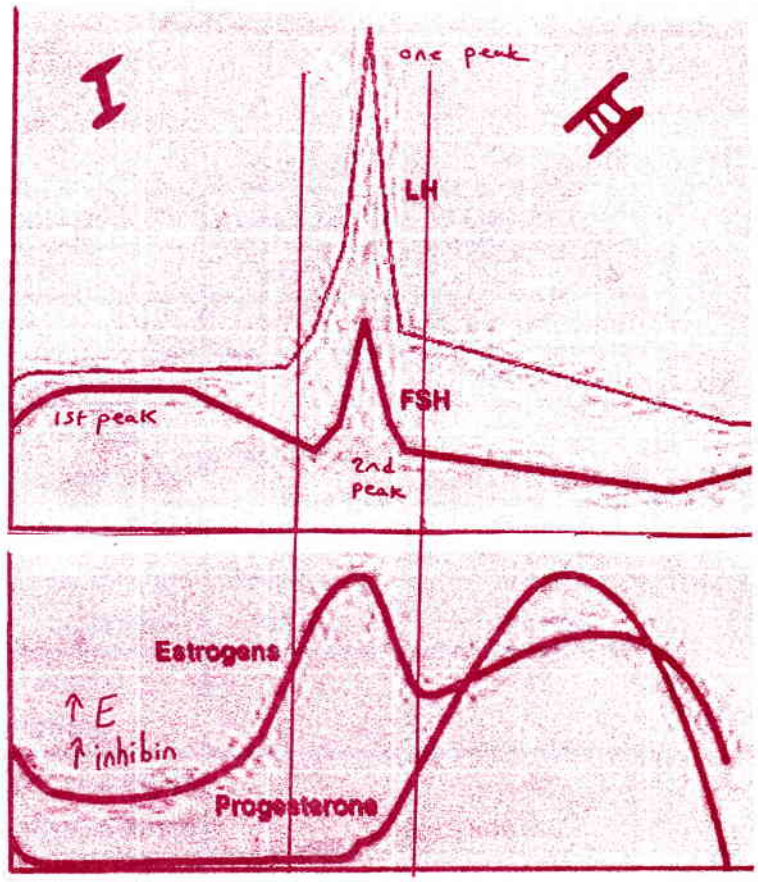

phase I:- initiation of the cycle by ↑GnRH pulse & ampl.

bec. → ↑F (1st)

→ ↑F G

Then FSH ↓ by inhibin & E from growing follicles

phase II :- - LH surge :-

- FSH surge :-

Phase III :- ↑ P → ↓ GnRH → ↓ FSH, LH → atresia of CL

→ menstruation

THE ENDOMETRIAL CYCLE

Upper 2/3 of the endometrium

- **Functional layer** (→implantation -secretion - menstruation)
  - ⇨ **Zona compactum** (1/4 thickness) around the necks of endometrial glands
  - ⇨ **Zona spongiosum** (1/2 thickness) around the bodies.

Lower 1/3

- **Basal layer** →regeneration
  - ⇨ **Zona basalis** (1/4 thickness) around the bases of the glands.

Phase		Regeneration	Proliferation	Secretory phase
Duration	Menstrual 2 - 5 d	1-2 days	9- 10 days	14 days
		from basal gland	E effect	Progesterone effect
Endothelium		1-2 mm thick	3-4 mm	7-8 mm thick
Epithelium		Cuboidal	Columnar	High col. + secretory (subnuclear vesicles)
Gland		Simple Tubular Narrow	Few no. Elongated dilated	Tortuous cork screw appearance (saw toothed) + secretions
Stroma		↑	↑↑	↑ + edema + leucocytic infiltration
Vessels		↑	↑↑	Basal a. → basal part spiral a → superficial part

MENSTRUAL PHASE :

Mechanism:

i. **Endometrium Shrinks** → ↑ coiling of spiral arteries (8 coils) → ischemic necrosis of the Endometrium.

ii. **WBCS extravasate in the stroma** → disintegration of the stroma.

iii. **↓Progesterone** → ↑ $PGF_2\alpha$ → VC of spiral arteries (for 24 h) then,

iv. **Dilatation (by PGE 2 & PGI 2)** → Extravasations of RBCs into the stroma & Endometrium.

v. **1st blood** occurs from spiral arteries (75%) then from coalesced blood Lakes in the endometrium + endometrial capillary & veins

vi. **Composition:** blood, endometrial shreds, FDPs, leukocytes, cervical mucous, desquamated vaginal epithelium, bacteria flora

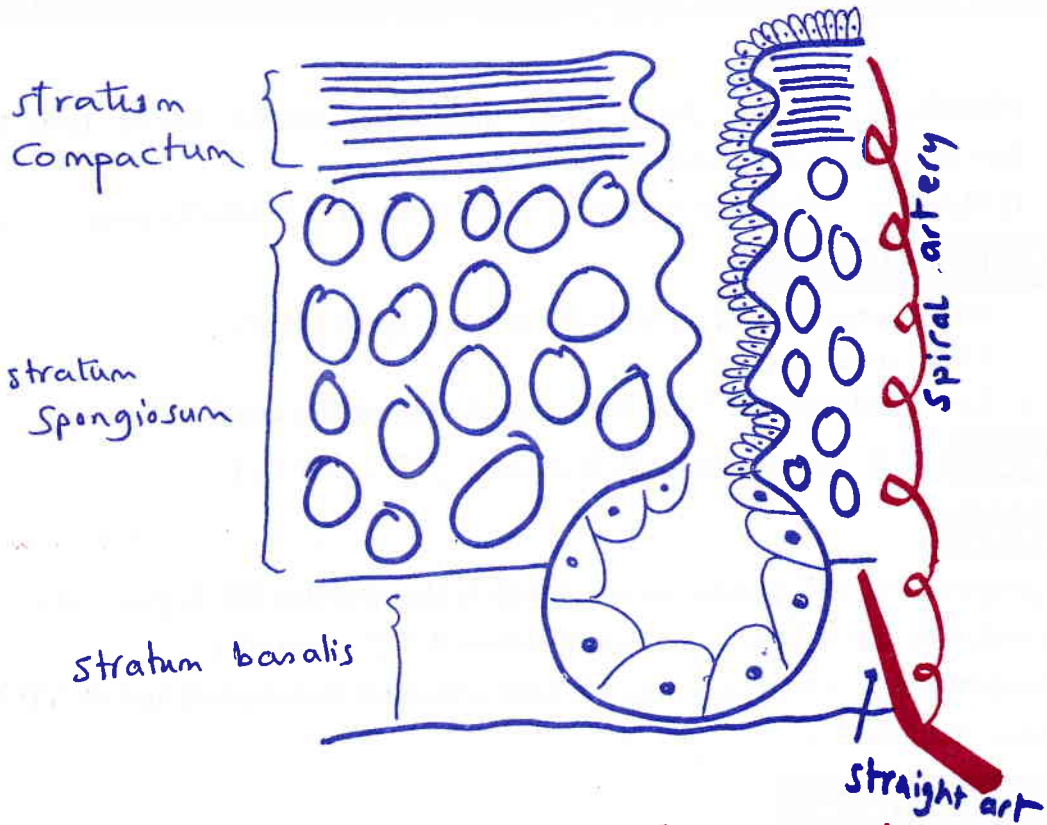

Layers of the endometrium

cycle

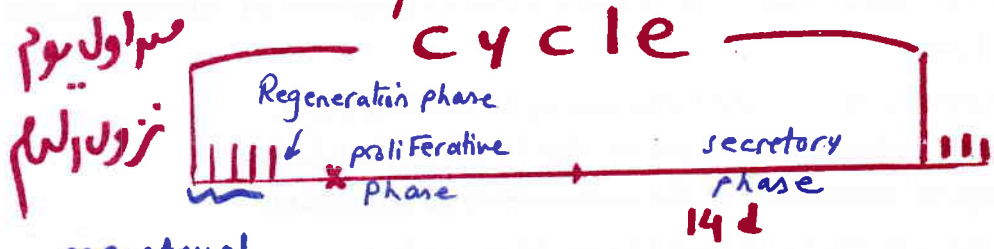

Normally

- Cycle 3-5 wk
- Duration 3-5 days
- Amount 30-50 ml

vii. **Menstrual Shedding** forms clots inside the uterine cavity then by fibrinolysis, fluidy blood pass outside

viii. **If bleeding** > fibrinolytic system, blood clots pass + colicky pain

MENSTRUAL STOPPAGE

1- Homeostasis plug of platelets & fibrin into spiral arteries
2- VC of spiral arteries.
3- Re-epithelization (3rd - 4th day) starts at isthmus & cornual ends.

NORMALLY 3-5 days every 3-5 weeks (30 - 80 ml)

ROLE OF PG

- ↓ *progesterone* → ↑ endoperoxides (endo & Myo mchium BG المادة الخام لل) .
- *In endomertium* →↑ PGF_2 & thromboxanes→ VC of spiral a.
- *In myometrium* → PGI_2 & PGE2 → back diffusion to endometrium → VD & massive blood loss

ENDOMETRIAL DATING

❖ **Def:** relating the histopathological finding of the endometrium with the date of the menstrual cycle. It has a value in diagnosis of infertile women.

Procedure:

1) Diagnostic test to determine timing of the ovulation.
2) Collect endometrial biopsy on day 10-12 postovulation.

Histological assessment of the endometrial development.

> 2-days lag time is termed a luteal phase defect.

CLINICAL ASPECTS OF THE MENSTRUATION

(1) **The volume of menstrual flow ± 50-80 ml/ cycle. Measured by:**

1. **Direct method**: collecting the loss in cervical caps (difficult).
2. **Indirect method**: by lysing the hemoglobin out of all the collected menstrual pads. That is inelegant but valid method.
3. **Practically**:
   A) Blood clots at the menstrual blood → excessive amount of loss.
   B) Sharp increase in the number of pad used.

(2) **Character**: dark altered liquid blood + vaginal secretion. It does not clot

(3) **The duration of menstrual cycle:**

1- **The length** = 28 days ± 7 days.
2- **Duration** = 2-6 days. Max loss is on day 2.

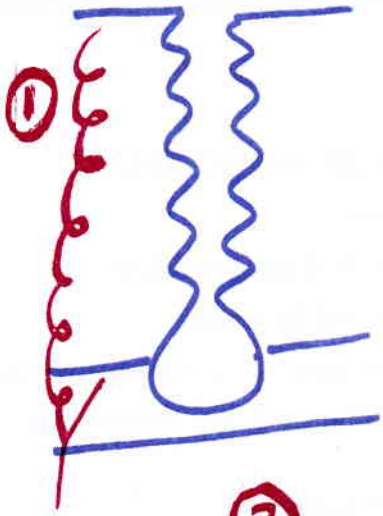

Extravasation of leucocytes

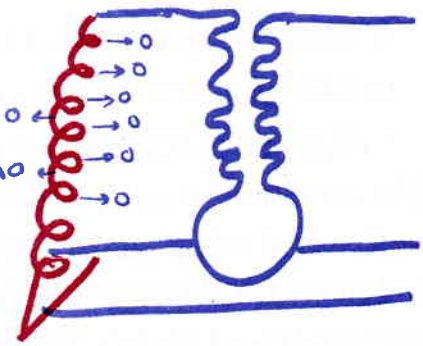

Collapse of endometrium

Disintegration of endometrium



ثم

4 Severe VC

ثم

5 VD

مع نزول دم للدورة

في الأول arterial 75%

ثم veins + sinuses.

(4) Symptoms at normal menstruation:

A) Minor subjective acceptable symptoms (menstrual molmina)

B) NO Symptoms : these are a minority of women.

C) Marked symptoms : as premenstrual tension & dysmenorrhea.

(5) The menstrual hygiene: **Either of two methods could be used:**

A- **External vulval sanitary pad :** changed 2-3 times /day → 12-18 pads/ cycle.

B- **Intra-vaginal tampon :** It should be removed & changed 3-4 times daily.

Disadvantages of the internal tampon:

1-They are inadequate if the loss is heavier than average.

2- Missing tampon → Toxic shock syndrome.

CLINICAL ASPECTS OF OVULATION

❖ History suggestive of ovulation (their absence does not mean anovulation):

1- Regular cycles.

2- Midcycle ovulatory pain (Mittelschmerz), due to irritation of the peritoneum, by released blood from the follicle.

3- Ovulatory discharge : ↑watery discharge due to ↑ cervical mucus.

4- Ovulation spotting : due to transient ↓ in estrogen level.

5- premenstrual symptoms: e.g. mastalgia.

6- Spasmodic dysmenorrhea.

Cycle	Polymenorrhea < 21 day	Oligomenorrhea > 35 day
Duration	Hypomenorrhea < 2 days	Menorrhagia > 7 days
Amount	Hypomenorrhea < 30 ml	Menorrhagia > 80 ml

	Proliferative phase (max preov)	**Luteal phase**
Cervical mucus	➢ ↓viscosity (↑ NACL & KCL) ➢ +ve spinnbarkeit ➢ +ve fern test	➢ ↑ viscosity ➢ - ve spinnbarkeit test ➢ - ve fern test
Vagina	➢ ↑superficial cells (Polygonal, Acidophilc, Pyknotic nuclei (small dark & dense chromatin)	➢ ↑intermediate cells {folded cytoplasm (navicular), basophilic & clear vesicular nuclei}
Tube	↑ movement ↑secretion (max before ovulation)	↓↓↓
	➢ Shrinkage & slight shedding occurring during menstruation	



The Spinnbarkeit



The Fern Test

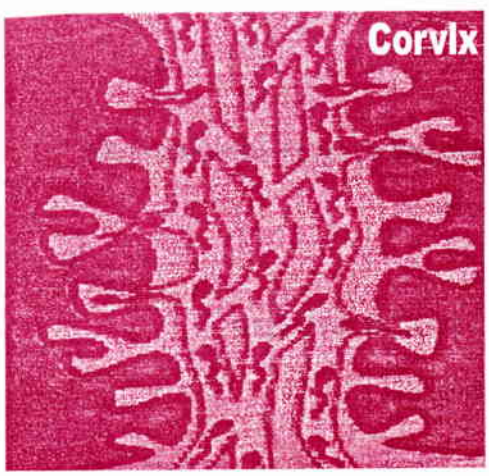

Cx mucus by EM microscopy

PUBERTY سؤال نظري قبل كده

DEFINITION التعريف مهم جدا

- **It is:**
  - **Physical, sexual & psychological maturation** of the female
  - With **development of 2ry sex characters** &
  - Ends by **menstruation** & **growth spurt**,
- It starts at age **8-16 years** (average 8-13), girls +/- 2 years earlier than boys.
- Puberty s a **period®** of time (2-5 years), menarche is an **event☺**
- VARIATION OF AGE OF START OF PUBERTY IS DUE TO MANY EFFECTS AS

  1-Constitutional, genetic predisposition

  2-Psychological factors

  3-Nutrition, activity (**athletes have later puberty**)

  4-Melatonin release from pineal body

WHY NO E BEFORE PUBERTY ☺? (Very little in childhood)

- *Very sensitive hypothalamic - pituitary axis* to - ve feedback of steroids.
- *Presence of CNS inhibitory factor* which may be melatonin.

AT PUBERTY:

- This feedback is less sensitive
- Disappearance of the inhibitory factors
  - ⇨ increase LH+FSH & estrogen

NORMAL EVENTS AT PUBERTY

1. **Somatic changes**

   A. Growth spurt (1st sign) + Deposition of fat in feminine areas

   B. Persistence of high pitched voice

2. **Adrenarche** → ↑DHEA.
3. **Thelarche** → breast bud appears 9 - 11 y (1st sexual sign).
4. **Pubarche** → scanty pubic & axillary hair.
5. **Menarche** → 1st menstrual period.
6. **Genital changes (↑E)** → development of genital organs

TANNER CLASSIFI CATION FOR DEVELOPMENT OF BREAST + PUBIC HAIR

	I= <9 yrs	II= 9-10 yrs	III= 11 yrs	IV= 12 yrs	V= 14.5 yrs
Breast bud	–	Elevation	More elevation	2ry mound (Areola projects out)	Regression of 2ry mound
Pubic hair	No	Scanty on labia majora	Scanty on mons pubis	Normal adult on mons (Dark coarse & curly)	Normal adult distribution

Pediatric, pubertal, adolescent abnormalities سؤال نظري

- **CONGENITAL**: ambiguous genitalia, congenital labial adhesion
- **TRAUMATIC**: circumcision, sexual abuse, accidental trauma
- **INFLAMMATORY**: prepubertal vulvovaginitis
- **NEOPLASTIC**: sarcoma botryoids (vagina), germ cell tumor (ovary)
- **MISCELLANEOUS**:
  - Prepubertal vaginal bleeding especially due to foreign body
  - Early puberty → precocious puberty
  - Delayed puberty

Precocious Puberty

Definition

- Appearance of pupertal changes **earlier than 2 standard deviation** below the mean for a given community النص مهم
- **in USA (1988)®:**
  - appearance of 2ry sexual character before 8 yrs or
  - the onset of menarche before 10 yrs

Types

1- isolated (incomplete = premature) precocious puberty:
- Adrenarche
- Thelarche (one side or both)
- Pubarche

Before 8 yrs with **no ↑ E** اهم نقطه = **↑tissue sensitivity**

- Usually regression occurs after few months and other pubertal changes occur normally so **reassure the patient**.

pediatric, pubertal & adolescent abn

C :- amb / Cong Labial

Trauma :- - Cir
- FB
- Sex

Inflammatory :-

Neoplasm :- S
G

Misc :- P P

Bleeding

من بيرو

Little Girl Pregnant at the age of 5!

A man from a small village in the Andes Mountains carried his five-year-old daughter into a hospital.The father told Dr. Gérado Lozada that her daughter strangely having **regular periodssince age three**, but they had **stopped about 7 1/2 months prior to the visit.** Dr. Gérado listened to the young girl's abdomen with a stethoscope, and heard **a tiny second heartbeat.** An X-Ray was also performed, after which there could be no doubt... to the doctors' astonishment, **five-year-old Lina Medina was about seven months pregnant!**

Tanner staging

Breast bud

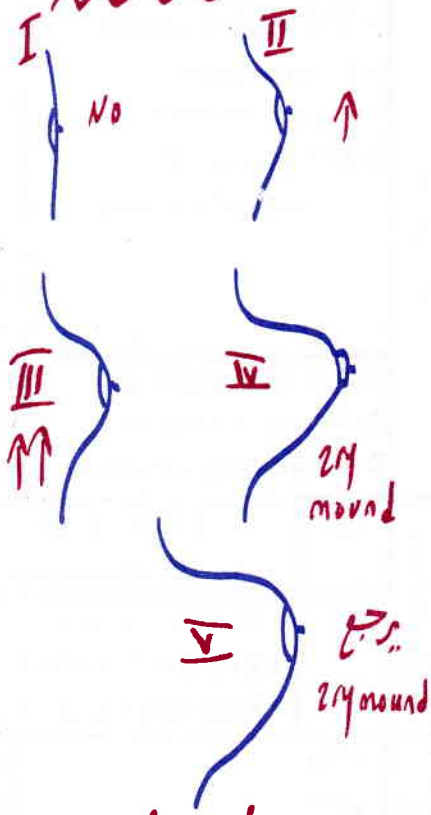

pubic hair



2- complete precocious puberty:

	Iso-sexual = ↑ E		Heterosexual = ↑ androgens
	TRUE (CENTRAL)	FALSE (PERIPHERAL)	
Causes	▷ C→constitutional 90% ▷ T→ skull fractures ▷ I →meningitis / encephalitis ▷ N→ pineal / 3rd ventricle tumor	✎ **Endogenous** → Tumor, hypothyroidism. ✎ **Exogenous**: COC intake ✎ **McCune-Albright $** ✓ *Polyostotic fibrous dysplasia* → pathological fractures سبب الوفاه ✓ *Café âu laît Patches* ✓ *Precocious puberty* (↑ E) ✓ *Hyperthyroidism or Cushing $*	**1- OVARIAN:** ✱ **Tumor** *Sertoli-Leydig.* ✱ **PCO:** *commonest cause* **2- ADRENAL:** ◈ CAH ◈ Tumor ◈ Cushing syn. **3- IATROGENIC**
	↑ Gonadotrophins Normal ovulation Pregnancy can occur	No ↑ in gonadotrophins No ovulation → no pregnancy Only feminization	
Diagnosis – **Symp**	• PH of surgical operation & drug use. • FH of similar condition.		
Diagnosis – **Ex**	• Hirsutism / acne. • Examine breasts & external genitalia. • Neurological & endocrinal examination		
Investigations	• ↑E • P ↑ • ↑ FSH & LH. • **BRAIN**: CT, MRI, U/S	✈ ↑ E only ✈ ↓ FSH & LH. ✈ U/S or laparoscopy. ✈ **BONE SCAN** in McCune Albright	• ↑T→ ovarian causes →U/S & laparoscopy. •↑DHEA→ adrenal cause → MRI & CT. •17αOH progesterone
Investigations – **Bone age:**	⇨ **Retarded** in **hypothyroidism**, ⇨ **Normal** in **isolated PP** & ⇨ **Advanced** (tall child but short adult) in **isosexual** or **heterosexual** PP		
Treatment	• Treatment of the **cause** • **familial:** Reassurance • **Medical (till 12 yr):** ✍ **P**: 400mg/3m Anti E+ Block FSH & LH ✍ **GnRH** الاحسن للعظم	• **Treatment of the cause**: thyroxin for hypothyroidism • **Tumor**:- remove • **Testolactone** 20mg/kg for non central causes as McCune-Albright $	• **Antiandrogens** for Hirsutism • **Tumor** → remove • **CAH** → Steroids for life

N.B.: CAH = congenital adrenal hyperplasia, T = testosterone

Precocious puberty

- Complete → Iso sexual
  - ♂ سريه
  - ♀ سريه
- incomplete → premature
  - Thelarche (breast)
  - pubarche (pubic hair)
  - adrenarche (axillary hair)
  - III ← نظمن المريضه صتخف لوحدها
- الاعراض < 8 y
- الدوره < 10 y

Iso sexual

True

ممكن تخلف

Cause: ↑ الاكثر CTINM
- brain ن

inv: ↑ FSH

III:
- of cause
- constitutional
  - نظمن المريضه
  - E نعاكس
  - الاقوى GnRH — الارضعف P

False

مش ممكن تخلف

Cause: ↑E
- مبيض
  - مرجوه
  - -T
  - - Hecune A1-7
- مبيض طاطا

inv: ↓ FSH الاهم

III: of cause

hetero sexual

Cause = ↑ A
- مبيض
  - ovary
    - PCO
    - Tr
  - adrenal
    - CAH
    - Tr
- مبيض بابا مبيض

inv: لنعرف نوع A اللي زايد
- ↑ Testosterone → pelvic US
- ↑ DHEA → Abd CT

III: of cause

Delayed puberty amenorrhea تعامل معامله ال

❖ **DEFINITION:**

- No menarche by 16
- No 2ry sexual characters by 14
- No menarche for 5 years after completed thelarche

❖ **ETIOLOGY:**

- Constitutional, severe exercise, malnutrition.
- **Hypergonadotrophic** → ovarian failure (CTINM)
- **Hypogonadotrophic** → hypothalamic – pituitary failure (CTINM)
- **Normogonadotrophic** → end-organ-insensitivity (Mullerian agenesis, TFS, imperforate hymen)

❖ **INVESTIGATION:**

- **LH, FSH to differentiate the 3 types**
- **Hypergonadotrophic** (FSH > 30 mIU/ml) ....karyotyping
- **Hypogonadotrophic** (FSH < 10mIU/ml).....CT skull
- **Normogonadotrophic** ....ultrasound pelvis

❖ **TREATMENT:** according to the cause

Menopause

Definition مهم جدا

◈ **IT IS:**

- The **point of time**© at which there is permanent cessation of menstruation due to exhaustion of follicles.
- A ***retrograde diagnosis***® when menstruation had ceased for 1 year in any female > 40 y (mean age 51. 4/12 in USA)

◈ **IT OCCURS:**

- **Usually gradually** with decrease length of cycles

Or

- **Irregular menstruation** either
  - Hypomenorrhea or
  - Dysfunctional uterine bleeding (*threshold bleeding* كان اسمه)

Or

- **Rarely it stops suddenly** <10%



"Menopause is easy - after you stop laying eggs they eat you. '

"The Poor girl is out of eggs. 'Henopause."

Menopause & Definitions..

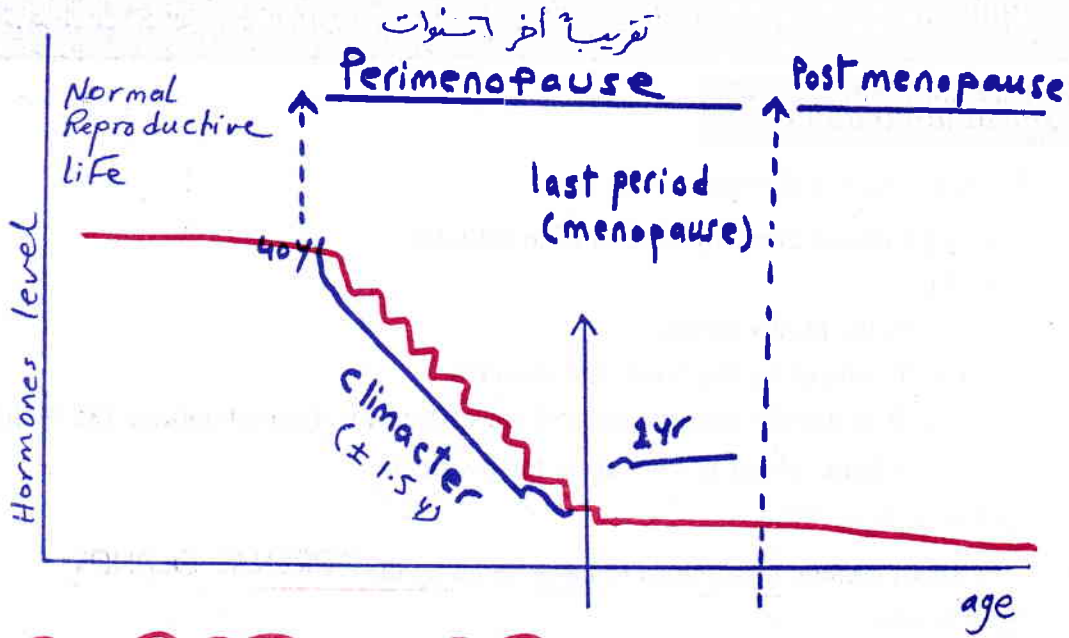

How Henopause Starts

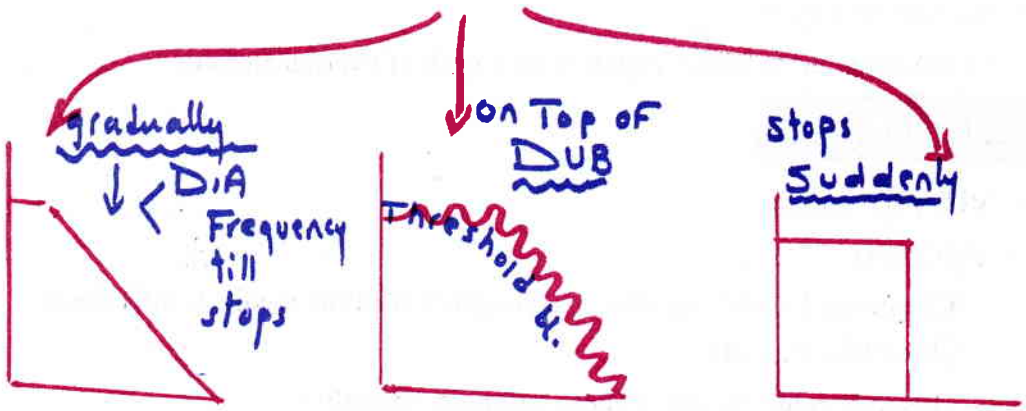

Other definition : تعريفات مهمة جدا

- Climacteric: the period during which the ovarian function decrease gradually till end in menopause (45-52 years).
- Perimeopause: period of life around menopause (before &1year after)
- Menopause: Period of time after 1 year after menopause
- Artificial menopause: due to surgery, drugs, radiation.

Physiology of menopause حاجات بتحصل طبيعية ولو زادت تبقى مشكلة

Hormonal changes :

Decrease estrogen

- ↓ E2 due to exhaustion of ovarian follicles
- E1
  - Is the MAIN form®
  - Produced by fat, liver, and muscles.
  - It is mainly from peripheral conversion of Androstendione (85 % from adrenal gland & 15 % from the ovaries).

Progesterone

- Small amount continuous to be secreted by the ADRENAL GLANDS.

Androgen

- Relative increase in testosterone with decrease estrogen → slight virilization seen in older female.
- It is produced by adrenal 75% & ovary 25%

Gonadotrophin

- Increased due to absent negative feed back of ovarian steroids

Local changes :

- VULVA: atrophy
- VAGINA:
  - Discharge (senile vaginitis, ↓ glycogen→ alkaline media & infections)
  - Pruritis vulvae
  - Dyspareunia (vaginal dryness, atrophic, smooth)
- UTERUS: atrophy of all layers (ATROPHIC ENDOMETRITIS is the COMMONEST CAUSE of postmenopausal bleeding)

Hormonal Changes:-

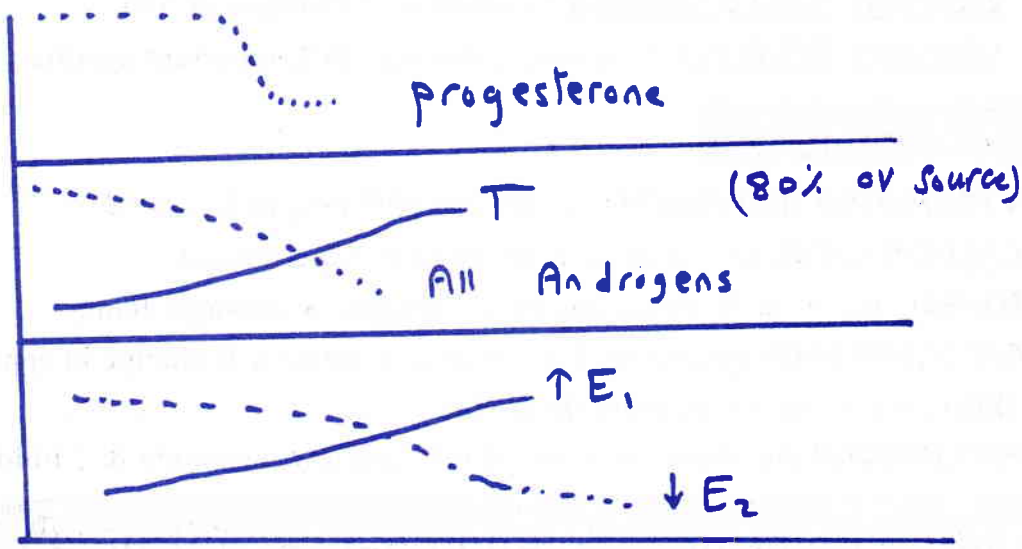

Local changes:-

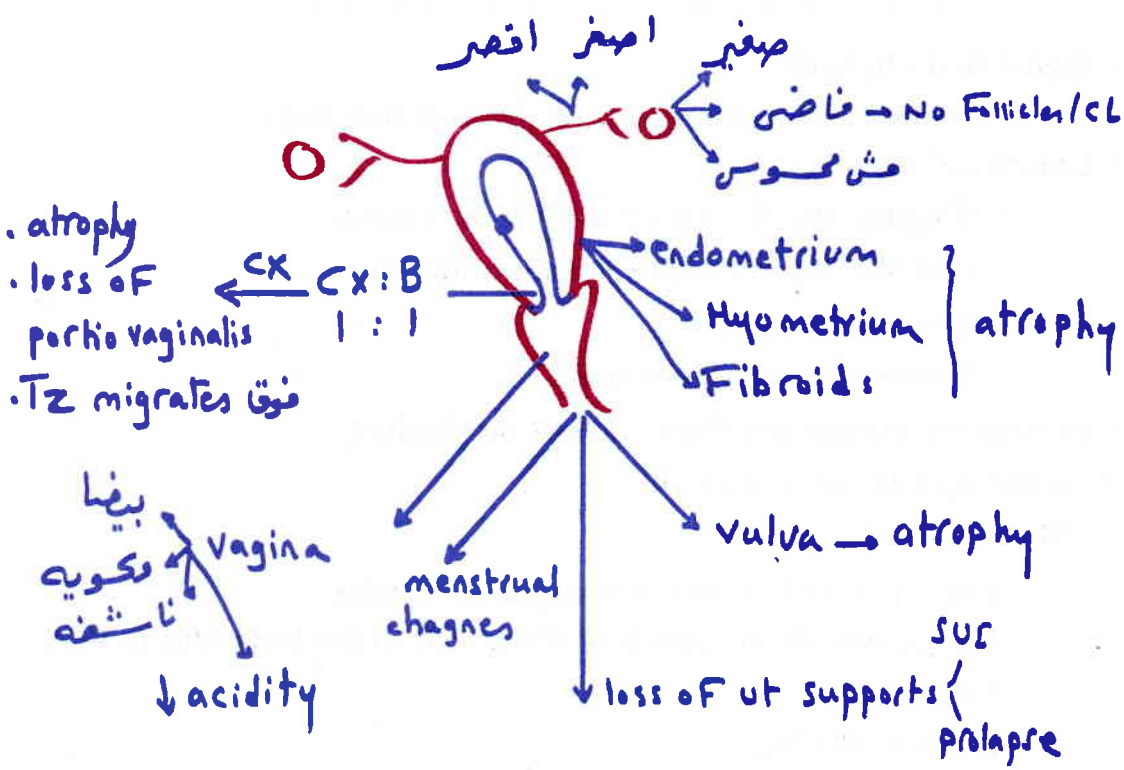

- **CERVIX :** atrophy of portiovaginalis (the vagina is flush with the cervix)
- **endopelvic fascia & ligaments :** weakness → Prolapse & SUI
- **URINARY SYSTEM :** Frequency, urgency, SUI, recurrent cystitis

General changes

- **VASOMOTOR INSTABILITY**: hot flushes (flashes) in 50 – 85%
- **CARDIOVASCULAR:** coronary heart disease, hypertension
- **BONES:** osteoporosis, rheumatic pain, backache & dowager hump
- **GIT SYMPTOMS:** dyspepsia, flatulence, constipation & change in appetite
- **SKIN:** mild hirsutism in upper lip & chin
- **PSYCHOLOGICAL:** depression, irritability, anxiety, insomnia & ↓ libido.

Clinical picture : "Menopausal syndrome"

- **It Occurs:**
  - Mild or absent in 70%
  - Moderate in 20%
  - Severe in 10%.
- **They are annoying symptoms of decrease estrogen**
  - Menstrual changes
    - Gradual decrease in amount & duration then stops.
  - Genito-urinary
    - **Vagina**: atrophy, pale smooth & dry vagina
    - **Cervix**: loss of Portio-vaginalis of the Cx,
    - **Uterus**: prolapsed
    - **Urinary system**: dysuria & SUI.
  - vasomotor instability (hot flushes or flashes)
    - **cause**: hypothalamic instability
    - **clinical picture**:
      - Present in 50-85% of postmenopausal females.
      - Intense warmth in upper half of the body of the body (due to VD)
      - Palpitations
      - profuse sweating
      - Then cold shiver (due to VC)

General changes:-

قلب ↓ IHD

مخ ← يأس، صهد

وعظم ↓ osteoporosis

وجلد ↓ تكرمش

وامعاء ↓ ملهاش نفس وانتفاخات

Clinical picture = (Menopausal syndrome)

- بتحصل في البيض مش في اليابانيات
- Absent in 70%
- Moderate in 20%
- severe in 10%

الأساسيه

قلب ومخ وعظم و genitals

المشاكل القاتله

- IHD
- osteoporosis
- Breast Cancer

- **Duration:**
  - It takes few seconds to few minutes
  - More at night
  - Disappear within 2 yrs with /without ttt ,
  - But may persist in 25% for another 5 yrs
- **Neurological**
  - Depression, fatigue, nervousness, irritability, lack of concentration.
- **Cardiovascular**
  - ↑ Liabilities to *ischemic heart disease* (↓ HDL, ↑ LDL).
- **Breast atrophy**

- **Osteoporosis** سؤال نظري لوحدها
  - **Definition** حفظ صم:
    - Decrease bone MASS
    - with MICROARCHITECTURAL changes of bone
    - That leads to ↑ bone fragility زي الطباشير
  - **Cause:**
    - Due to increase OSTEOCLASTIC activity
    - Rate of loss is 2-3%/y in postmenopause.
  - **Site:** distal radius, lumbar vertebrae, neck of femur.
  - **Risk factors:** white race- slim body- smoking- alcoholism- sedentary life- family history-premature ovarian failure- drugs.

Diagnosis of menopause

- **History & examination.**
- **Investigations**
  - **Hormonal:**
    - **↑FSH > 40 IU/l (most important)**
    - **↓ E2 <20 pg/ml, ↓P, ↑LH**, relative ↑Androgen & Lipid profile
  - **Vaginal cytology:** ↑Parabasal, ↓ superficial cells = cornification index
  - **Radiology:**
    - **DEXA** (*dual energy x ray absorptiometry*) most accurate.
    - **US** beam attenuation measures bone mass not bone mineral density.
    - **X-ray** late after 40% of bone mineral are lost
    - **U/S:** endometrial thickness (>5 mm → fractional curettage)
- **For CVS:** LDL, HDL, cholesterol, triglycerides



"No batteries needed, but you have to be menopausal to make them work."

Carol found her own way of coping with the hot flushes

Treatment of menopause

A-General

1- Reassurance: menopause is a normal midlife event
2- Improve life style: avoid factors which can precipitate hot flushes as hot weather, nervousness, excessive coffee
3- Improve diet: decrease fat, increase Ca (1000 mg daily)
4- Exercise: improves osteoprosis
5- Sedatives: tranquilizer for nervousness & depression

B- hormone replacement therapy

Indications

1- Symptoms and signs of menopause. & premature menopause.
2- Prophylaxis and treatment of osteoporosis & Genito-urinary atrophy.

Contraindications:-

★ Absolute	★ Relative
✓ Recent Stroke	✓ Migraine
✓ Recent Myocardial Infarction	✓ Hypertension
✓ Vascular Thrombosis	✓ Thrombophlebitis
✓ Acute Liver Disease	✓ Gall Bladder Disease
✓ Unexplained Vaginal Bleeding	✓ Active Endometriosis

Controlled HTN or DM are not contraindications of HRT

THE WHI (USA) + 1 MILLION STUDY (UK) STUDIES RESULTS

HRT use > 5 years:

Definite ↑ of endometrial cancer, venous thromboembolism, CVD

Probable ↑ **in risk** of breast cancer (related to length of use)

Number needed to harm 1250 (عارف دي معناها ايه؟؟؟؟)

No proven effect on quality of life, dementia, depression, sleep, libido

Non hormonal drugs are better used than HRT for control of symptoms

Complication:-

★ ↑Breast & endometrial carcinoma.
★ ↑Hepatic adenoma & Gall bladder disease.
★ Hypertension.
★ Nausea, vomiting, wt gain

"I SHOT MY AGE ON THAT HOLE!"

+ improve Life

*D

- **Mechanism of action :**
  - **Protection against osteoporosis:**
    - Decrease activity of osteoclasts (inhibit PTH).
    - Increase Ca through
      - ↑GIT absorption.
      - ↓renal loss of Ca
      - ↑ vit D activation in the kidney
      - ↑Calcitonin
  - **Protection against cardio vascular diseases:**
    - ↑HDL, ↓LDL
    - ↓cholesterol & ↓cholesterol deposition in the blood vessels.
    - ↑N.O synthesis (vasodilator).
    - The above is masked by ↓ATIII, ↑factor 1,7, 8,9,10
- **Either estrogen only or progesterone only or combined**
- **Routes: Conjugated equine E (Premarin®)→0.625-1.25 mg/D**
  - **Oral:** liable to extensive first pass metabolism
  - **Injection:** liable to fluctuations of level
  - **Trans-dermal:** no first pass metabolism, better for:
    - **Osteoporosis:** due to higher E_2 concentration
    - **DM:** doesn't impair glucose tolerance
    - **HTN:** doesn't ↑ liver RAS
    - **History of DVT:** oral E ↑ clotting Fs & ↓ antithrombin III
    - **GIT problems** as gastritis, malabsorption $
  - **Topical:** in atrophic vaginitis
- **Before treatment:**
  - **History & Examination** to exclude contraindication
  - **Investigations**: PAP smear, TVUS, endometrial biopsy, liver function tests, cholesterol level
- **Method:**
  - **Cyclic:**
    - Withdrawal bleeding occurs at the end of each month.
    - 0.625 CEE + 10 mg MPA for 10-14 days
  - **Continuous:**
    - Avoids withdrawal bleeding
    - Breakthrough bleeding occurs needing endometrial biopsy
    - Amenorrhea occurs after 1 year
    - 0.625 CEE + 2.5 MPA / d

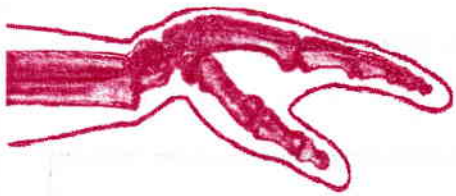

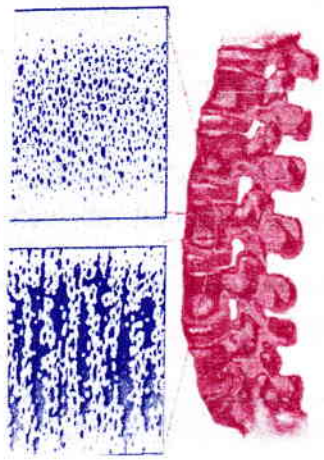

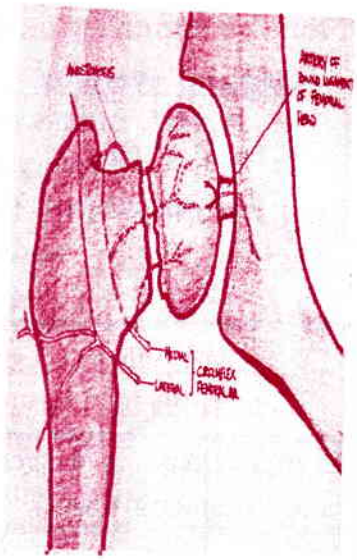

(it's The most dangerous compl of Menopause, & The most common ind of

★ *estrogen only therapy, indicated in few cases*

a- If **no uterus** following hysterectomy

b- **Intolerance** to progestin side effects.

follow up the patient by U/S, P.A.P & fractional curettage

⇨ **Duration** الكلام الجديد: According the *American College of obstetrics & gynecology:*

A. HRT is not recommended for more than 2 years

B. HRT should not be given for prevention of coronary heart disease

C. Other measures are used for treatment of postmenopausal conditions as osteoporosis & hypercholesterolemia.

C-Non-hormonal therapy:

⇨ **Vasomotor symptoms:**

- Agreal, Bromocreptin (dopamine agonists), Belladonna.
- Vit. E, Ginseng, Clonidine, α methyl dopa,
- Phytoestrogens (natural estrogen = isoflavon, present in soya bean)

⇨ **Vaginal atrophy:** water soluble vaginal lubricants.

D. SERM (selective estrogen receptor modulators)	E. Tibolon (livial®)
Exert E effects in desired organs (CVS & bone) & anti-E effects in reproductive organs (uterus & breast)	
Tamoxifen® is 1st generation while **Raloxifen®** is nearly the ideal estrogen but fails to control postmenopausal vasomotor symptoms	⌛ Steroid®, synthetic with weak estrogenic, progestogenic, androgenic effect ⌛ Dose: 2.5mg/tablet /day ⌛ Advantages (according to tissue affinity) 1-good relief of menopausal $ 2-E does not stimulate uterus or breast 3-progesterone has no need to be added 4-Androgen improves osteoporosis &libido 5-controls climacteric symptoms

Q: What are the phytoestrogens?

They are natural estrogen found in soya bean & some other vegetables they can be used for the control of menopauseal symptoms.

Q: How can you diagnose osteoporosis DXA? للأوائل فقط

- Osteoporosis is diagnosed when there is a fall in bone mineral density > 2.5 standard deviations (SD) below the mean for young adults (t score).
- The **Z Score** is the number of standard deviation away from the bone minerals density of age matched normal person.

- Risk factors:

- Diagnosis:

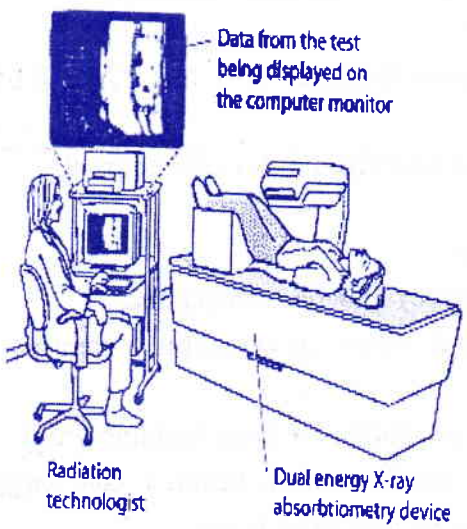

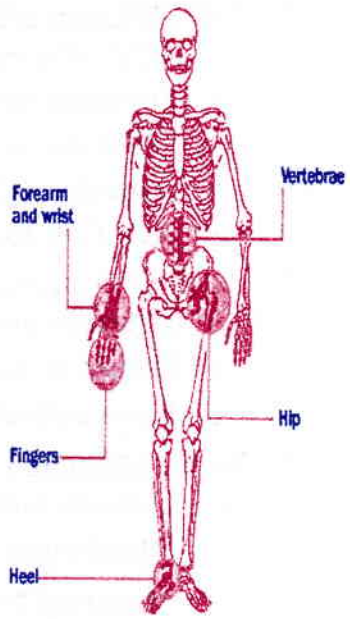

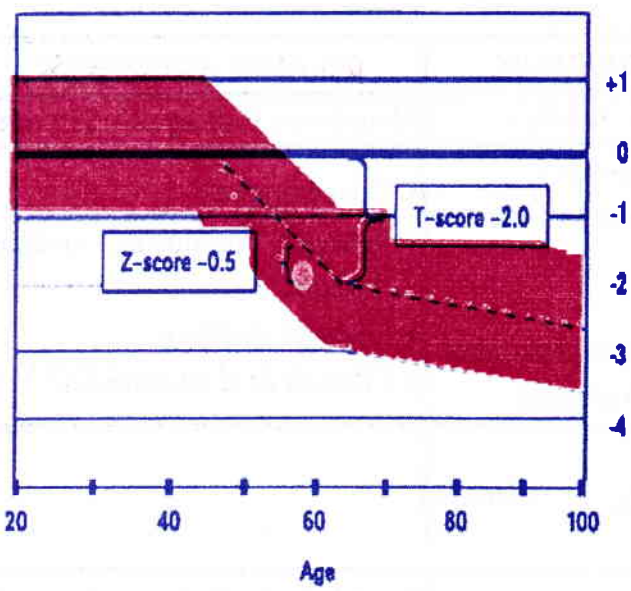

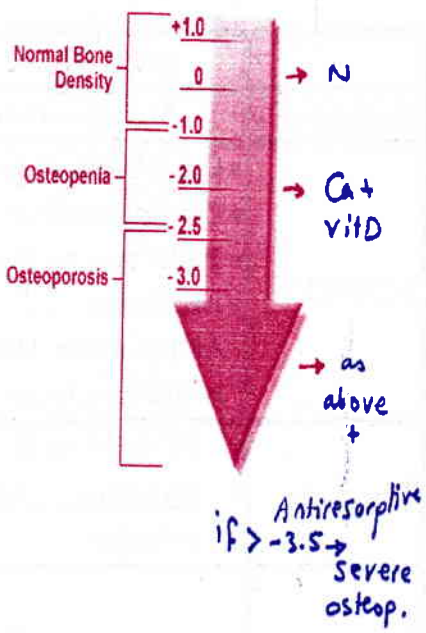

f- Treatment of osteoporosis

- **Prevention:** good nutrition, ca rich diet
- **Education:** Stop smoking, exercise
  - **Vit D:** 400 IU/D in adult & 800IU/D (elder people)
  - **Ca++:** 1g/day. This slows bone loss but doesn't ↑ bone mass
- **Anti-resorptive drugs:**
  - **Estrogen الكلام الجديد بلاش احسن**
    - ↑Ca^{++} absorption, ↓Ca^{++} excretion, ↑collagen formation
    - Decrease osteoclastic activity.
    - 0.625 mg of conjugated equine estrogen or 1 mg E2 or 0.05mg of trans-dermal.
    - ACOG & RCOG are not recommending E for osteoporosis.
  - **Calcitonin بطلوه في الخارج :**
    - Decrease osteoclastic activity.
    - Human or salmon (less antigenic) 200 IU transnasal.
    - Has a central analgesic effect & effect on vertebrae > femur.
  - **Bisphosphonates الاحسن ;**
    - Decrease osteoclastic activity (most effective bone building drug).
    - *Alendronate* (fosamax®) 20 mg/d for 2-3 years + 500 mg/d Ca^{++} →increase bone mineral density by 10% after 1year
  - **Na+ fluoride:** ↑osteoblastic activity الوحيد, but poor quality of bone.

	PREMATURE MENOPAUSE	DELAYED MENOPAUSE
Definition	Menopause before 40 years.	Menopause is delayed > 55 years
Etiology	• Constitutional. (commonest) • Chromosomal as Turner $, • Infections: mumps • Irradiation. Autoimmune: Hashimoto thyroiditis is common in 30-50% of cases	• Constitutional. • Estrogen producing ovarian tumors. • Diabetes mellitus. • Fibroids & endometriosis.
Diagnosis	✓ FSH>40 m IU/ml ✓ **Ovarian biopsy:** →atretic follicles	
Treatment	HRT	↑ **endometrial hyperplasia & carcinoma** so manage as **postmenopausal bleeding**

Anti-resorptive Drugs

EVISTA®
raloxifene HCl

other Common symptoms of menopause	Anatomical alteration of the genital tract
• Senile vulvo-vaginitis • atrophy of lower genital tract → ممكن تؤدي الى post menopausal bleeding • vulval dystrophies • Tumors	• post menopausal changes الكلام اللي فات • with coitus:- fossa navicularis اختفاء ال hymen. تقطيع • with vaginal delivery:- - Hymen ...→ Carunculae Myrtiformis - slit cx - scars in perineum & Fourchette - gapped introitus.

Abnormal uterine bleeding اهم درس فى المنهج

Normal menstrual cycle is characterized by being:

1. Regular "every 3 - 5 wks for 3 - 5 days (< 7 days)"
2. Average amount of blood ± 80 ml per day (25-50ml) = 2 pads/ day

⇨ ABNORMAL FORMS OF UTERINE BLEEDING

♦ Cyclic bleeding Related to menstrual period	♦ Acyclic bleeding Not related to menstrual Period
1. Menorrhagia: **Excessive** menstrual flow in amount &/or in duration with **normal** cycle duration.	**1. Metrorrhagia (Metrotaxis):** **Acyclic** bleeding due to local cause.
2. Poly-menorrhea: **Normal** flow but **shortened** cycle < 21 d.	**2. Meno-metrorrhagia:** **Menorrhagia** +**intermenstrual bleeding**
3. Poly-menorrhagia: **Too frequent** menstruation with **excessive amount** &/or **duration** of menses"**i.e.= menorrhagia** +**polymenorrhea**"	

⇨ ETIOLOGY:

1. General causes:

- **Endocrine diseases:** Hypo- or Hyper-thyoidism, DM (vasculopathy)
- **Psychological disturbance:** (Unsatisfied sexual urge)
- **Cardio-vascular diseases:** (C.H.F - Hypertension)
- **Liver diseases:** impaired estrogen metabolism الاهم and ↓ clotting factors.
- **Renal diseases:** (Renal failure → toxic capillaritis and thromb-asthenia).
- **Blood diseases:** (Coagulation defects as Von Willebrand deficiency, Leukemia, or Thrombocyto-penia).

2. Local causes:

- **Congenital uterine disorders:** (Bicornuate uterus or septate uterus).
- **Traumatic disorders:** Hymenal tears or F.B. in vagina.
- **Inflammatory disorders:** vaginitis, or cervicitis, or endometritis
- **Neoplastic disorders:** (Fibroid, or CA cervix, vulva, vagina or uterus).
- **Miscellaneous:** chronic constipation or displacement & endometriosis.

Pattern of menstrual cycle:-

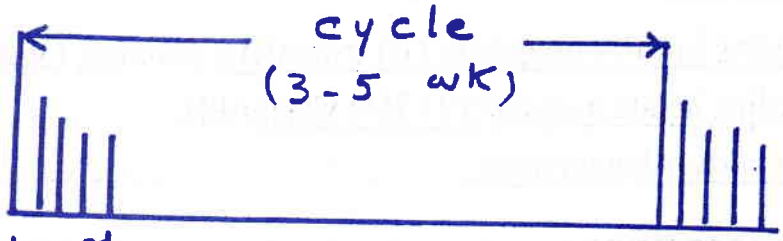

* Duration :- 3-5 days عدد أيام نزول الدم
* Amount :- 30-50 mL كمية الدم

Forms of abnormal genital bleeding:-

Regular



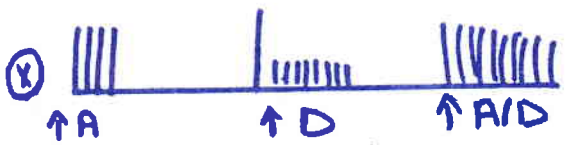

Menorrhagia

polymenorrhea: ↓ cycle < 8 wk

polymenorrhagia

Irregular

Metrorrhagia

Menometrorrhagia كوكتيل

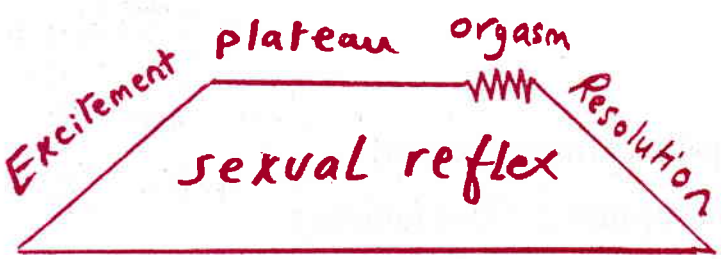

3. Conception:

- **Bleeding in early pregnancy (1st trimester):** Abortion, EP, or vesicular mole.
- **Bleeding in late pregnancy (> 28th wks):** APH.
- **Post partum hemorrhage.**

4. Contraception: (Irregular intake of oral contraceptive pills or IUD)

5. Drug intake: (Oral anticoagulant or Aspirin, or Psychotropic drugs)

6. Dysfunctional uterine bleeding (D.U.B)

Dysfunctional uterine bleeding (D.U.B) مهم جدا

DEFINITION غايه في الاهميه:

- Abnormal uterine bleeding
  - Not due to general or local causes

But

  - Due to abnormalities in
    - The ENDOCRINE GLANDS controlling the menstruation
      "Hypothalamo - pituitary - ovarian axis"

Or

    - Local ENDOMETRIAL defect (imbalance between VD PG & VC PG)

INCIDENCE:

- 10-20% ®
- More
  - Around **puberty** (immature axis)
  - Before **menopause** (↓ NO of follicles)
- 75% after 30 yrs



"I've *got* it! — chocolate-covered birth control pills!"

⇨ **TYPES** قمه التركيز:

1- Ovular DUB 80 % ⟶ menorrhagla

"Self-limiting disorders need no treatment but progesterone maybe needed"

A. Functional polymenorrhea

- **Too frequent** cycles due to **too short** follicular phase of menstrual cycles

B. Mid - cycle spotting:

- **Slight ↓ of estrogen** just pre-ovulatory

C. Functional Menorrhagia

- due to ↑ **VD PG**

D. Irregular ripening of endometrium

- **Premature shedding** of Endometrium
- **Premenstrual spotting®** due to corpus luteum insufficiency → decrease progesterone production "**weak secretory phase**"

E. Irregular shedding of endometrium

- **Delayed shedding** of endometrium
- **Postmenstrual spotting®** due to prolonged progesterone production due to slow incomplete degeneration of corpus luteum

F. Halban disease (persistent corpus luteum):

- **Cause: Unknown** (abnormal ovarian PG which is needed for luteolysis).
- **Clinical picture:**
  - **Missed** period.
  - Then the corpus luteum degenerate causing
    - abdominal **pain**
    - menstrual **bleeding**
- **DD: Ectopic pregnancy** (*differentiated by +ve pregnancy test*)

Treatment for all previous types:

- **If bleeding + no need of pregnancy**
  - Progesterone (as primolut or provera 10 mg for 10 or 20 days)
  - COC (inhibits the axis & start artificial cycles)
- **If bleeding + infertility**
  - HCG
  - Clomiphene + HCG
  - ART if induction is failed

A. Threshold bleeding

- **Timing:**
  - At extremes of menstrual cycle
- **Cause:**
  - Ovary produces small amount of Estrogen reaching threshold level.
  - The threshold level (50-60 pg/ml) is enough to **stimulate** proliferation but not to **maintain** the endometrium
- **Amount of blood:**
  - Not profuse due to fluctuation of E around 50 – 60 pg/ml الرقم مهم
- **Treatment**
  - **D & C** is required in perimenopause
  - **COC:** repeat for 3 – 6 cycles وبعد كده حتنتظم لوحدها
  - **If infertility in young age**: induction of ovulation

B. Metropathia hemorrhagica "Schroeder's disease"

- **Definition:**
  - it is **acyclic** bleeding
  - **Occurring** from proliferative hyperplastic endometrium
  - **Resulting** from unopposed E (anovulation)
  - It may be **preceded** by short periods of amenorrhea
- **Etiology:** Unknown
- **Pathogenesis:**
  - Continuous growth of the follicles after failure of ovulation.
  - They form functional cysts which secrete unopposed E acting on the uterus.

Pathology of metropathia hemorrhagica	
Uterus	**Ovaries**
⊙ *SYMMETRICALLY* enlarged = (myohypertrophy) ⊙ Endometrium: - Thickened - Polypoidal - Endometrial hyperplasia	⊙ Enlarged ⊙ Functional cysts: - Multiple - variable sized (<6cm) - lined by granulosa cells ⊙ Absence of corpus luteum

Diagnosis of metropathia hemorrhagica	
Symptoms	**Sings**
Short period of amenorrhea: Due to prolonged E effect on endometrium **Followed by bleeding:** ★ May be **life threatening** ★ Is **painless prolonged** ★ **Breakthrough** bleeding ★ **Due to:** 1. Relatively insufficient estrogen to support the thick endometrium 2. ↑ E → ↓ FSH support of follicle	**Generally:** ★ Anemia ★ Shock **Locally:** ★ Vagina shows fresh bleeding ★ Soft and closed cervix ★ Bulky and soft uterus

D.D.

- Abortion - Ectopic pregnancy - Gestational trophoblastic tumors
- Irregular uterine bleeding (tumors, fibroids)

Investigations

- Diagnosis is by **exclusion**
- **Exclude general cause as:**
  - Platelet count & function
  - **Clotting profile**: PT, PTT.
  - **Function test**: liver & renal functions
- **To exclude local cause**: U/S and Serum HCG, fractional curettage
- **Tests of ovulation:** to differentiate if ovular or anovular
- **If ovular**: do tests of LPD
- **If anovular**: do test of PCO

Treatment of dysfunctional uterine bleeding التقسيمه مهمه جدا:

- **General lines of treatment:**
  - **Bed rest.**
  - **Iron supplement. & Vitamins.**
  - **Reduction of weight.**
  - **Blood transfusion** according to amount of blood loss.

Non – hormonal treatment:

- **Anti-fibrinolytic agents:**
  - Epsilon Amino-caproic Acid (EACA)
  - Tranexamic acid (Cyclokapron®): 1g tab. 4 times/d, ↓ bleeding 50%.
- **Haemostatic agents:** "To ↑ platelet aggregation and to ↓ capillary fragility"
  - Diosmin (Daflon ®)
  - Ethamsylate (Dicynone ®)
- **Thomboxane:** VC and platelet aggregation
- **PG synthetase inhibitors:** reduce vasodilatation induced by PGE2

Hormonal treatment: →

- **Progesterone:**
  - **Forms:**
    - (Norethisterone "Primolut®").
    - (Medroxy-progesterone acetate "Provera®") to oppose E
    - Levonorgestrel containing IUCD (Mirena)
  - **Start:**
    - **5th d** of the cycle for **20 days** Or
    - **15th day** of the cycle for **10 days**
  - **Doses:** 2-3 tabs. / d
- **Combined OCPs** (Cycloprogynova, Gynera®, Marvelone® & Cilest®)
  - 2-4 tab. / d till bleeding stops; then 1 tab. / d for 20 days
- **Estrogen:**
  - Indications:
    - Severe cases
    - Threshold bleeding
  - Dose: oral conjugated estrogen for 20 d;
    combined (with P) in the last days to promote normal period.
- **Androgen:** "Danazol - Methyl testosterone - Gestrinone"
- **GnRH analogue:** "Nasal spray - IMI - SC" every 3 - 4 w >> **amenorrhea"**

Surgery:

- **Curettage of the uterine cavity**
  - **For diagnosis and treatment**
  - **Effect:**
    - 50% cured
    - 25% improved
    - 25% no effect.

- **Endometrial ablation or resection:**
  - **Using:** LASER - Electrocautery -Thermal destructive techniques
  - **Disadvantage:**
    - Risk of endometrial proliferation
    - endometrial cancer
  - **Effect:**
    - Amenorrhea in 50% of cases
    - Reduces bleeding in 90% of cases.
- **Hysterectomy**
  - **After failure of the previous lines of treatment**
  - In female > 40ys with adequate number of children
  - Associated pathology is found

if there is infertility→ induction of ovulation

In acute severe bleeding:

1. Hospitalization & resuscitation (IV fluids + blood transfusion)
2. High doses of:
   a) E → Cojugated equine estrogen 25 mg IV/4 h
   b) COC 1x4 till bleeding stops the one tab/ day for 20 days
3. Emergency D&C

Types of abnormal genital bleeding

Menorrahgia	Metrorrhagia	Polymenorrhea
1. General causes **2. Local causes** **3. Dysfunctional menorrhagia**	**1. Local lesions (commonest causes)** **2. Conception.** **3. Contraception** **4. Anovular DUB.**	**1-Dysfunctional polymenorrhea:** Due to **short follicular** or **short luteal phase.** **2-local (ovarian congestion).**

CAUSES OF MENOMETRORRHAGIA

- Any cause of menorrhagia may develop into menometrorrhagia

CAUSES OF OLIGO OR HYPOMENORRHEA OR OLIGOHYPOMENORRHEA

- Same causes of amenorrhea except cryptomenorrhea or absent uterus or ovary

Menorrhagia	Metrorrhagia	Polymenorrhea
T		
L		
G	CC	

ABNORMAL BLEEDING ACCORDING TO AGE

1. Birth Crisis

- ★ Mild spotting in newborn female 3-10 days post-natal due to excretion of maternal E passed to the infant through the placenta.

2. Vaginal bleeding and secretions during childhood:

- ★ **Trauma: F.B. in vagina** "famous cause", removed under anesthesia.
- ★ **Inflammatory: Vulvo-vaginitis & Vaginal adenosis.**
- ★ **Neoplastic: Sarcoma botryoides** "grape-like sarcoma", germ cell tumors
- ★ **Miscellaneous: Precocious puberty.**

3. Bleeding during childbearing period:

- ★ **Post-pubertal period:** DUB or coagulopathy.
- ★ **20-40 years:** all causes but local causes or complications of pregnancy& contraception are the most common.

4. Contact bleeding "bleeding on touch of cervix or vagina":

- **Types:**
  - ★ Post-coital bleeding
  - ★ Vaginal examination or douches
- **Causes:**
  - ★ **Local causes of the cervix or vagina** (any case is considered cancer cervix till proved otherwise)
  - ★ **Uterine polyp** passing through the cervix

5. Peripubertal & peri-menopausal bleeding: all causes but mostly DUB

6. Post-menopausal bleeding is due to:

- ★ **Malignancy:** 10-20%®☺ especially "***endometrial carcinoma***";
- ★ **Atrophic changes** of lower genital tract (most common)
- ★ **Exogenous hormones** as estrogen withdrawal being used in HRT
- ★ **General (rare)**
- ★ **Complications of prolapse** as trophic ulcers or retained pessary
- ★ **Non gynecological causes:**
  - ✌ Bleeding / urethra
  - ✌ Bleeding / rectum

Withdrawal bleeding	E + P → Normal menstruation, OCPS
Breakthrough bleeding	E>> metropathia hemorrhagica P>> POPS, injectables or implants

Abnormal bleeding according to age group :-

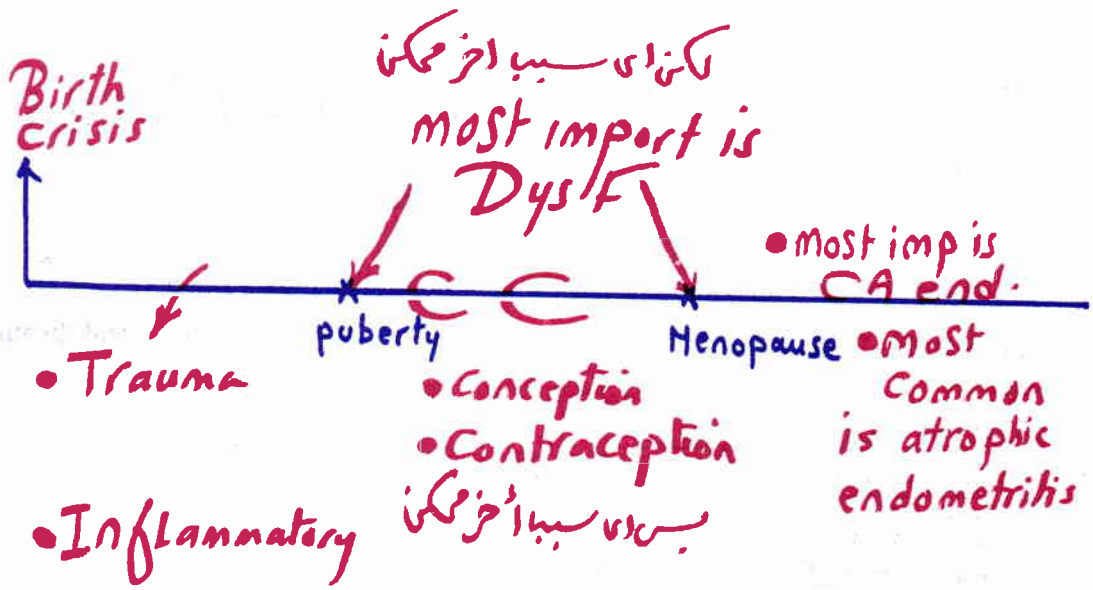

- Inflammatory
- Neoplastic { Germ cell Tr / Sarcoma botryoides
- Miscellaneous : precocious puberty

Types of bleeding acc. to hormonal level.



DISCUSS POST MENOPAUSAL BLEEDING

DEFINITION

- Bleeding from genital tract occurring after one year after menopause.
- *It is considered cancer endometrium till proved otherwise*

ETIOLOGY

1. **Local causes "in the genital tract"**
   - **Neoplastic (10-20%):** genital CA esp. endometrium & feminizing ovarian trs.
   - **Inflammatory:**
     - Senile "atrophic" vaginitis or senile endometritis
     - It is the commonest cause (1/3 of cases)
   - **Traumatic:** Retained pessary or trophic ulcers of the genital prolapse.
2. **Hormone replacement therapy:** This may lead to breakthrough bleeding
3. **General causes (rare):**
   - **Coagulation defects** e.g. thrombocytopenia & liver cirrhosis.
   - **CVS causes** as hypertension or congestive heart failure.
   - **Early cases of** hypothyroidism or thyrotoxicosis.
4. **Urethral or rectal causes:** Urethral caruncle or piles or malignancy.

DIAGNOSIS

HISTORY

Personal History

Parity:
- Endometrial cancer & epithelial ovarian trs are commoner in low parity
- Cancer cervix is common in high parity.

Race:
- Endomertrial carcinoma in white race
- Cervical carcinoma in black races

HPI:
- Associated symptoms e.g. pain or purulent discharge.
- Masses protruding from the vulva i.e. genital prolapse.

Contraceptive H.: Hormonal therapy e.g. estrogen.

Past H.: General disease e.g. hypertension or coagulation disorder

EXAMINATION:

General examination:
- The general condition for pallor, cachexia or hypertension.
- Signs of metastasis in the chest e.g. pleural effusion & spine.

Causes of post menopausal bleeding :-

- **Abdominal examination:** to detect;
  - Ovarian mass or hemato-pyometra if cervical or uterine cancer.
  - Hydronephrosis in cases of cervical cancer.
  - Liver metastases.
- **Pelvic examination:**
  - Inspection of the vulva to detect masses or ulcers of the vulva.
  - Palpation to detect vaginal or cervical lesions.
- **Bimanual ex. for**
  - The uterus: size, fixation & tenderness
  - Ovarian masses.
- **Speculum examination** to detect cervical lesions
- **P/R** to detect spread to the rectum or parametrium

INVESTIGATIONS:

- **Diagnosis:**
  - **Radiological:**
    - **U/S** to exclude lesions of the uterus or ovary.
    - **Hysteroscopy** to exclude organic lesion of the uterus.
  - **Biopsy**
    - From any lesions.
    - **Fractional curettage** is the most important.
- **Investigations to detect spread** e.g. chest X-ray, liver scan, abd CT or MRI.
- **Preoperative investigations** e.g. blood picture, coagulation tests & EGG.
- **Investigations for other causes**

MANAGEMENT

- Treatment of the cause (DUB: P & if failed hysterectomy or endometrial ablation)
- If bleeding is recurrent & no cause is found → pan hysterectomy.
- Treatment of premalignant & malignant conditions

HOW TO APPROACH A CASE OF ABNORMAL UTERINE BLEEDING

HISTORY:

- **Age:** If the patient's age is above 40, malignancy should be excluded.
- **Marital status:** Complications of pregnancy occur in the child bearing period.
- **Obst.history:** In postabortive/2ry PPH, choriocarcinoma should be excluded.
- **HPI:**
  - Associated symptoms e.g.: pain
  - General disease e.g. hypertension or coagulation disorder
- **Contraceptive History:** Hormonal therapy e.g.: hormonal contraception.

EXAMINATION

- **General examination:**
  - Signs of anemia e.g.: pallor
  - General disease e.g.: hypertension or hypothyroidism
- **Abd. examination:** masses as pregnancy, fibroid or ovarian tumors
- **Pelvic examination:**
  - To detect a local cause e.g. fibroid or polyp
  - To exclude urinary and rectal causes e.g. piles

INVESTIGATIONS

- **Investigations for general causes:**
  - Blood picture, Bleeding & clotting time
  - Thyroid hormones & Liver functions
- **Investigations for local causes:**
  - **Radiological**:
    - **U/S:** to detect fibroid or ovarian masses
    - **HSG:** to detect submucous fibroid or polyp.
  - **Endoscopy:**
    - **Hysteroscopy:** to detect submucous fibroid or polyp.
    - **Laparoscopy:** to visualize the pelvic organs.
  - **Biopsy:**
    - Fractional curettage to exclude endometrial or cervical carcinoma
    - Ectocervical biopsy for suspected cancer on the Ectocervix

TREATMENT

- **Correction of anemia** i.e. Iron therapy
- **Treatment of the cause** e.g. Treatment of fibroid
- **Medical Treatment: -** to decrease the amount of blood loss:
  - Anti-PG's
  - Anti-fibrinolytic agents e.g.: tranexemic acid & Ethamsylate
- **Hormonal Treatment** for DUB
- **In DUB, hysterectomy is done for** pts above 40 years with adequate number of children if hormonal treatment and curettage failed

ANOVULATION

- **DEFINITION:** Interruption of ovulation

N.B. WHO classification of ovarian insufficiency	
Group I	Hypothalamic pituitary failure
Group II	Hypothalamic pituitary dysfunction
Group III	Ovarian failure

- **ETIOLOGY** مهمه جدا

  - **Physiological**
    1. 1st few cycles or around menopause
    2. Before puberty & after menopause
    3. Pregnancy & lactation
  - **Pathological**
    - **Hypothalamic- pituitary - ovarian** causes: →C-T-I-N-M
    - **General:** anemia, physical exercise, chronic disease, drugs, obesity
    - **Idiopathic**
    - **Thyroid** dysfunction
    - **Hyper prolactinemia**
    - **Adrenal:**
      - Adult onset adrenal hyperplasia
      - Cushing's $

- **CLINICAL PICTURE**

  - **Manifestations of the cause**
    1. **PCO** → obesity, hirsutism, infertility & anovulation
    2. **Hyperprolactinemia** → galactorrhea
    3. **Hyperandrogenism** → hirsutism
    4. Other endocrinal diseases as thyroid (goiter, palpitations, tremors)
  - **Manifestations of anovulation**
    - **Menstrual changes**: oligomenorrhea - amenorrhea (commonest)
    - **Infertility**

- **INVESTIGATION**

  - **To diagnose the cause**
    - **FSH level:**
      - >40 m IU/ml → ovarian failure

- ★ < 5 m IU/ ml → hypopituitarism
- ★ **Normal:** <20 m IU/ml

- **LH/FSH:** if > 3 → PCO
- **Tumors:**
  - ★ Testosterone → ovarian tumor
  - ★ DHEA → adrenal tumor
- **Thyroid function test**
- **17α OH progesterone** n adult onset adrenal hyperplasia

♣ **To document anovulation**

- **BBT** (mono-phasic pattern)
- **Premenstrual Endometrial Biopsy** →(no secretory changes)
- **Cervix** (no pre-ovulatory runny clear mucus, -ve spin, -ve fern)
- **Vaginal smear** (no intermediate cells)
- **Progesterone** < 3mg / ml
- **Absent LH surge.**
- **Folliculometry**

TREATMENT

- **Treatment Of The Cause**
- **General:** correction of malnutrition, anemia, DM
- **Medical:** induction of ovulation, bromocriptine if hyperprolactinemia
- **Surgical:** Drilling for PCO, surgery for virilizing ovarian tumor

LUTEINIZED UNRUPTUED FOLLICLES SYNDROME (L.U.F.S)

Luteinization of the Graffian Follicle but without release of ova.

EFFECTS: Regular menstruation + secretion of progesterone + infertility.

INVESTIGATIONS:

♣ **Serial U/S**

- Development of follicles which don't collapse at the expected ovulation
- No rim of fluid in the Douglas pouch.

TREATMENT:

1. Induction of ovulation.
2. Avoid anti-PG (at mid cycle): PG are needed for rupture of the follicles.
3. IVF.

Polycystic ovarian syndrome (PCOS) غاية فى الأهمية

Stein & leventhal syndrome 1935

DEFINITION:

- Chronic anovulatory condition characterized by cystic enlargement of ovaries + amenorrhea (70%) or oligomenorrhea (most common) + hirsutism (50%) + infertility (50%) + obesity, DM & hypertension.

INCIDENCE: 2-4 %.

PATHOLOGY

- Macroscopic
  - Ovular changes: POLYCYSTIC, SCLEROCYSTIC
    - Size: enlarged
    - Surface: thick cortex, pearly (ivory) white
    - Cut section:
      - Stroma: thick.
      - Follicular cysts: multiple, small (<10 mm), subcapsular, filled with fluid rich in E+ A
  - Uterine changes: symmetrical enlarged ± adenomyosis
- Microscopic
  - Ovarian: stromal hyperplasia, cysts, luteinized theca like cells
  - Uterine: endometrial hyperplasia

PATHO-PHYSIOLOGY

↑ A (by ovaries)

↑ LH & ↓ FSH ↑ E (peripheral conversion)

- *There is high LH (pituitary hypersensitivity):*
  - Stimulates androgen formation by theca cells & ovarian stroma
  - Part of this androgen is transformed to E locally & peripherally.
  - The end result is increased both androgen & estrogens
- *This will inhibit FSH release:*
  - Thus follicular development is arrested at various stages
  - Local androgens leas to follicular atresia & thick capsule → multiple cysts.

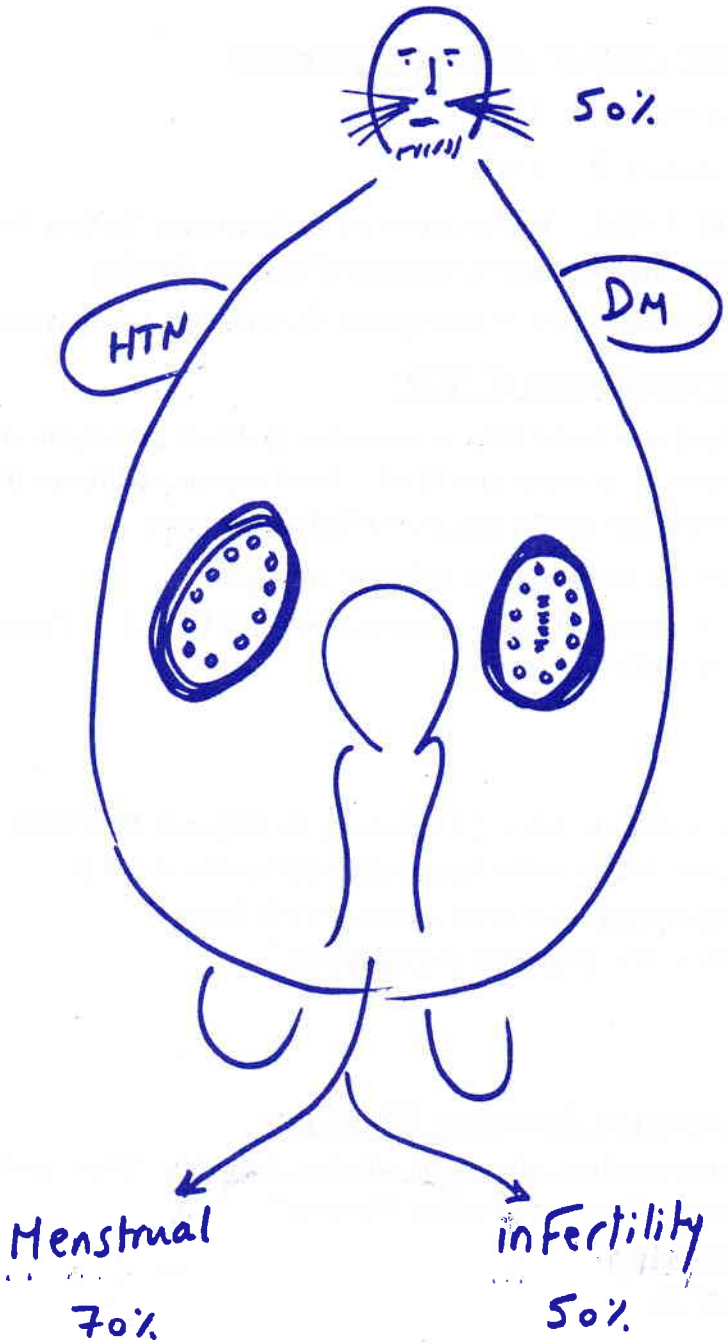

Symptoms

اهم ٣ نقط

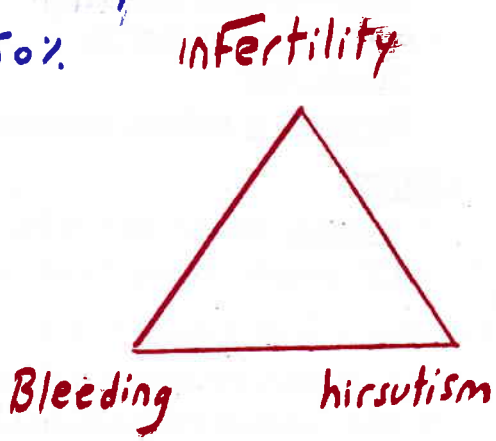

These follicles will further increase estrogen:

- +ve feed back on LH → ↑ LH
- -ve feed back on FSH → ↓ FSH
- **THIS VICIOUS CYCLE** → stimulation of endometrium leading to short periods of amenorrhea followed by prolonged irregular bleeding
- Proliferation of endometrium → hyperplasia → carcinoma + myohyperplasia

Relation of hyperinsulinemia & PCO:

- Insulin resistance was found 40% of cases due to defect in receptor or anti-insulin antibodies → increase insulin → ↑ local ovarian androgens through its receptors or through Insulin like growth factors receptors.
- Insulin like GFs are stimulatory to androgen synthesis
- Type II DM + obesity (BMI > 27kg/m2) → ↓ SHBG & ↓ Estradiol + Hypertension & CVD

CAUSES مهمه

1. **1ry central defect**
   i. Either pituitary abnormality (↑ LH release in response to GNRH)
   ii. Or hypothalamic defect with change of GnRH pulse → ↑ LH
2. **↑ adrenal & ovarian Androgen** "may be by insulin growth factor 1"
3. **1ry enzyme defect** in the ovary "aromatase enzyme defect "
4. **obesity**

CLINICAL PICTURE

Symptoms: more common between 20-30yrs

- **Amenorrhea, oligomenorrhea, abnormal uterine bleeding** "short period of amenorrhea followed by Prolonged Painless Bleeding"
- **Hirsutism, acne, seborrhea**
- **Infertility or sub-fertility**
- **Obesity 50%**
- **Recurrent or habitual abortion**

Signs

- **General**: obesity, DM, HTN, Acanthoma Nigricans, acrocordones.
- **PV**: palpable enlarged cystic ovary

COMPLICATION (LONG TERM)

- Endometrial hyperplasia → carcinoma.
- DM, Ischemic Heart Disease, HTN.
- Infertility & menstrual irregularities

Role of obesity in Pcos:-

1- ↑ synthesis of estrogen

2. Insulin Resistance

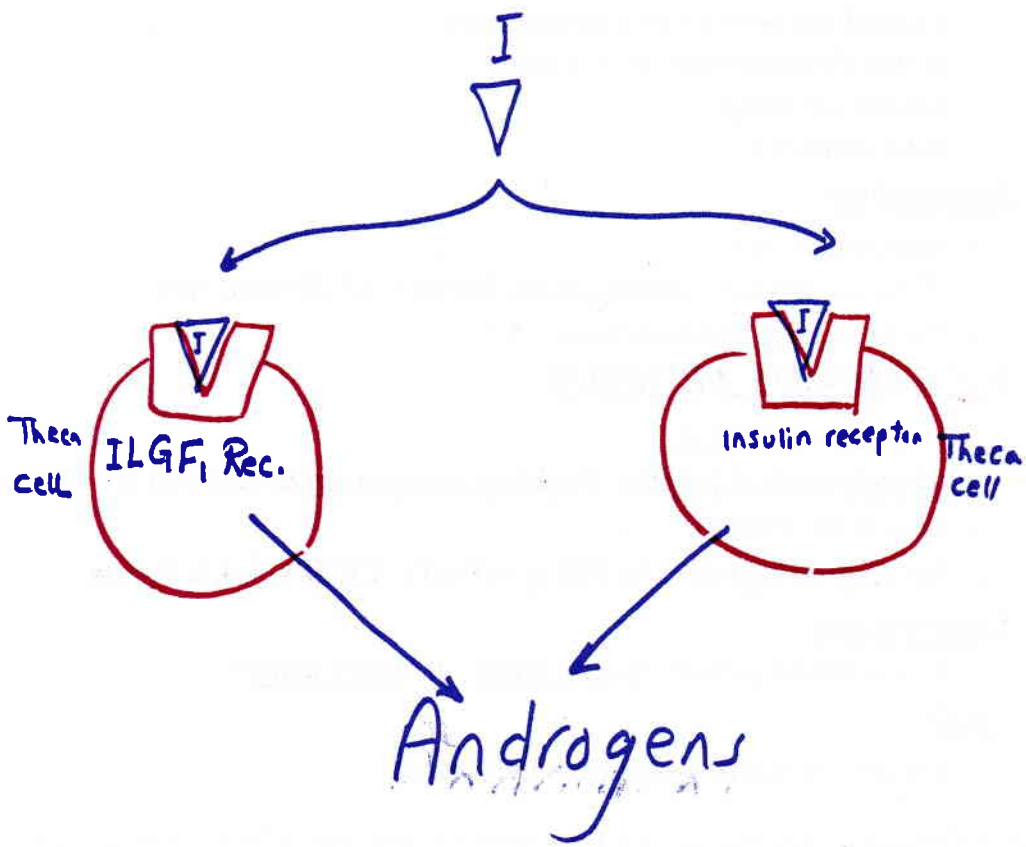

3- ↓ SHBG → ↑ Free Part of the hormones

Obesity: BMI > 27 kg/m2
morbid > 35 kg/m2

♂: apple shaped
♀: pear shaped

INVESTIGATIONS

Hormonal

- ↑ LH, ↓ FSH (LH/FSH= 3/1) → most important
- ↑ T, DHEA, Estrogens & Prolactin (<30 ng/ml)
- ↓ Progesterone, ↓ SHBG.

To document Anovulation

- **Basal body temperature** "monophasic"
- **Premenstrual endometrial biopsy** "no secretory changes"
- **Cervix** " – ve fern test"
- **Vaginal smear**→ no intermediate cells
- **Serum Progesterone** → "< 3 ng/ml"
- **Absent LH surge**
- **Folliculometry**

Metabolism

- Impaired GT test,
- "↑ fasting insulin" (normal fasting insulin < 10 -20 units/ ml)
- Serum fasting glucose/insulin < 4.5

U / S (ADAM'S CRITERIA)

- Ovarian size ≥ **10cm³**
- **>10 sub-cortical follicles** (**Necklace appearance** & each cyst is 6-10 mm)
- stromal hyperplasia

Not diagnostic present in 20% of normal♀, OCPs, ↑A & Stress.

Laparoscopy

- Characteristic picture "**pearly white**" or "**ivory white**"

D&C

- For any associated endometrial hyperplasia

TREATMENT (tailored according to the symptom لازم تفهم الهدف من العلاج)

GENERAL

- **Weight reduction** → ↓insulin resistance & ↓ hyperandrogenism
- **Stop smoking** → ↓ adrenal androgen

IF THE C/O IS INFERTILITY

- **Medical:**
  - **Clomiphene citrate:** induction of ovulation (acts as an anti-estrogen)
    - ↑GnRH & FSH → follicular development
    - **Dose: 1x2x5** from **2nd or 3rd day** of the cycle & **for 5days**
  - **HMG:** - for induction of ovulation "dose:- FSH 75 IU + LH 75 IU"

Consequence of PCOS

Short-term

1- menstrual irregularities
2- hirsutism / acne
3- infertility / obesity / Abn. lipids

long-term

1- DM
2- IHD
3- Endometrial Carcinoma.

Rotterdam definition of PCOS (2003):-

2 out of 3

1- oligo or Anovulation
2- clinical &/or Biochemical evidence of ↑A
3- PCO (with Exclusion of related disorder)

D.D. of PCOS:- PCO like.

1- adrenal gland causes of hirsutism = CAH, Tr, Cushing
2- ovarian tumor (androgenic)
3- ↑ PRL & Thyroid diseases.

- **Combined Clomiphene citrate** & **HMG**
- **Oral hypoglycemic** مهم → Metformin '500 mg/ 8h" to ↓ insulin resistance → ↓ testosterone, estrogen, LH→ spontaneous pregnancy

➢ **Surgical "in case of failure of medical Treatment"**

- **laparoscopic ovarian Drilling**
  - May be done by **electrocautery**, **laser** (better)
  - 4-8 punctures are done in each ovary for 2-4 seconds each (40-400 watt)
  - Advantages: less adhesions, bleeding than BWR, pregnancy rate 70%
- **Previously:** inverted bilateral wedge resection (BWR) لا تذكرها للعلم بالشيئ فقط
  - More adhesion & bleeding, pregnancy rate 50%
  - 1/4 or1/2 of the ovary is removed
- **If failed**: ART "assisted reproductive technique"

> **The mechanism of surgical drilling is unknown by may be:**
>
> *1-* ↓ stroma → ↓ androgen → FSH can control the remaining ovarian tissue
> 2-removal of thick tunica → allows the follicle to rupture
> 3- removal of the increased ovarian tension → correction of local factors

IF COMPLAIN IS HIRSUTISM

- **Diane 35**
  - For 21 days & stop 7 days every month
  - 35 microgram ethinyl estradiol + 2 mg cyperoterone acetate
- **COC** containing 3rd generation progestins (Gynera, Marvelon, cilest).

IF COMPLAIN IS DUB

- **Hormonal:**
  - Progesterone 10mg/d for 10 days each month, either
    - Provera (PMA) or Primolut (norethiterone)
  - COC for 21days then stop 7days & repeat for 3-6 months
- **Surgical:**
  - **D&C:**
    - Therapeutic if medical treatment is failed
    - Diagnostic to exclude endometrial hyperplasia & malignancy
  - **Hysterectomy:**
    - Atypical hyperplasia or carcinoma
    - Female > 40 yrs & completed her family

Treatment of PCOS is

Tailored according

كلام لطيف

To the symptom

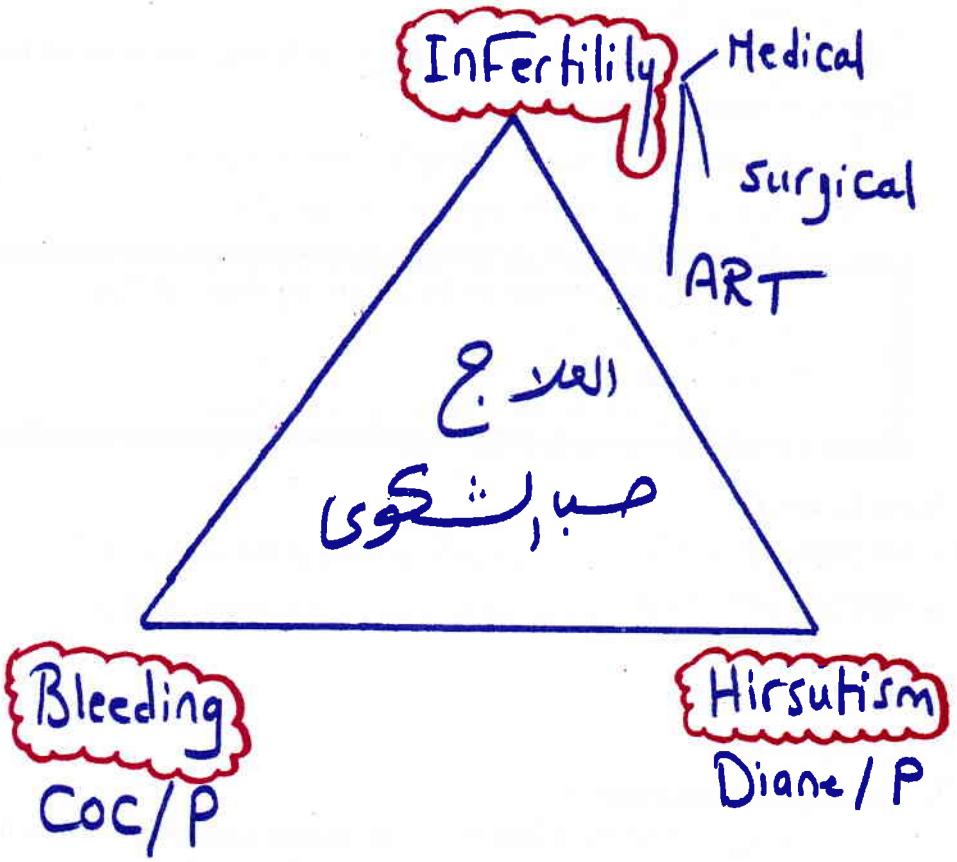

Luteal Phase Defect (L.P.D)

DEFINITION

- Group of disorders

Due to

- Decreased hormonal production by the corpus luteum.

PATHOGENESIS سؤال لوحده

1- **Weak corpus luteum:**

- ↓FSH & LH at the ovulatory surge → ↓ maturation of the Graffian follicle in the 1st half of the cycle.
  - ↓ Progesterone production by the CL → (poor secretary changes).

2- **Early degeneration of corpus luteum (luteolysis)**

- Hyperprolactinemia & Hyperandrogenemia.
- Hypothyroidism.
- Pelvic endometriosis (↑ PGF2α → **early degeneration of the CL**).

3- **Resistant endometrium**

- Endometrial resistance (↓ Progesterone receptors)
- Poor response as in Clomiphene therapy ☺ ®

LPD is common in the following stages of life:

- after menarche
- Pre-menopause
- 1st few cycles following delivery or abortion.

SIGNIFICANCE

- SPORADIC LPD: occurs in 30% of normal fertile females.
- PERSISTENT LPD: occurs in at least 2 consecutive cycles.

CLINICAL PICTURE

1. *Asymptomatic.*
2. *Menstrual irregularities:*
   a. **Pre-menstrual spotting** due to **irregular ripening** of the Endometrium.
   b. **Poly-menorrhea** due to **short luteal phase < 11 days.**
3. *Interference with implantation:* Of the fertilized ovum causing
   a) **Infertility** (4% of causes of infertility)
   b) **Early abortion** (35% of causes of repeated abortion).

Luteal phase defect

خلي بالك نقص Progesteron

إما

Absolute

- ↓ Follicle maturation
- hypothyroidism
- ↑ PRL
- ↑ A
- Endometriosis

Relative

- ↓ Receptors as clomiphene ~~Therapy~~ Therapy

Basal body Temperature





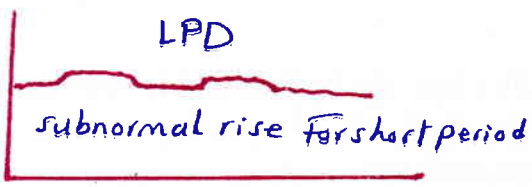

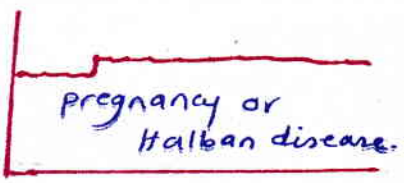

INVESTIGATIONS

Investigations are repeated in more than one cycle®

1- Endometrial biopsy by Pipelle cannula التفاصيل في غايه الاهميه:
- At day 26 (late luteal phase, within 2-3 days of expected period)
- Two samples on two consecutive cycles
- Histological date is correlated with the date of the NEXT menstrual period
- Lagging > 2 d= out of phase

2- Progesterone level: at 7th day post ovulation (if 3 - 10 ng / ml).

3- Basal body temperature in 2nd half of the cycle
- **Subnormal** rise or
- **Increased** for short time < 10 d.

TREATMENT

- **Clomiphene Citrate** (1st drug of choice) increases FSH.
- **Replacement therapy for progesterone:**
  - 25 mg suppositories / 12 hrs 2-3 days after ovulation.
- During pregnancy:
  - 17 α OH P caproate 250 mg IM/wk for 10 wks.
  - HCG 5000-10000 IU IMI daily as it is;
    - Luteo-trophic and prolongs the corpus luteal function
    - Could be preceded by HMG or Clomiphene citrate
- **Bromocriptine** for Hyperprolactinemia.
- **Thyroid replacement** for hypothyroidism.
- **Corticosteroid** for hyperandrogenemia.

Resistant ovary S (Savage S)

- **DEFINITION:** The ovaries do not respond to gonadotrophins.
- **POSSIBLE MECHANISM** decrease gonadotrophin receptors on the ovaries.
- **INVESTIGATIONS**
  - FSH & LH are increased, decreased estrogen.
  - Ovarian biopsy: normal number of follicles (differentiates it from premature ovarian faliure).
- **TREATMENT**
  - Cyclic E+P to induce cyclic bleeding may be followed by recovery.
  - Gonadotrophins are not useful.
  - Spontaneous recovery has been reported
  - Oocyte donation (unethical حرام شرعا و قانونا)

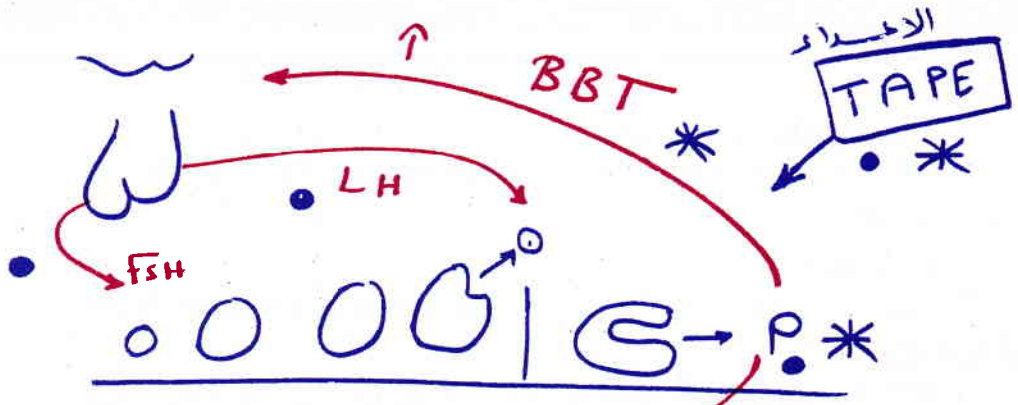

* Secretory endometrium for 2 weeks

implantation

تكمله الحمل حتى 10 weeks

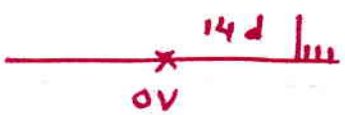

* Investigations :-

• III :-

Causes

CIP

INV

III

هذه الرسم تشمل يعني الموضوع كله

Hyper - Prolactinemia

- **Nature:**
  - It is ***single*** polypeptide
  - 198 A.A. Molecular weight 23,000 Dalton & 3 Sulfur bonds.
- **Normal level**
  - 2-20 ng/ml.
  - Variable secretion in the day (**so measured 3 times at least**)
- **Types of prolactin.**
  - LITTLE Prolactin (23.000 Dalton) → is the biologically active form.
  - GYLCOSYLATED Prolactin → PRL + CHO part.
  - BIG PRL (50.000 Dalton).
  - BIG BIG PRL (100.000 Dalton).
- **Origin:** acidophils (lactotrophs) of ant. Pituitary.
- **Control:**
  - ***What ↑ PRL***: **E** (↑ Prolactin but blocks its action) **TRH** (→ + pituitary → release TSH & prolactin) **& Serotonin.**
  - ***What ↓ PRL:*** prolactin inhibitory factor → Dopamine.

CAUSES OF HYPER-PROLACTINEMIA

Physiological

- **Pregnancy** (up to 200-400 ng/ml due to E)
- **Suckling** (100-200 ng/ml)
- **Stress, Sleep, Sexual intercourse, 2nd half of the cycle & hypoglycemia.**

Pathological

- **Hypothalamus: destruction** (CTINM) → ↑ Prolactin by ↓ dopamine
- **Pituitary:**
  - **Adenomas:** COMMONEST 50% (either prolactinoma or GH producing tumors)
  - **Empty cell $** *(diagnosis CT or MRI)*:
    - *Congenital* → (herniation of CSF in the sella turcica) → ↑ PRL due to pressure on pit. stalk & interference with the delivery of dopamine. Also squeezing of the gland → ↑ PRL & amenorrhea
    - *Acquired* → after surgery, tumors, infarctions or irradiation
- **Ovary:** PCO → ↑ E → ↑ PRL (in 25% of cases & rarely exceeds 30ng/ml)
- **Miscellaneous**
  - **T** = Thyroid → hypo or hyper
  - **R** = Renal &liver; ↓excretion by the kidney or ↓ destruction by liver

Hyper prolactinemia

Types

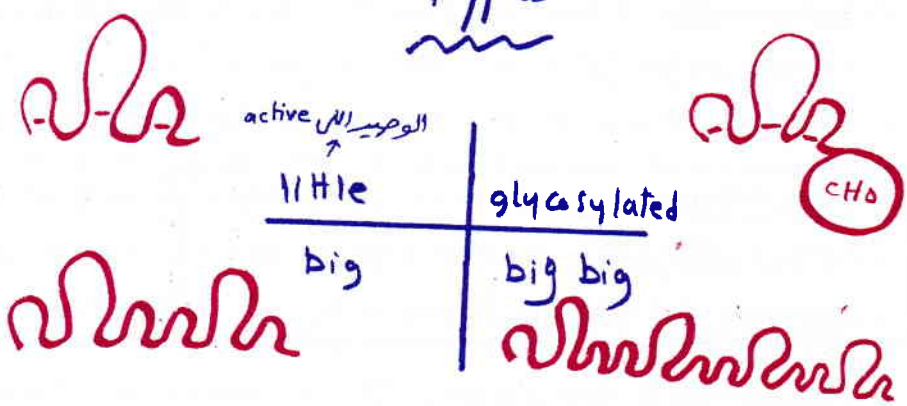

Cause

physiological

pregnancy +

7
- suckling
- stress
- sleep
- ex
- urgery
- second ½ of cycle

pathological

W
O
+

- T hyroid
- R enal & liver
- E ctopic
- N eurogenic
- D rugs

- ★ **E** = Ectopic sources of PRL as bronchogenic carcinoma or renal tumor
- ★ **N** = neurogenic, scars on chest stimulate nipple → PRL release
- ★ **D** = antipsychotic, antihypertensives (α methyl dopa), Antiemetics, MAOI & COCS (↓ dopamine or block dopamine receptors or ⊕ lactotrophs)

⇨ CLINICAL PICTURE:

1- Galactorrhea → milk production from non lactating breast usually bilateral from both breasts. Occurs in 30-60% of cases of ↑ PRL

⇨ **Diagnosis:** microscopic examination of the discharge (*fat droplets*)

- ♦ **Chiari-Frommel $:** amenorrhea galactorrhea following delivery
- ♦ **Forbes-Albright$:** amenorrhea galactorrhea following pit adenoma
- ♦ **Ahumada-del Castillo $:** amenorrhea galactorrhea in nulli-Para

2- Amenorrhea & Anovulation (↑ PRL accounts for 20% of cases)

3- Infertility, luteal phase defect & hirsutism (PRL → ↑ adrenal androgens)

4- Frigidity → decrease libido

5- Clinical picture of the **cause** as in pituitary tumors (headache + ↑ ICT)

6- Clnical picture of **complications** as bitemporal hemianopia

⇨ INVESTIGATION Exclude pregnancy + physiological causes

1. ***Prolactin level:***

⇨ < 50ng/ml	benign cause
⇨ 50 - 100 ng/ml	suspicious of adenoma
⇨ 100 - 300 ng/ml	highly suspicious of adenoma
⇨ > 300 ng/ml	diagnostic of malignancy
⇨ 2000 - 3000 ng/ml	tumor infiltration of cavernous sinus

2. ***Cause:***
   - ❖ **RFT, LFT, T3 & T4** → for hypo / hyperthyroidism
   - ❖ **FSH, LH →PCO**
   - ❖ **CT - U/S - MRI** (most accurate) for macro (>1cm) & micro adenomas (<1cm)
   - ❖ **Coned view of sella tercica X-ray:** distortion-erosion-expansion
3. ***Complications:***
   - ❖ **Field Ex.** For optic affection

clinical picture

1. ↑ PRL
   - Amenorrhea
   - Galactorrhea
   - inFertility
2. Cause
3. Complication

investigations

Physiological Causes + لنستبعد الحمل

1. ↑PRL نفسه
2. Cause
3. Complications

Can galactorrhea occur with normal prolactin?

- *Yes, due to:*
  - *Wide normal range*
  - *Hypersensitivity of the breast to normal prolactin.*
  - *Prolactin assay depend on immune reactivity & not biologic activity.*

TREATMENT

1- **Treatment of the cause:** hypothyroidism, renal & liver failure

2- **Idiopathic causes**

A. Bromocriptin (dopamine agonist) (look H & anti H page)
- Ergot alkaloid inhibits Prolactin secretion
- **Dose:** Tablet 2.5 mg during or after meals. Start with 1/4 to 1/2 tablets at bed time & increase by 1 /2 tablet as tolerated.
- **Maintenance:** 2-3 tablets daily. Monitor continuation with Prolactin

B. Lisuride (Dopergine):
- More potent with less side effects.
- **Tablet:** 0.2mg.

C. Cabergoline (Dostinex):
- Long acting oral preparation with less severe side effects.
- **Tablet:** 0.5mg once or twice weekly.

D. Quinagolide (Norprolac):
- It Is not an ergot alkaloid
- **Tablets:** 25, 50, 75 microgram once daily.

3- **Pituitary adenoma:**
- 1st **TREATMENT IS MEDICAL** (1/3 will disappear),
- **INDICATIONS OF SURGERY** (transphenoidal or transfrontal)
  - If failed (the tumor didn't decrease in size)
  - Pressure symptoms & signs on brain (bitemporal hemianopia)
  - Intolerable side effects
- If **RECURRENT OR UNFIT FOR SURGERY** → irradiation

4- **During pregnancy**

→ medical treatment → Bromocriptin is not teratogenic

- **Micro-adenoma (< 1 cm)** grow in 1% of cases
- **Macro-adenoma (> 1 cm)** grow in 15% of cases
- **Every 3m** → do field of vision

5- Repeat MRI or CT scan:

- AFTER 1 - 2 YEARS
- For detection of recurrence

ANATOMY OF THE PITUITARY GLAND مهمة

- Lies in the sella turcica, behind the optic chiasma
- Covered by diaphragm sellae → pierced by the pituitary stalk (carries vessels & nerves from the hypothalamus to the pituitary)
- On each side: the cavernous sinus
- Below: sphenoid bone

PARTS OF THE PITUITARY GLAND☺

	Anterior lobe = adenohypophysis			Posterior lobe = neurohypophysis
Origin	Rathke`s pouch (upper part of the oropharynx)			Down growth from the diencephalon
Control	Hypothalamic portal circulation			Nervous control
hormones	**acidophil**	**Basophil**	**Chromophobe**	Oxytocin & ADH Synthesis: hypothalamus Stored & released from the pituitary
	- GH - Prolactin	-FSH&LH -ACTH -TSH	- Reserve cells - produce prolactin	

Hyper - androgenism

PATHOPHYSIOLOSY

1-Types of androgen:

- **Testosterone** (0.2 - 0.8 ng/ml)
- **Dihydro-testosterone** (Testosterone by 5 α **reductase** → DHT)
- **Pre-androgens** (DeHydroEpiAndrosterone, DHEA Sulphate, Androstenedione)

2-Pathogenesis:

a- **Increased level of serum androgen**: Endogenous or Exogenous

Ovary		Adrenal
25%	Testerone	25%
50%	Androtenedione	50%
10%	DHEA	90%
0%	DHEA-S	100%

b-**Decreased production of SHBG**

1. Increase free testosterone
2. It is a globulin synthesized by liver
3. Decrease synthesis® occurs in liver diseases; hypothyroidism, acromegally, hyperprolactenemia, hyperanderogenism, obesity, insulin resistance

80%	19%	1%
Bound to SHBG	Bound to albumin	Free

c- **Local increase sensitivity** of hair follicles to normal testosterone levels (0.2-0.8 ng/ml), T acts locally on hair after conversion to dihydro-testerone DHT

SITES OF PRODUCTION

- The adrenals (under ACTH)
- The ovary (precursor to Estrogen)
- Peripheral conversion

CAUSES OF HYPERANDROGENISM

1. Ovarian causes:
   - PCO (2nd most common), Pregnancy luteoma, tumors & Post menopausal.
2. Adrenal causes: CAH, Cushing syndrome, tumors
3. Obesity: ↓ SHBG & insulin resistance??
4. Anorexia nervosa

5. **Iatrogenic:** minoxidil, levonorgestrel
6. **HypoThyrodisim:** ↑ Production of T & ↓ SHBG
7. **Idiopathic, constitutional (commonest cause):** Normal androgen level & regular menses (↑sensitivity or ↑5α reductase activity → conversion of T to DHT)
8. **Insulin resistance:** Insulin ↑ ovarian androgen either directly or through IGF_1R.
9. **pituitary:**
   - **Hyper-Prolactinemia:** PRL ↑ adrenal androgen
   - **Cushing disease** (basophil adenoma, adrenal hyperplasia)
   - **Acromegally**
10. **Abnormal Sexual differentiation:** Turner syndrome

⇨ CLINICAL PICTURE

Virilization (presence of some ♂ physical characters in the ♀)

- **Virilzing symptoms:** hirsutism, balding, mammary atrophy, harsh voice, clitoromegaly, ↑ muscle.
- **Non virilizing:** acne, diffuse alopecia, ↑ libido, menstrual irregularities, infertility.

Hirustism

- Growth of **TERMINAL** (coarse, pigmented, and longer) hair in unusual places (upper lip, chin, chest, back, pubis, thighs).
- Early age of onset → familial tendency
- Rapid rate of occurrence → tumors

Hypertrichosis ↑ **VILLOUS** hair (non sexual, thin & unpigmented)

⇨ DIAGNOSIS

History: family history, Virilizing symptoms, endocrinopathies & drugs

Examination:

- Manifestation of virilization & Cushing.
- Pelvis, abdomen, external genitalia & bimanual ex. of uterus & adnexae

Investigations

Hormonal profile:

- total & free androgens (↑ testosterone > 150-200 ng/dl = ovarian tumor, if ↑ DHEAS > 700 μg/dl = adrenal tumor & if all are normal = idiopathic)
- PCO: ↑ LH, ↑E, ↑ A
- FSH of post menopausal, PRL, thyroxin & cortisol level
- If CAH → 17 α OH progesterone
- Serum or 24 hr urinary cortisol & serum DHEAS: to diagnose cushing $, if suprarenal tumor → dexamethasone suppression test → no ↓ in cortisol

- **Imaging:**
  - ★U/S for the ovaries
  - ★CT + MRI → adrenal causes
- **Invasive procedure:** e.g. laparoscopy

TREATMENT

- **Treatment of the cause**
- **Non pharmacological treatment:**
  - Weight loss
  - Cosmetic therapy of alopecia:
    - hair is removed by shaving, depilatory creams, electrolysis ,laser
    - **Disadvantages** :time consuming &may leave pigmentation
- **Pharmacological treatment (response after 6-9months):**

1. **Aldactone® = spironolactone:**
   - AR inhibitor
   - Starting dose 200 mg/day → maintenance 25-50 mg
   - **Side effects**: Polyuria and hyperkalemia, it causes feminization of the male fetus and so pregnancy must be prevented
2. **Pills (avoid levonorgestrel containing pills):**
   - **E** → ↑ SHBG (↓ free androgens) & ↓ 5 α reductase
   - **P** → ↓ **LH** (↓ ovarian androgens)
     - **Marvelon, Cilest, Gynera**: 3rd generation of progesterone
     - Provera tablets 10-30 mg daily
     - **Depoprovera**: 150mg IM /3m
   - The response to treatment is **slow** (6-9 months) as hair life cycle is slow, therefore given for at **least 1or 2 years**
   - **↓ ACTH dependent adrenal DHEAS**
3. **Cyperoterone acetate (alone= Androcure 50-100 mg/d)**
   - **Action**:
     - Androgen receptor inhibitor in target organs
     - Inhibit 5α reductase enzyme
     - Progestogenic: decrease LH
   - **Dose**: 2mg CA+ 50 μg EE_2 → Diane & 2mg CA + 35 μg EE_2 → Diane 35
   - **Side effects:**

     1-**Expensive**, nausea, weight gain, breast tenderness, irregular uterine bleeding, decrease libido, depression

2-**Teratogenic** causes feminization of male fetus due to antiandrogenic effect, so must add COC to prevent pregnancy

4. **Dexamethazone** in CAH. 0.25 mg in morning & 0.5 mg in the evening
5. **Endometrial protection:** Shedding by intermittent progestin intake.
6. **Eltroxin®**: in hypothyroidism
7. **Flutamide (Eulexin 250mg/d)®:**
   - **Action:** AR inhibitor
   - **Side effects**: Hepatotoxic, galactorrhea, avoid pregnancy
8. **Finasteride (proscar 5mg/d)®:**
   - **Action:** 5 α reductase activity
   - **Side effects:** teratogenic so avoid pregnancy
9. **GnRH**: ↓ ovarian E & P + (E+P add back). SE: menopausal symptoms.

Central	Hormone producing glands			Peripheral
GnRH	Ovary		Adrenal	Flutamide Finasteride
	Estrogen	progest.	Dexamethasone	

10. **Insulin lowering agents**: Metformin → ↓ T in patients with PCOD

❋ MCQ: **anti-androgens are more effective for clinical symptoms > infertility**

Amenorrhea

Amenorrhea

Definition

* **1ry amenorrhea**

Absence of menstruation in a patient who has never menstruated by the age of

- 14 years with ABSENT 2RY SEXUAL CHARACTERS

Or

- 16 years with PRESENT 2RY SEXUAL CHARACTERS.

* **2ry amenorrhea:**

Cessation of menstruation in a patient who was menstruating for:

- 6 months (WITH IRREGULAR CYCLES)

Or

- 3 **successive** cycles (WITH REGULAR CYCLES)

Types

* **Physiological Amenorrhea**

1. **Pregnancy** "The commonest cause of 2ry amenorrhea"
2. **Lactation** as prolactin released during lactation is
   a. Anti GnRH
   b. Anti-gonadotropic
   c. ↓ ovarian steroidogenesis
   d. Blocks the action of E on the endometrium.
3. **Before puberty** due to low output of the pituitary gonadotropins.
4. **After menopause** because all the follicles are exhausted.

* **Pathological Amenorrhea** *(it is a symptom not a disease)* عرض وليس مرض:

⇨ **TRUE:**

- ☆ **Primary**
- ☆ **Secondary**

⇨ **FALSE:** (CRYPTO MENORRHEA) = OUT FLOW OBSTRUCTION

- ☆ **Congenital:**
  - ♣ Imperforate hymen (***the commonest cause***)
  - ♣ Transverse vaginal septum
  - ♣ Vaginal agenesis
  - ♣ Congenital cervical atresia
- ☆ **Acquired:**
  - ♣ Vaginal atresia after operation, trauma or burns
  - ♣ Acquired cervical atresia as after excessive cauterization

(Embryology page (24) (مكتوبه بالتفصيل في ال .

Causes of cryptomenorrhea

Congenital

1- uterus

- Non communicating horn

2- Cervix

- CX atresia

3- Vagina

- Absent vagina + uterus is present
- Transverse vaginal septum
- Imperforate hymen

Acquire

1- uterus

- Suturing of antr to postr wall in CS

2- Cervix

- Cautery, amputation, conization
- obstruction by a mass

3- Vagina

- rarely vag. gynatresia after a difficult instrumental delivery.

True amenorrhea

Hypothalamic causes = compartment 4

- **CONGENITAL SYNDROMES:-**
  - **Frölich S:**
    - ↓ **GHRH** → short
    - **Defect in satiety centre** → obese
    - **No GnRH** → amenorrhea, genital hypoplasia & no 2ry sexual characters
  - **Laurence Moon Biedl:** as above +
    - **Limb anomalies:** polydactyl +
    - **M**ental retardation +
    - **B**lindness due to retinitis pigmentosa
  - **Kallmann:**
    - Tall
    - Anosmia (*due to common embryologic origin → temporal lobe hypoplasia*)
    - Amenorrhea (isolated ↓ GnRH deficiency)
- **TRAUMA**: fracture base of the skull
- **INFECTION**:- encephalitis, meningitis
- **NEOPLASM**: destructing the hypothalamus
- **MISCELLANEOUS**:
  - Hyperprolactinemia of hypothalamic origin: ↓dopamine → ↑ prolactin
  - Psychological conditions:
    - Exercise, severe weight loss & severe stress:
      - Increase prolactin, ß endorphin
      - This leads to decrease pulsatile GnRH secretion
    - Anorexia nervosa *(disturbed body image)*:
      - Severe psychological disorder affecting hypothalamus & appetite
      - marked anorexia, emaciation, hypoglycemia, ↓ BMR, amenorrhea
      - *Treatment*: psychotherapy
    - Bulimia:
      - *Clinical picture:*
        - Binge purge eating (episodes of overeating followed by self induced vomiting, fasting, use of laxatives & diuretics)
        - amenorrhea & other menstrual irregularities, depression
      - *Treatment*: behavioral therapy

Causes of Amenorrhea

Endocrinal axis

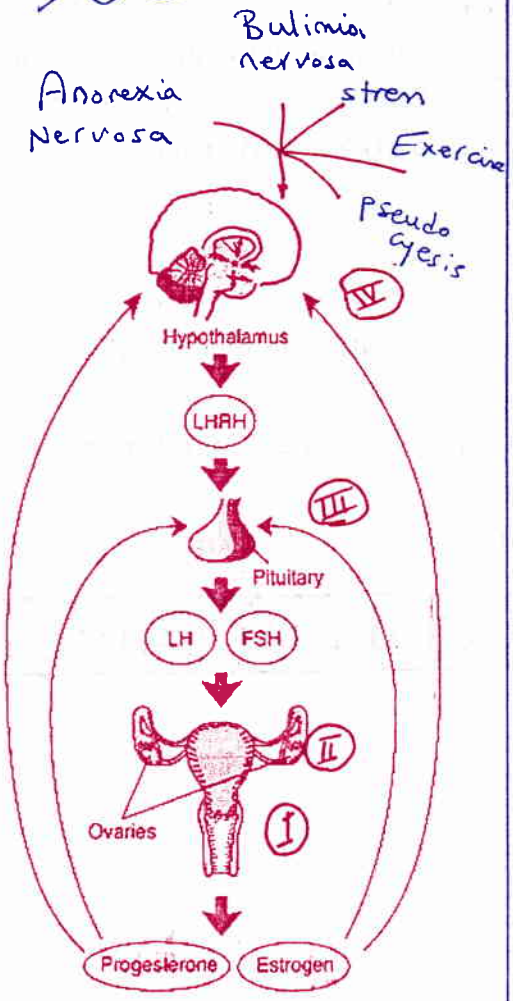

- Compartment I : out flow or uterine
- " II
- " III

other endocrinal organs

① Thyroid



② Adrenal

③ pancreas

General

Non Endocrinal

- under weight
  - Nutritional
  - deblitating diseases as T.B.
- Over weight

Obesity → ↑E + ↓SHBG

- **Pseudocyesis:**
  - *cause:*
    - Extreme desire to get pregnant (infertile patient) or
    - Marked fear from it (near menopause)
  - *Symptoms:*
    1-Amenorrhea due to decrease GnRH secretion.
    2-Abdominal distension (fat, gas, increased lordosis)
    3-Fetal kicks (intestinal movements)
    4-The patient thinks she is pregnant & may even have false abdominal pain (**SPURIOUS**) at the expected time of delivery
  - *On examination*: normal uterus, empty by U/S, -ve B-HCG
  - *Treatment*: psychotherapy
- **Post pill amenorrhea : (Shearman $):**
  - *Cause:*
    - Persistent hypothalamic suppression after stopping COC
  - *Inestigations:*
    - If amenorrhea >6months → investigate for causes other than pills
  - *Treatment*: induction of ovulation
- **Functional Hypothalamic amenorrhea**

Pituitary cause = compartment 3

- **CONGENITAL SYNDROMES:**
  - **Simmond:**
    - Panhypopituitarism due to any cause.
  - **Levi Lorain:**
    - ↓GH → Dwarfism
    - ↓FSH & LH → Amenorrhea
- **TRAUMA**: fracture base of the skull
- **INFLAMMATION**: meninigitis, encephalitis
- **NEOPLASTIC**:
  - *Types according to behaviour:*
    - **Destructive** as craniopharyngioma.
    - **Secretory.**
  - *according to size:*
    - Microadenoma (< 1cm)
    - Macroadenoma (>1 cm)}.

- *Classified according to cell of origin:*
  - **Acidophil adenomas:** acromegaly or gigantism (some produce **PRL**)
  - **Basophil adenoma:** Cushing (↑ **androgen & corticosteroids**)
  - **Chromophobe adenomas:** ↑ prolactin (**prolactinoma**)

★ MISCELLANEOUS:

▪ Sheehan $:

- **Definition**: It is necrosis of the anterior pituitary (75%)
- **Cause**: acquired by severe antepartum or post partum haemorrhage
- **Pathogenesis**:
  - **During pregnancy**: hyperplasia of the gland with ↑size > blood supply
  - **During labor:** shift of blood to the posterior lobe to produce oxytocin
  - **So, the anterior pituitary** is under relative ischemia.
  - **Genital hemorrhage→** pituitary affection (***through paravertebral plexus***).
- **C/P:**
  - ↓ **FSH&LH**:amenorrhea, genital organs atrophy &infertility
  - ↓ **Prolactin**: defective lactation **(1 st symptom)**
  - ↓ **TSH**: 2ry hypothyroidism.
  - ↓ **ACTH**: adrenal insufficiency.
  - ↓ **GH**: minimal effect
  - ↓ **MSH**: decreased pigmentation.
- **Treatment:**
  - **HORMONE REPLACEMENT (corticosteroids** then **thyroid** hormones).
    - **If no needed for pregnancy→** E+P.
    - **If is needed for pregnancy→**HMG.

▪ Empty sella $ (page 75)

▪ Hyper-prolactinemia syndromes (page 76)

▪ Cushing $:

- ↑ **cortisol** (***due to ↑ activity of adrenal cortex***) → tunkal obesity, thin limbs, moon face, amenorrhea & osteoprosis).
- **Androgenic** effects as hirsutism, acne.
  - **Types**:
    - **Pituitary Cushing (disease):** due to basophil adenoma.
    - **Adrenal cushing {syndrom}**→adenoma or adenocarcinoma.
    - **Hypothalamic cushing.**
    - **Ectopic** e.g lung cancer.
    - **Congenital adrenal hyperplasia**

Ovarian cause = compartment 2

★ HYPOFUNCTION (DECREASE E)

- **Congenital causes**
  - **Turner $ & mosaic turner**
  - **Deletions** of x chromosome with infantile internal & external genitalia
  - **Superfemale (47xxx)**
  - **Gonadal agenesis:**
    - Failure of germ cell migration
    - occurs in ♀ or ♂ (Swyer syndrome)
- **Truma:** oophorectomy (surgical, medical, irradiation)
- **Inflammatory:** mumps, TB
- **Neoplastic:** destructive tumors
- **Miscellaneous:**
  - Premature ovarian failure
  - Resistant ovary syndrome
  - Hyperprolactinemia
  - hyperandrogenism

★ HYPERFUNCTION (INCREASE E /A /OR BOTH):

- **Polycystic ovarian syndrome**
  - Increased E & A
- **Tumors:**
  - Estrogen producing tumors
  - Androgen secreting tumor → defiminization then virilization

Turner Syndrome ® §§ واخد بالك

ETIOLOGY

- It is a chromosomal disorder **45 XO or mosaicism** .
- 45 XO/46 XX or 45 XO/46 XY **Mosaic Turner**→ **may be tall ± pregnant"**

DIAGNOSIS

- **Suspected in the neonate by:**
  - **Lymphedema** of the dorsum of hands
  - Neonatal **sneezing**
  - **deformities** of the fingers & toes

- The main symptom is **primary amenorrhea**
- The ovaries are replaced by fibrous tissue "**streaked gonads**".
- The vagina and uterus **are under-developed**.

PHENOTYPE TURNER STIGMATA

- Short stature + variable degrees of ↓ intelligence
- Webbing of the neck ↑ carrying angle with deformities of the fingers & toes.
- Widely spaced nipples + under developed breasts(**shield chest**)
- Aortic Coarctation, Lymphedema of dorsum of hands & feet & horseshoe kidney

INVESTIGATIONS

- **Hyper-gonadotrophic hypogonadism**: High FSH > 40 mIU/ml & low estrogen.
- **Laparoscope** reveals streak gonads.
- **Karyotyping** to assess the chromosomal pattern shows 45 XO.
- **Buccal smear** to assess the chromatin pattern shows **absent Barr body**.
- **U/S**: streaked gonads

TREATENT

- **DELAYED** to prevent premature closure of the epiphysis
- **ESTROGEN** to induce breast development & to prevent osteoporosis. (at 13 yrs)
- **PROGESTERONE** is added to prevent endometrial carcinoma
- **GH** to increase the length (± 8 cm)
- In XO/XY: **GONADECTOMY** to avoid cancers (dysgerminoma in 25% of cases)
- The only hope in pregnancy is **OOCYTE DONATION** (not ethical حرام).

Q: HOW CAN YOU IDENTIFY TURNER AT BIRTH ?

- **Lymphedema** on the dorsum of hands &feet
- **X-ray:** deformities of fingers &toes (short metacarbal bones &metatarsal).
- **Karyotyping:** 45 XO

Q: WHAT IS TRIPLE X SYNDROM (SUPER FEMALE) ?

- **Genotype**: Female with 47 or 48 chromosomes (47xxx or 48 xxxx) →amenorrhea, infertility
- **Phenotype**: majority are normal (may have a lower IQ)
- **Genitalia**: infantile organs.
- **Treatment**: Gonadotrophins are used to induce ovulation

- Signs :-

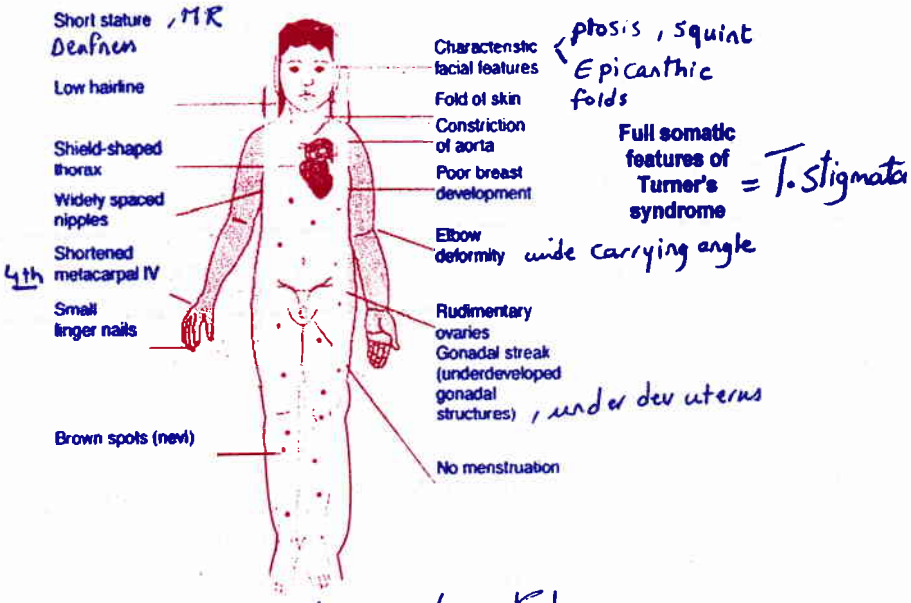

* Kd abn :- horse shoe Kd
* early NN signs = bil edema in hands & feet
& NN sneezing

oral MCQ

INV :-

Anatomy

① Buccal smear :- absent Barr bodies

= (inactive x chr) = no of x - 1

② Chr. study : 45 X O from Blood
Karyotyping

Samples & lymphocytes

③ hysteroscopy
⇒ atrophic end
vag cytology : parabasal cells

FSH > 40 mIU/ml , LH > 25 U/L
P < 2ng/ml , E_2 < 100 pg/ml
US → small ov + no GF
laparoscopy

Uterine causes:compartment 1

- **CONGENITAL ABSENCE**: aplasia or hypoplasia
- **INFLAMMATORY**: TB endometritis
- **TRAUMATIC**: hysterectomy or Asherman syndrome عالم يهودي

TESTICULAR FEMINIZATION (MORRIS) SYNDROME

PATHOGENESIS

- ***X- linked recessive*** diseases
- ***Absent or insensitive receptors*** in breast, hair follicle, vulva → no response to androgen secreted from testis (end organ insensitivity)
- They develop in a ***feminine direction***

CLINICAL PICTURE

1. ***karyotype***: 46xy (male)
2. ***phenotype***:
   - **Complete form**: female with well developed breasts (fat only, no gland) with small nipples, pale areola, pubic & axillary hair are absent
   - **Incomplete form**: variable degree of musculinized female
3. ***Gonads***: testis (found intrabdominally, in a hernial sac, in groin, in labia)
4. ***Internal genitalia***: gonads are testis, they secrete a hormone from sertoli cells (anti-mullerian hormone) → no uterus or tubes
5. ***External genitalia*** → normal vulva, a vaginal pouch from urogenital sinus

INVESTIGATION

- Normal male level of:
  - **Testosterone** > 300ng/dl
  - **Estradiole** 30pg/ml produced from
    - Adrenals, Testis
    - peripheral conversion (androstenedione to estrone)
  - This small E amount is unopposed by T → breast development
- Normal FSH, LH

TREATMENT

1- leave the pt till 16-18 years to allow breast development
2-gonadectomy must be done (testis ...malignancy in 25%)
3-ERT (maintains ♀ character, avoid osteoporosis, CVD), no need for progesterone

	TFS	MDS
1ry Defect	Androgen insensitivity (lack of receptors) or↓ 5α reductase E	Lack of Müllerian duct dev.
Chromosomes	46 XY	46 XX
Gonads	Testis mostly ectopic	Ovaries
Hormones	Normal male hormones	normal female hormones
Genitalia	no int. Genitalia but there is normal female external genitalia	
General ex.	No axillary or pubic hair + breast is only fat (no glands)	normal female secondary sex characters

INTRAVTERINE SYNECHIA (AMENORRHEA TRAUMATICA = ASHERMAN S) مهمه جدا

ETIOLOGY

(triad of trauma + infection + amenorrhea):

-Operations: Over-curettage of the endometrium, myomectomy, manual placental removal.

-Infections: Chronic endometrkis (most often TB endometritis), septic abortion.

DEGREES (BY HYSTEROSCOPY)

1st	Filmy adhesions (< ¼ Ut. Cavity is affected)	2 tubal ostia are seen
2nd	Partial obliteration (¼ - ¾ of Ut. Cavity is affected)	1 tubal ostium is seen
3rd	Complete obliteration (> ¾ Ut. Cavity is affected)	No tubal ostia is seen

TYPES OF ADHESIONS

Fibrinous – fibrous – cartilaginous – osseous.

CLINICAL PICTURE

Symptoms :

- History of the cause
- Amenorrhea /hypomenorrhea (never menorrhagia®)
- Infertility
- During pregnancy: recurrent abortion, preterm labor, placenta previa, accreta.

Signs :

- Limited passage of uterine sound

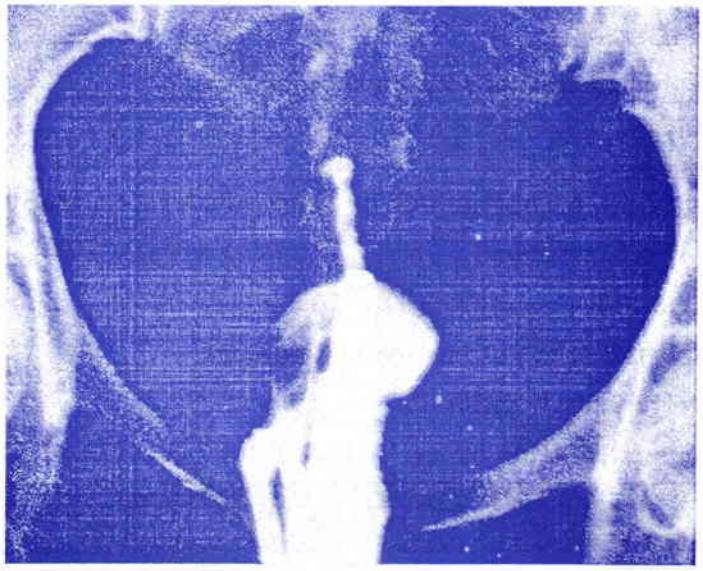



INVESTIGATIONS

- **Hysterography** shows irregular filling defects.(moth eaten appearance)
- **Hysteroscopy** (best).
- **Normal FSH & LH**
- **-ve estrogen-progesterone** withdrawal bleeding.

TREATMENT

- **Adhesiolysis**: Hysteroscopy guided **or combined hysteroscopy & laparoscopy.**
- **Prevention of reformation**
  - **pediatric Foley's catheter** (for 10 days) or
  - **IUD** inserted in the uterus for 1-2 months.
  - **Corticosteroids + antibiotics**
- **Endometrial proliferation** by **cyclic E & P** for 2-3 cycles (CEE 2.5 mg/d)

General causes

DISEASES :

- **General debilitating diseases:**
  - Severe anemia
  - Malnutririon
  - Chronic diseases as TB, renal or liver failure, DM

DRUGS:

- **Drugs causing hyperprolactinemia**
- **Drugs containing hormones:** Androgens or COC

ENDOCRINAL

- **Thyroid (hypo or hyper function)**
- **Acromegally**
- **Adrenal gland: hypo or hyper (CAH, Cushing)**
  - **Congenital adrenal hyperplasia**
    - **Cause**: deficiency of 21 hydroxylase enzyme (90% of cases)
    - **Pathology**: Failure of conversion of P to corticosteroid → ↓cortisol, ↑ACTH, ↑P &↑ androgens
    - **C/P**:
      - **Early type :** ambiguous genitalia
      - **Late type :** Heterosexual precocious pubrty
    - **Investigation**: ↑ 7-9 a.m. 17α OH progesterone, gene study
    - **Treatment**: steroids for life + cosmetic surgery of the genitalia

The management of amenorrhea according to the clinical picture

1) 1ry Amenorrhea with present uterus and absent 2ry sexual characters.

⇨ **Causes:**

a- Hypothalamic- pituitary- ovarian failure: CTINM
b- Congenital adrenal hyperplasia
c- General

⇨ **Investigations:**

Investigations= FSH	Normal	**→Adrenal**	**→ 17 α OH Progesterone**	
	Increased >40 ng/ml	**→ Ovarian causes**	**→ Karyotyping**	
	Decreased < 5 ng/ml	**→ Hypothalamus or pituitary**	**→ CT & MRI**	
			→ GnRH stimulatory test	↑FSH → **hypoth**
				↓FSH → **pit**

⇨ **Treatment:-**

- ★ **If ovarian causes** → Cyclic E + P (HRT)
- ★ **Hypothalamic- pituitary causes:**
  - ○ **If not in need of pregnancy** → Cyclic E+P
  - ○ **If Ineed of pregnancy:**
    - • FSH & LH "1 – 2 amp IM / d from 3rd day of cycle" or
    - • GnRH in a pulsatile manner every 90 min using a computerized pump with folliculometry "17 – 20 mm" & E "200 – 300 pg /ml" then add HCG "5000 – 10000 IV /IM"
- ★ **If adrenal causes** → cortisol

2) 1ry Amenorrhea with present uterus & present 2ry sexual ccc & "2ry amenorrhea "ده السؤال اللي بييجي دائما في الامتحان"

⇨ **Causes**

- ★ **Hypothalamic- pituitary- ovarian causes: TINM**
- ★ **Uterine causes:** Asherman's $

⇨ **Investigations**

- ★ **Exclude** pregnancy "by β-HCG", hypothyroidism "by T3, T4, TSH", hyper-prolactinemia "PRL >20 ng/ml" & cong. adrenal H "by 17α OH P &DHEA"
- ★ **Progesterone challenge test:**
  - ○ +ve (bleeding) → Anovulation

LONG
U
SL
V

blind
vaginal
pouch

- -ve (no bleeding) → do P + E challenge tests

★ **P+E challenge test**

- +ve (bleeding)→ (Axis abnormality) → FSH→ As before → Ovarian or H-P cause
- –ve (no bleeding) → uterine cause → (US, HSG,Hysteroscopy)

⇨ **Treatment**

★ **Ovarian causes: -**

- HRT
- PCO → induction of ovulation
- Thyroxin , Bromocriptin , Corticosteroid

★ **H-P causes:-**

- **If in need for pregnancy:** induction of ovulation by FSH &LH
- **If no need→** HRT

★ **Uterine Causes:**

- Treatment of Asherman $"

3) 1ry Amenorrhea with absent uterus and present 2ry sexual characters:

Causes	Investigations	Treatment
★ **Male**: Testicular Feminization (TF$) (Androgen insensitivity) ★ **Female**: Müllerian Dysgenesis (MD$)(cong. absence of uterus)	1- Karyotyping 2- Androgen level 3- IVP + spines X - ray in MD$	1. TF$: artificial vagina + remove the testis with HRT 2. MD$: artificial vagina

4) 1ry Amenorrhea with absent uterus & absent 2ry sexual characters:

⇨ 46 X Y + ↓ Testosterone synthesis

⇨ Management as TF $.

Oligomenorrhea is infrequent menses i.e. intermenstrual period >35 days.

Hypomenorrhea is decreased amount & duration of menses < 2 d.

- **Causes: Oligomenorrhea** and **hypomenorrhea** usually co-exist
  - **Constitutional** dates since puberty. Ovulation is normal & no treatment is required.
  - **Pathological**: Causes, diagnosis & treatment is like amenorrhea

How can you assess a case of amenorrhea?

HISTORY

- **Personal history:**
  - **Age:**
    - ✓ For the definition of amenorrhea
    - ✓ Whether physiological or pathological.
  - **Marital status**: to exclude pregnancy.
  - **Parity**: for previous pregnancy (Chiari frommel).
  - **Occupation & Special habits.**
- **C\O:**
  - **1ry amenorrhea:**
    - ✓ **False amenorrhea** which present by cyclic pain & urine retention
    - ✓ **True**:
      - Commonest cause is **constitutional**
      - Turner $, Mullarian agensis then Testicular feminization $.
  - **2ry amenorrhea** → 1st exclude pregnancy.
- **History of present pregnancy:**
  - **Amenorrhea** (analysis)
  - **Other gynecological symptoms** e.g anovulation, virilization, galactorrhea & development of 2ry sexual characters.
  - **Other systems:** hypothyroidism, cushing, acromegaly, D.M, T.B, severe anemia, drugs (↑prolactin hormone).
- **Menstual history:**
  - 1ry OR 2ry (in 1ry no menarche)
  - **Symptoms of anovulation:**
    - Irregularity of cycles
    - No premenstrual tension
    - No spasmodic dysmenorrhea
    - Absence of mid cyclic pain, spotting & discharge.
- **Obstetric History:**
  - Post partum amenorrhea due to® فكره حالات:
    - Another pregnancy
    - Lactation
    - **Hypothalamic cause**: Chiari fommel.

- **Pituitary causes**: Sheehan $
- **Uterine causes:** Asherman $, hysterectomy

- **Past History:**
  - Medical: T.B, D.M ,other endocrinal disorders
  - Surgical: hysterectomy, D&C, ovarian operation.
  - Drugs: (↑prolactin, hormones)
- **Contraceptive History:**
  - Amenorrhea following injectables.
  - Post pill amenorrhea.

EXAMINATION

- **General:**
  - **Weight**
    - Thin as anorexia nervosa, hyperthyroidism, D.M.
    - Obese: Frolich, Laurence Moon Biedle, PCO, Cushing & hypothyroidism.
  - **Height:**
    - Tall: gigantism, acromegally, TF$.
    - Short: Frolic, Laurence Moon Biedle, Turner, Levi lorain
  - **2ry sexual characters:**
    - Galactorrhea (causes of ↑Prolactin).
    - Virilization (causes of ↑ Androgen as PCO, CAH, tumors).
- **LOCAL:**
  - Exclude pregnancy.
  - Examine the genitalia (for gross pathology, ambiguous genitalia).

Endometriosis

Endometriosis كل امتحان حتلاقيها

DEFINITION

- It is the presence of **functioning endometrium** اهم كلمه (glands & stroma) outside **uterine cavity** (lining the uterine body)
- This endometrium is ∈ DEPENDENT & undergoes cyclic changes ودي المشكله

RISK FACTORS

the most important iS unopposed hyperestrogenemia

1. **Age**: 30-40 yrs (not before puberty, or after menopause except if receiving ERT)
2. **Parity**: Low parity
3. **Race**: White race
4. **Class**: High social class
5. **Genetic**:↑ with +ve FH

SITES

1- PELVIC:

a) Genital 99%:

- ★ **Ovary** → most common
- ★ **Peritoneum** → 2nd most common
- ★ Intra-Myometrium "adenomyosis"
- ★ Vulva, vagina, Cx, Intratubal, Ligaments & rectovaginal septum

b) Extra genital 1%: Bladder, Rectum, & Scars of episiotomy

2- EXTRAPELVIC:

- ★ Scars of laparotomy
- ★ Umbilicus
- ★ Others: gall bladder, umbilicus & lung

CAUSES: UNKNOWN BUT THEORIES

1- Sampson theory اهم واحده → menstrual regurgitation (more in ovary & DP).

- ❖ Regurgitation of endometrial fragments along the tube to be implanted on pelvic organs & peritoneum
- ❖ It occurs *normally* in 70 -90% of women
- ❖ Evidence of this theory:
  - ✓ Presence of implants in most dependent areas of the pelvis
  - ✓ ↑ed endometriosis after experimental cervical **Obstruction** (in monkeys)
  - ✓ Laparoscopic visualization of blood through fimbria during menses
  - ✓ Endometrial tissue can be implanted

Theories of endometriosis:-

unopposed E أهم حاجه

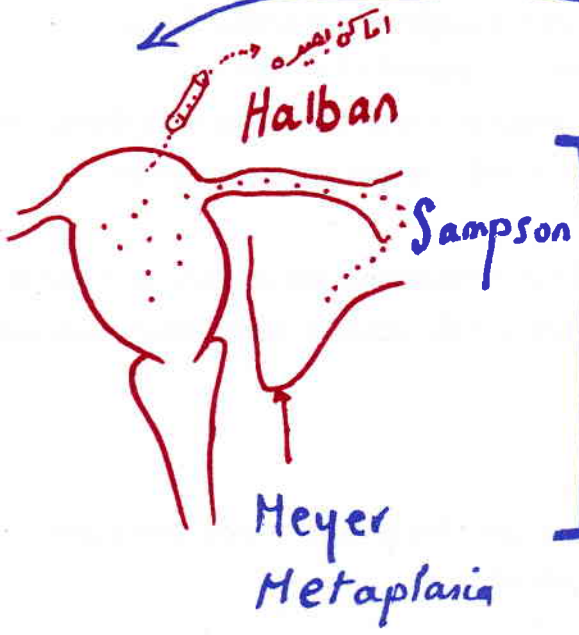

Induction
Immunologic
Implantation

Pathology:-

MAc

implants < Typical / subtle

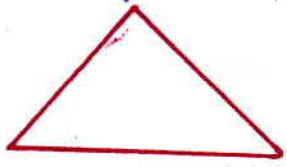

Adhesions

- Fixed RVF
- Filmy / Dense

mass < ov. / nodules < DP / Rectovag septum / utero sacral lig

MIc

glands + stroma

في العينات اللي بره الرحم

2- **Immunological theory** → defective leukocytes with failure to engulf & remove the endometrial implants.

- **Evidence of this theory**
  - ↑peritoneal macrophages activity
  - ↑ cytokines as α TNF
  - ↑ PG
  - ↑ Some antibodies as lupus anticoagulants & anticardiolipin.

3- **Meyers theory** → cœlomic metaplasia into endometrial epithelium.

4- **Induction theory**: unknown factor changes peritoneal epithelium into endometrium.

5- **Spread (Halban theory):** lymphatic / blood. Explains extrapelvic spread

6- **Hereditary factors**

7- **Implantation**: abdominal scar after CS or myomectomy, perineal scar after delivery

8- **Cullen diverticular theory:** deep growth of the glands. Explains adenomyosis only.

PATHOLOGY :

1. **Macroscopic:**

a) **Implants**: tender, thick & fixed
- **Typical lesions**: powder burn, gun shot or burnt match appearance
- **Subtle lesions**: red yellow lesions

b) **Adhesions**:
- Filmy or dense
- Fixed RVF

c) **Masses**:
- Nodules in DP, rectovaginal septum, uterosacral ligament
- **Ovary:** chocolate cyst, bilateral in 30% of cases

2. **Microscopic:**
- Endometrial glands + stroma
- **Uterus:** Arias Stella reaction

CLINICAL PICTURE

1-Symptoms (triad of pain, infertility & bleeding):

- **may be asymptomatic**
- **Pain: Pain is not related to the extent of the disease®**

1. **2ry spasmodic dysmenorrhea**
   - Starts few days **before menstruation** (congestion of implants)
   - ↑ in severity **during menstruation**
   - Reaches maximum at the **end of menstruation** (crescendo).
   - ↓ gradually few days **after menstruation**
   - In severe cases there is **no pain free intervals**

Site :-

Genital →

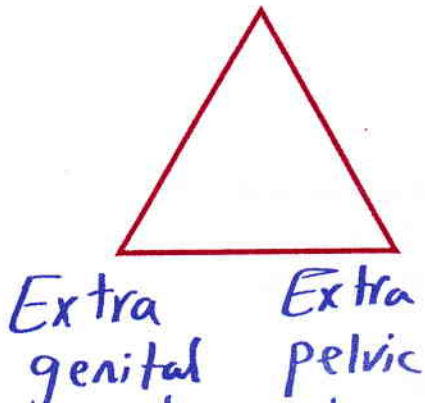

Clinical picture

Pain

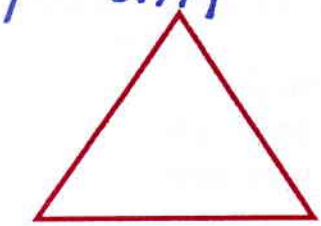

→ Menouria
B/R : cyclic

→ Bleeding / umbilicus
cyclic hemoptysis

Investigations

CA 125

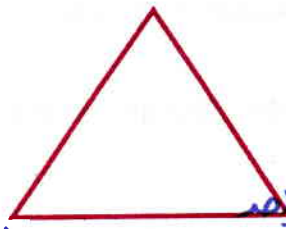

imaging
US
CT
MRI

D — T — Clarification

laparoscopy

Treatment

AntiE

Symptomatic

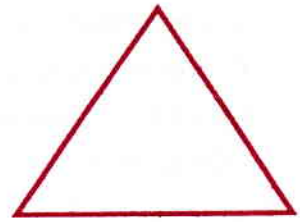

surgical

Cons — Radical

فشلت بخرجه بشيل

2. **Deep dyspareunia due to:**
   - Nodules in rectovaginal septum
   - Nodules in DP
   - Prolapsed ovaries
   - Fixed RVF
3. **Dysuria**
4. **Dyschazia**
5. **Deep pain:**
   a) Pelvic
      i. **Acute**: as complications of chocolate cyst
      ii. **Chronic** (pelvic congestion, ↑ PG)
   b) Backache: affection of uterosacral ligaments

⇨ **Bleeding:**
- **Menorrhagia** (due to uterine congestion)
- **Polymenorrhea** (due to ovarian congestion)

⇨ **Sub-fertility Due to:**
- ★ **Anatomical defects:** Adhesions
  - A. **Ovarian encapsulation** → lutenized unruptured follicle
  - B. **Tubal block** → ectopic or infertility
- ★ **Functional defects:**
  - a) **↑PG** → LPD, recurrent abortion 40% (also ↑ autoantibodies as lupus anticoagulants or anticardiolipin antibodies)
  - b) **Intraperitoneal inflammation** & ↑ peritoneal macrophages → phagocytosis of sperms

⇨ **Extra-pelvic symptoms:**
- Cyclic bleeding per rectum + dyschazia
- Cyclic hematuria "**menouria = youssef syndrome**" + dysuria
- Cyclic hemoptysis
- Umbilical nodules → at menses the nodules become tender, bluish, enlarge & bleed.

2- Signs (not all may be present):

⇨ **Ovary:** **Ovarian Cysts** (**Chocolate cysts** bilateral in 50% of cases)
⇨ **Uterus:** RVF uterus "fixed"
⇨ **D.P.**: Tender nodularity of utero-sacral ligament (felt by PR)
⇨ **Vagina**: tender thickened rectovaginal septum (felt by PR)
⇨ **Vulva**: may show bluish cysts

INVESTIGATION

1. **Imaging**
   - U/S, MRI (accurate), CT
   - Cystoscopy & Proctoscopy
2. **CA125:**
   a) **Not specific** but for follow up.
   b) **Has D.D.**→ it is produced by other celomic epithelium
      i. Pregnancy
      ii. Endometriosis, uterine fibroids (benign tumors)
      iii. Pancreatitis, normal menstruation, pelvic inflammatory disease, liver disease.
      iv. Tumors of the ovaries, uterus, tubes, endometrium, lung, breast, & GIT.
3. **Laparoscopy (gold standard of diagnosis)**
   - **Diagnosis by biopsy** → glands & stroma of endometrium
     - Typical lesion → **gun shot** or **powder burn app.**(dark brown implants)
     - Subtle lesion→**Yellowish** or **Red implants**, adhesion, nodules, cyst
     - Commonest site is the ovary then DP → fixed RVF
     - Ovaries:
       - Enlarged, thick tunica albuginea
       - Surface: small dark nodules
       - Chocolate cysts
   - **Therapeutic**
   - **Classification** (American fertility society) **According to**: Adenxal & peritoneal implants, Adenxal adhesions & Douglas pouch obliteration
   - **Scoring:**(I: mild 1 – 5, II: moderate 6 – 15, III: severe 16 – 40 & IV: Extreme > 40)

Endometriotic nodules	Microscopic	<1cm	1-3 cm	>3cm
adhesions	No	filmy	Dense	
Tubes				
Ovaries				
Peritoneum			Partial obliteration	Complete obliteration
Scores	1-5	6-15	16-40	>40
Stages	Mild (I)	Moderate (II)	Severe (III)	Extreme (IV)

4. **Inv for infertility** (tubal & ovarian factors)
5. **Other lesions:** Biopsy & histopathology for umbilical or implantation nodules

D.D.

- **Frozen pelvis**: TB, pelvic malignancy, PID, extensive surgery
- **Symmetrical or asymmetrical enlargement of uterus**
- **Ovarian chocolate cyst** → endometrioma, tubo-ovarian abscess, endometrioid carcinoma of the ovary

TREAT MENT

Treatment depends on:

1. Symptoms (pain, bleeding)
2. Presence of surgical removable lesions
3. Presence of infertility

1. Prophlaxis:

- **Avoid delay of age of child bearing**
- **OCPs:** has a suppressive value on the disease

2. Symptomatic treatment:

a) **Mild to moderate disease**
b) **Pain**: anti PG
c) **Bleeding**: COC, progestin.

3. Medical:

- **In severe cases also adjuvant to surgery**
- **Results:**
  - Improvement 80%
  - Pregnancy 50%
  - Recurrence 40%

Progesterone	GnRH	OCP
• 30 mg/d oral for 6 m. • **1st choice** as it is effective as other methods but cheap & less adverse effects. • **Prog.+ ocp**:-At 1st pseudo-deciduas & on prolonged use → atrophy	• Reversible pseudo- menopause by the continuous manner • IM or sc (zoladex/ 28 d) or nasal spray • **Prolonged use →** ❋ Hot flushes ❋ Osteoporosis but to avoid use (**E+P add back**) ❋ Dry vagina. ❋ Expensive.	• One tablet/ day for a year • (use progesterone dominant & low dose estrogen 30-35μg) • **Side effects:** see contra ception

Danazole	Gestrinon (Dimetriose®)
• 400-800 mg/d for 6-9m • **Expensive** • Weak androgen → Isoxazole derivative of 17α ethinyl testosterone	• 1.25 – 2.5 mg 2/wk • 19 nor-testosterone derivative

- (-) GNRH effect on pit.
- (-) Effect of gonadotrophins on ovary
- (-) effect of E&P on endometrium
- ↓SHBG, ↑ free A, & ↑ clearance of E&P
- **Net result**: pseudomenopause → ↓E &P, ↑A & atrophic endometrium

- "Action is guided by relief of symptoms or appearance of amenorrhea or side effects (androgenic, dry vagina, hot flushes)"

- **Disadvantages**:
  - **Expensive** (progestins have same effect + less side effects + cheap)
  - **Mild androgenic action:**
    Acne, hirsutism, temporal balding, deepening of voice, ↓ muscle mass, clitorimegally
  - **Menopausal symptoms:**
    Hot flushes, ↓ libido, dyspareunia (atrophic, dry vagina) & breast atrophy
  - **Metabolic effect**:
    liver failure, impaired glucose tolerance, hypertension, salt & water retention
- **CI:** pregnancy, cardiac, liver, renal diseases, DM, HTN.
- **Other indications:**
  - Endometriosis (**main indicaition**), Endometrial hyperplasia, fibroid
  - DUB (**metropathia hemorrhagica**)
  - Isosexual precocious puberty
  - Premenstrual tension syndrome

4. Surgical

- **In extreme cases**
- Recurrence after surgery 5-20% in 1st year & 40% after 5 yrs
  - **Laparotomy or laparoscopy** → with laser, electro-cautery
  - **Conservative Treatment: (if seeking fertility)**
    1. **Dissection** of adhesions
    2. Ovarian **cystectomy** for chocolate cyst.
    3. ***Laparoscopic uterosacral nerve ablation*** (LUNA)
    4. **Plication** of round ligament may be done (to prevent RVF)

- **Radical Treatment**: (if not seeking fertility)
  - Mainly **Oophorectomy** or TAH + BSO (HRT can be used after 5 years from the operation)
  - **Especially** if old age + severe symptoms + failed above measures.

5. Infertility:
   - **No mass**: induction of ovulation
   - **Mass**: remove the mass then induction of ovulation
   - **Previously**: pre or post operative hormonal suppression
   - **ART or IVF-ET**: Used when other measures are failed

Adenomyosis

DEFINTION

- Endometrial glands (basal parts) in the myometrium (endometriosis interna)
- It is less responsive to E & hormonal changes (lack E receptors)

PATHOGENESIS : usually multifocal

1) Cullen's diverticular theory الاهم
2) Blood / lymphatic spread
3) DENOVO

PATHOLOGY

THE RESPONSE TO OVARIAN HORMONES IS LIMITED

- **Diffuse disease**:
  - More common
  - Symmetrically enlarged uterus (<14 weeks)
  - Cut section → brown spots (glands + altered blood), reticular appearance.
- **Focal (adenomyoma):** usually in posterior wall of the uterus.

CLINICAL PICTURE

USUALLY MULTI-PARA AROUND 35-40 YEARS

Symptoms: **(bleeding + pain + infertility in less than 1/3 of cases)**

- **Menorrhagia** (most common in 75% of cases)

  Due to:
  - Large uterus
  - Pelvic congestion
  - Associated endometrial hyperplasia or fibroid

- Congestive dysmenorrhea
- Leucorrhea
- Diurnal frequency

Signs:

- The uterus كبير وبيوجع
  - Does not exceed 12 weeks in size.
  - Tender
  - Mobile
  - Firm

DIFFERENTIAL DIAGNOSIS :

- Causes of **symmetrically enlarged uterus**.
- Between **adenomyoma and leiomyoma**:

	Adenomyosis	Fibroid
Age	Younger	30 – 40 years
Etioiogy	Cullen divericular theory	Hyper E
Size	< 14 wk, symmetrical	Large, asymmetrical
3Capsule	Reticular appearance	Whorly appearance
Capsule	No capsule	There is a capsule

INVESTIGATIONS

1) **Ultrasound** (difficult).
2) **MRI** (more accurate):
   - Enlarged uterus with small cysts & thick Myometrium.
   - Uterine echogenicity ranges from normal to slightly hypo-echoic (which represents menstrual engorgement of the endometrial glands)
3) **Hysteroscopy**: Wide gland openings
4) **Histopathology**: after TAH is the only way of diagnosis *(retrospective diagnosis)*

TREATMENT

1. **Medical:**
   - Less response to hormones **as the basal parts of the glands lack ER**
   - Analgesics, anti PG for dysmenorrhea
2. **Surgical:**
   - Panhysterectomy: 1st line (Hormonal treatment in young ♀ but ineffective)
   - Localized resection in focal types (utriclectomy) + NSAID for pain

Premenstrual tension syndrome

DEFINITION

- Certain syndrome bearing specific time relationship to menses
  - Few days **before** menses
  - **Absent** in the follicular phase
- It is a group of cyclic physical and psychological symptoms (± 150 symptom).

N.B.: → occurs only in ovulatory females

ETIOLOGY : (UNKNOWN BUT THEORIES)

- Central:
  - Changes in neuro-peptides in brain **endorphins** & **serotonin** → mood changes
  - ↑**Prolactin** → affect intestinal motility.
- Endocrinal:
  - ↑ **E** / ↓ **P ratio**
  - ↑ **ADH** & **aldosterone** → salt and water retention (May be due to E or P).
  - ↑ **Prolactin** → mastalgia
- Allergy to ovarian hormones.
- Vitamin deficiency: B6 – B1 def.
- Diet: High salt with decrease sugar intake

CLINICAL PICTURE : (CYCLIC AT LUTEAL PHASE AT LEAST FOR 3 CYCLES)

- Age: usually at 30 – 40 y (may be severe up to suicidal tendency in 5% of cases)
- Physical symptoms: Mastalgia, Joint pains, Abdominal fullness and bloating
- Psychological symptoms: Depression, Fatigue, Headache & Irritability.

TREATMENT

- General: reassurance, encourage exercise & change the life style
- Medical:
  - Premenstrual
    - Mild sedative as barbiturate
    - Spironolactone قبل الدوره (avoided as → electrolyte imbalance).
  - Pain: anti PG
  - Diet:
    - ↑ sugar intake, ↓salt
    - **Linolenic acid** derivatives (PRIMAROSE)

- **Mastalgia:**
  - Vit. B_6 (**PYRIDOXINE** 100mg) - B_1 : ↑ serotonin & dopamine
  - **Dopamine** agonists → **bromocreptin**
- **If severe** → **Hormonal inhibition of ovulation**
  - → **COC** is the best
  - → **Progesterone** or androgen in latter half of cycle.
  - → **GnRH**
  - → **mefipristone**

Dysmenorrhea

DEFINITION

Pain related to menstruation

1. SPASMODIC (1ry= idiopathic) DYSMENORRHEA

DEFINITION

- **SPASMODIC** (colicky) pain of uterine origin
- occurs on the **IST DAY** of the period
- in the **ABSENCE** of any organic pelvic pathology as:
  - **Ectopic**: no cervical motion tenderness, -ve preg. Test
  - **Salpingitis**: no Chlamydia or gonorrhea on cervico vaginal cultures
  - **Appendicitis**: no rebound tenderness, normal TLC, ESR
  - **Any pelvic pathology**: free examination and US

SITE

- **LOWER ABDOMINAL** may radiate to lower limbs.

TIME

- The **IST DAY** of menstruation with or just before the flow, it then rapidly ↓
- Occurs only in **OVULATORY** cycles. (Usually 2-3 years after puberty).
- Usually in **VIRGINS** & **NULLIPAROUS** esp. if sedentary life & ↓ after childbirth.
- May be associated with **NAUSEA**, **VOMITING**, **SWEATING** and **FACIAL PALLOR**.

ETIOLOGY

- Unknown may be
  - **Presence of** ↑ prostaglandins or increased sensitivity to it (esp. excess of $PGF_2\alpha$).

- ★ **This is the most accepted theory as:**
  - There is ↑ **$PGF_2\alpha$** in menstrual blood with severe dysmenorrhea.
  - There is good relief of symptoms with anti-prostaglandins.
- ⇨ Inability of menses to pass freely as in:
  - ★ **Obstructive theory** (acute anti-flexion or cervical stenosis),
  - ★ **Hypoplastic theory** (underdeveloped uterus can't expel blood),
  - ★ **Disturbed polarity** (contraction of Cx. and isthmus),
- ⇨ Abnormal stimulation / sensitivity of nerves: Muscle ischemia, Low pain threshold
- ⇨ Psychological, emotional and environmental factors.

TREATMENT

- ♣ **General:** Avoid sedentary life, correct anemia & Reassurance
- ♣ **Medical ℞:** **Anti PG (main treatment)** as Mefanemic acid, naproxen, ibuprofen, Other anti-spasmodics and anti-cholinergics (not very effective)
- ♣ **Hormonal:** Inhibit ovulation by OCPS or E (↑ development & Blood supply).
- ♣ **Surgical** لا تذكرها الا عند الطلب **xxx:**
  - ⇨ D&C (dilate pathway + lacerates Para-cervical sympathetic nerves) up to No. 14 Hegar's dilator + but recurs 6-9 in. later and may cause habitual abortion.
  - ⇨ **Injection** of pelvic plexus.
  - ⇨ **Presacral neurectomy** or LUNA:
    - ☞ **Action:** cuts motor (↓ uterine spasm), sensory nerves & ↑ vascularity.
    - ☞ **Disadvantages:** difficult, pain recurs + injury to ureters or iliac vessels.

2. MEMBRANOUS DYSMENORRHEA

DEFINITION

- ♣ **Painful** passage of large **endometrial casts** during menstruation

ETIOLOGY : UNKNOWN كالعاده

- ♣ may be due to ↑ **development** of the endometrium (↑ P or hypersensitivity to it)
- ♣ The pt is **young, ovulatory** and has dysmenorrhea **since menarche**.
- ♣ It is **not improved** by labor.
- ♣ Severe pain in **1st few days** with **scanty flow**.
- ♣ Then passage of complete **membranous casts** → Relief of pain & ↑ flow.

TREATMENT

- ♣ Repeated D&C.
- ♣ Suppress ovulation (progesterone dominant OCPS for few cycles).

3. CONGESTIVE DYSMENORRHEA

DEFINITION

- **Continuous dull aching pain in lower abdomen and back** due to pelvic disease
- The pain is **relieved by menstrual flow.**

CLINICAL PICTURE

- It usually occurs **later** in life (usually in **parous** women)
- Starting **few days (3-5) before menses** & gradually subsides with the flow.
- Usually associated with **menorrhagia** or **poly-menorrhea** and **vaginal discharge**.

ETIOLOGY (PELVIC CONGESTION)

- **Inflammatory** (Cellulitis, peritonitis, salpingitis, cervicitis).
- **Neoplastic** as fibroids.
- **Displacement** (RVF & prolapse).
- **Functional or simple** (emotional, sedentary life, constipation, coitus interruptus).
- Endometriosis has special character of pain → 2ry spasmodic (CRESCENDO).
  The pain ↑ with the passage of the flow to reach maximum last day of menses.

TREATMENT

- Treat the cause
- Avoid constipation.
- Glycerin - icthyol suppositories decrease pelvic congestion.

4. OVARIAN DYSMENORRHEA

DEFINITION

- Dull aching pain نقح
- In 1 or both iliac fossa علي ناحيه واحده او ناحيتين
- Preceding menstruation & relieved by it.

ETIOLOGY

- Ovarian **congestion** (thick tunica albuginea)

TREATMENT

- Analgesics, Glycerin icthyol suppositories or Suppress ovulation
- **In severe cases:** ovarian sympathectomy (**cutting infundibulopelvic ligament**).

INFERTILITY

INFERTILITY العقم

DEFINITION

1ry infertility

- Inability to conceive after 1 y of
  - Regular
  - Unprotected sexual intercourse
  - With no previous conception what ever its outcome → "Full term, still birth, abortion, EP & VM"

2ry infertility

- Inability to conceive after 2yrs of
  - Regular sexual intercourse.
  - Without the use of any contraception (including lactation)
  - After previous conception

STERILITY العقم

- **Definition**: Sterility means ***ABSOLUTE*** inability to conceive.
- **Management**
  - Normalize the secondary sexual characters and the sexual life
  - **Gamete donation & surrogate mothers** الام الستاجره may be the only hope (unethical)
- **Examples include:**
  1- Premature ovarian failure and menopausal women.
  2- Absent ovaries or uterus.
  3- Testicular atrophy and permanent non-production of sperms.
  4- Klinefelter's syndrome.

INCIDENCE

10 - 15 %, depending on

1. **Age of the couples:**
   - ***AT 20 Y***: 7% infertile
   - ***AT 40 Y*** : 20% are infertile due to ↑ incidence of endometriosis & fibroids
2. **Presence of** STD's or PID
3. **Exposure of males to pollution**

INFERTILITY

1ry :- Marriage



2ry

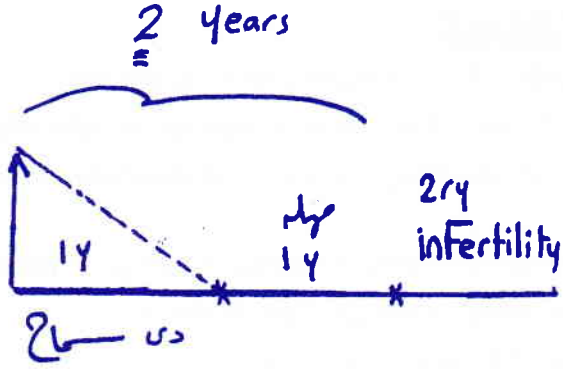

على ما الهرمونات ترجع لل normal
بالذات هرمون PRL
فيمتنعش احاسب المريضه على هذه
السنه

رأى آخر لل infertility

= Inability to bring a viable offspring

يعنى كمان يشتمل على abortions

Normal conception rate حفظ صم

- **1st month** 15 – 20 %
- **after 6 months** 50 – 75 %
- **after 12 months** 85 – 90 % "

- **But treatment is not recommended before the first year except if**
  - Apparent disease e.g. irregular menses
  - Advanced age

ROLE OF FEMALE

- **Ovulation** under effect of hypthalamus & pituitary.
- **Transport** of ovum from ovarian surface to tube (there must be an optimum tubo-ovarian relationship, normal peritoneum, fimbria, short distance, no adhesions)
- **Transport** of sperms through vagina → cervix → tubal ostia
- **Transport** of morula through tubes to uterus
- **Implantation** of blastocyst in uterus

ROLE OF THE MALE

- Spermatogenesis, transport, deposition

ETIOLOGY (MORE THAN ONE CAUSE MAY BE PRESENT)

I-Female factors "55%"	1. **Ovarian factors** 25% "commonest cause of 1ry infertility" 2. **Tubal factors** & peritoneal factors: 20% (commonest cause of 2ry infertility). Pelvic endometriosis is reported in 10-25% of infertile ♀. 3. **Uterine factors** 5% 4. **Cervical factors** 5%
II- Male factors "35%"	
III- Coital factors "5%"	
IV- Unexplained "5%"	

I- OVARIAN FACTORS (25%)

Commonest cause of Iry infertility

CAUSES (WHO CLASSIFICATION):

- **Group 1:**
  - Hypothalamic pituitary failure
  - ↓ FSH & E
  - -ve withdrawal after 'Progesterone'
  - Causes:
    - **Congenital**
    - **Trauma** → surgical, radiological, direct
    - **Inflammation** → meningitis, encephalitis
    - **Neoplasm** → from pituitary gland "glioma, meningioma"
    - **Miscellaneous** → empty sella $, psychological, ↑prolactin & obesity
- **Group 2:**
  - Hypothalamic pituitary dysfunction,
  - Normal gonadotrophic & estrogen levels
  - +ve withdrawal after 'P'
  - Causes:
    - **PCO**
    - **Idiopathic Anovulation**
- **Group3:**
  - Ovarian failure
  - Increase FSH & decrease E
  - -ve withdrawal after 'P'
  - Causes:
    - **Congenital**
    - **Trauma** → surgical, radiological, direct
    - **Inflammation** → oophritis
    - **Neoplasm** → benign & Malignant
    - **Miscellaneous** → premature ovarian failure, resistant ovary $
- **Other group:**
  - ↑Prolactin (15%) & Hyperandrogenism,
  - LPD (3-4 %), resistant ovary syndrome& luteinized unruptured follicle

Ovarian Factor

• Causes:-

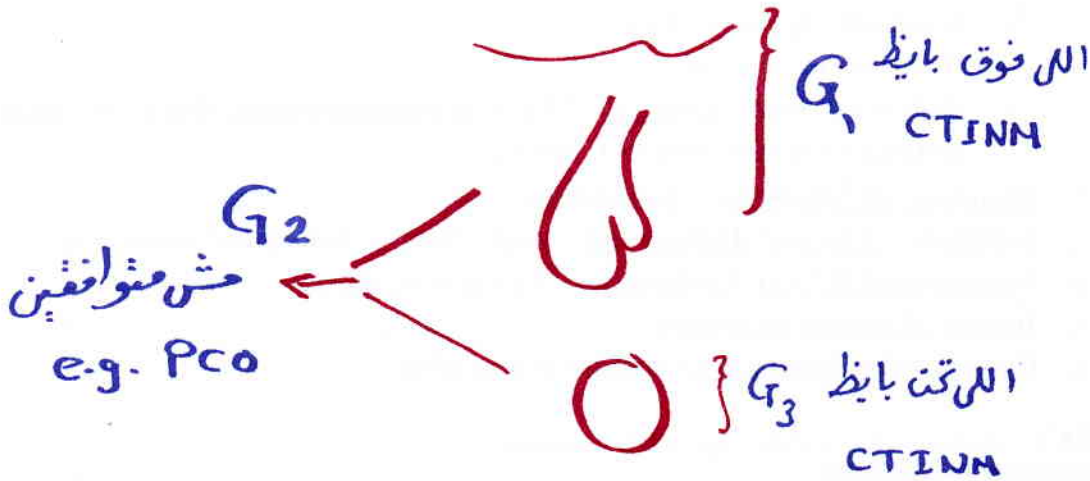

Other groups

- ↑ PRL
  - A

- LPD

- LUF ↓

- Resistant ovary syndrome.

CLINICAL PICTURE

SYMPTOMS:

1. **Symptoms of ovulation** مهمه جدا خلي بالك :-
   - ★ Regular menses,
   - ★ Spasmodic dysmenorrhea,
   - ★ Premenstrual tension,
   - ★ **Midcyclic triad** {discharge (↑E), pain (=mittelschmerz due to ovulation), spotting (transient drop of E level)}
2. **Symptoms of ↑prolactin: -** galactorrhea
3. **Symptoms of thyroid dysfunction: -** weight changes, heat or cold intolerance
4. **Symptoms of PCO or ↑androgen: -** ↑ hair growth, obesity.
5. **History of trauma or surgery**
6. **Contraceptive history of : -** implants or injectables

SIGNS: obesity, galactorrhea , thyroid dysfunction

INVESTIGATIONS

A) TO PROVE ANOVULATION

1. **Basal body temperature**
   - ★ **Normally** biphasic (↑ 0.3-0.5^0 in the 2nd half due to P),
   - ★ **Monophasic** in anovulation
   - ★ **Subnormal rise** for **short duration** (10 d) in luteal phase defect
   - ★ **If persistent** ↑ (Halban's or pregnancy)
   - ★ **Disadvantages**: not so accurate, affected by infections & fevers
2. **Serum progesterone (mid luteal or day 21 of 28 day cyle☺®)**
   - ★ <3ng = anovulation,
   - ★ >12ng/ml = ovulation,
   - ★ 3-12 (كتاب القسم 10) ng/ml = LPD
3. **Premenstrual endometrial biopsy:**
   - ★ **Proliferative** in anovulation, **secretory** in ovulation.
   - ★ In **LPD** there is lag > 3 days between menstrual dating & histological dating.
   - ★ Also allows diagnosis of infections as TB.
   - ★ **S.E.**: disturbing a co-existing pregnancy
4. **Folliculometry** الاهم الاهم الاهم (mature follicle is 20ml)
5. **Laparoscopic** visualization of CL, detection of **LH surge in urine**
6. **Vaginal smear** (P effect = intermediate cells)
7. **Cervical mucus changes:**
   - ★ Profuse, watery, +ve Fern & Spinnbarkeit (just preovulatory)
   - ★ Turns -ve on day 17-21 progesterone effect

Investigations:-

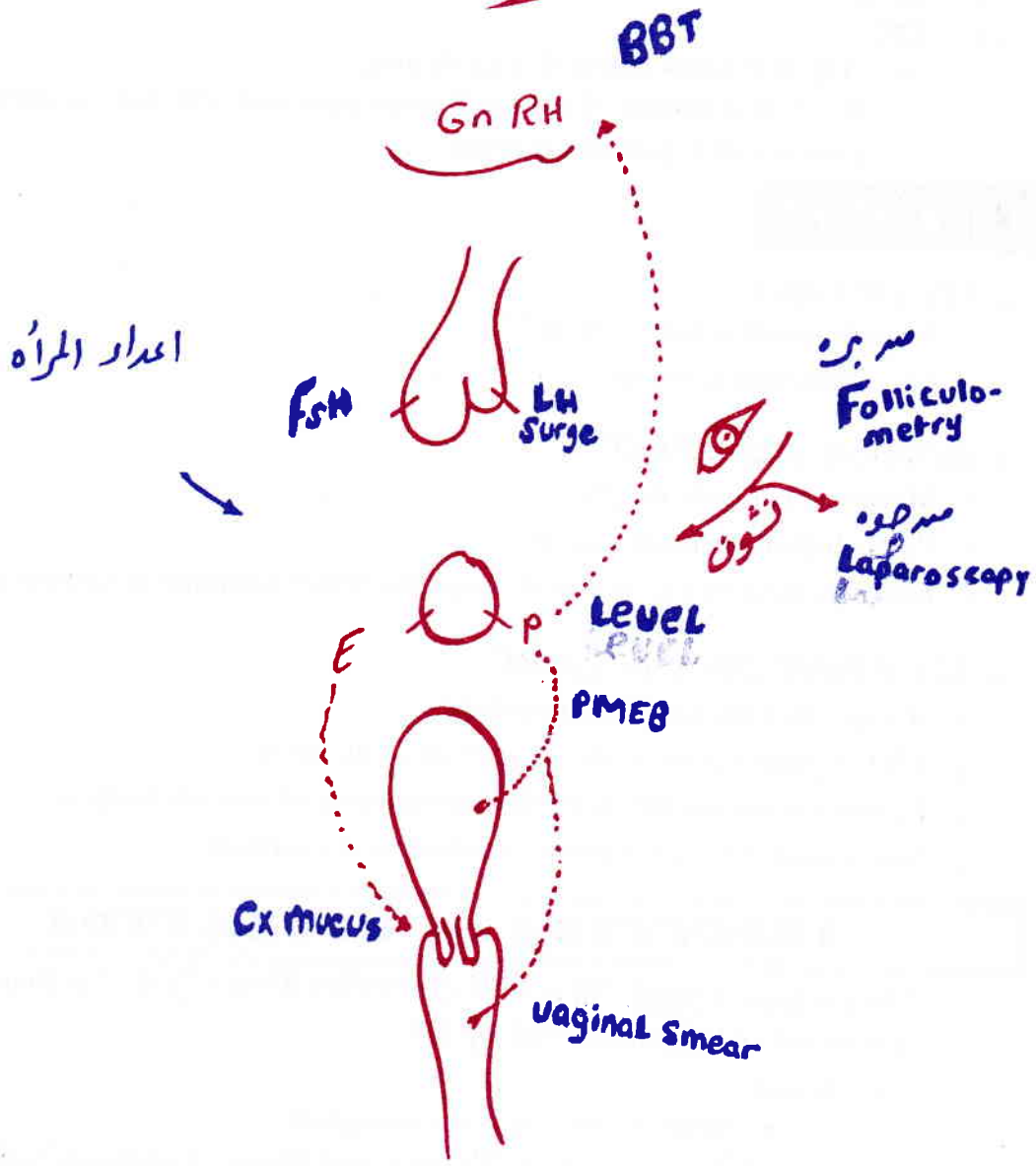

B) TO KNOW THE CAUSE:

8. **Progesterone challenge test**
9. **Serum prolactin: -** "normally 2 – 20 ng /ml
10. **T3, T4, TSH**
11. **Androgen level** "0.2 – 0.8 ng/ml"
12. **Adult onset of CAH** → 17 OH progesterone & DHEA (treatment → steroids)
13. **FSH**
    - If ↑ → **ovarian cause** → Karyotyping
    - If ↓ → **H-P failure** → do GnRH stimulation test, CT, MRI to differentiate pituitary or hypothalamic cause

TREATMENT

PROPHYLAXIS

- Early detection & treatment of PID
- Good treatment of mumps

GENERAL TREATMENT

- Modulation of body weight
- Psychological & social support
- Stoppage of smoking, alcohol & drugs that affect ovulation or spermatogenesis

TREATMENT OF THE CAUSE:

- Hyperprolactinemia → **Bromocriptin**
- LPD → progesterone in the second half of the cycle
- Resistant ovary syndrome → HRT till regaining of ovarian function
- Anovulation & LUF syndrome → induction of ovulation.

INDUCTION OF OVULATION

1- **Clomiphene Citrate** 50 mg OR Tamoxifen 10 mg/12 h (if > 5 y → *endometrial carcinoma*) OR Cyclofenil 100 mg/12 h

- **Action**
  - Synthetic nonsteroidal anti estrogen®
  - Blocks -ve feedback of E on hypothalamus → increased GnRH & FSH & follicular development (Needs intact H-P-ovarian axis)
- **Mode of administration**
  - 1x2x5 from 2nd or 3rd day of the cycle & for 5 days
  - In amenorrhea, give P → withdrawal bleeding → then start
- **Monitor response**
  - by **ultrasound** or **Basal bady Temperature** or **progesterone**

Induction of ovulation:

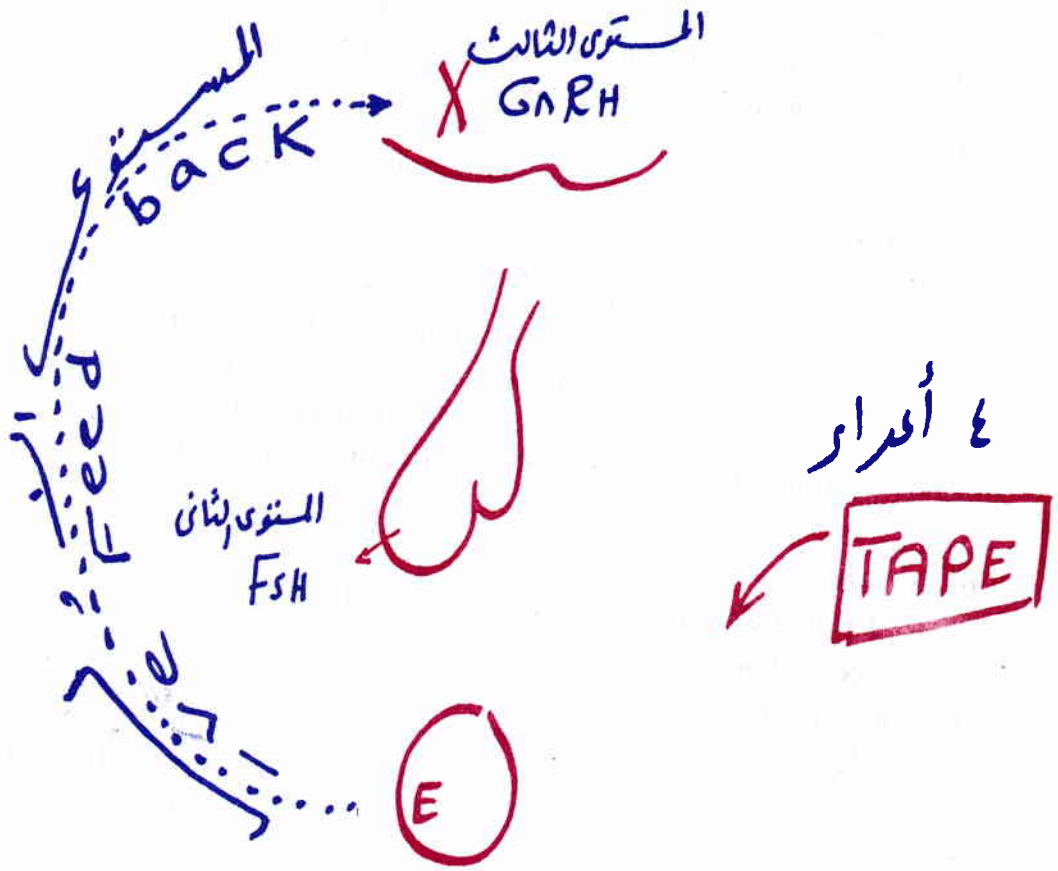

- **Management of failure of Clomiphene therapy**
  - Increase the dose up to 5 tab/day (250mg/d)
  - Clomiphene with other medications:
    - With HCG.
    - With Dexamethazone 0.5 mg, at bedtime.
    - With Bromocriptin
    - **May also use insulin sensitizers (metformin)**
    - Gonadotrophin therapy.
    - With Naltrexone (opioid receptor blocker)....25mg twice daily
- **Induction of ovulation occurs in 80% of cases.**
- **Conception occurs in 40% of cases**
- **To increase conception rate**
  - **Estrogen** to improve cervical mucus.(low dose E from 8th to 14th d)
  - **HCG.**
- **Side effects of Clomiphene**
  - Multiple, pregnancy: 5- 10% increase.
  - Ovarian hyperstimulation syndrome (OHS) is rare.
  - Hot flushes & dry vagina (anti-estrogenic effect)
  - Abdominal bloating (feel of distension) & breast discomfort.
  - Subjective visual disturbance (mydriatic effect).

2- Clomiphen + HCG:

- **Preparation:**
  - Pregnant urine: pregnyl, profasi (IM)
  - Recombinant: ovidrel (SC)
- **Action:** acts like LH
- **Dose:** Give HCG 5000 – 10.000 units /IM when Follicle is mature by ultrasound (**17-20mm**), intercourse on same & next day of injection

3- Gonadotrophins therapy

- **Indications:**
  - Hypothalamic-Pituitary Failure.
  - Polycystic ovarian disease not responding to Clomiphene.
  - Super ovulation in assisted reproduction.
  - unexplained infertility
  - LPD, Hostile cx mucus (it ↑ quantity & quality of cervical mucus)
  - In male for oligospermia and cryptorchidism
- **Preparations:**
  - FSH 75-150 1U & 75 1U LH → Humegon or Pergonal or Menogon
  - FSH 150 IU & LH < 1 IU: metrodine
  - Recombinant FSH only: Puregon or Gonal F: better in PCO patients

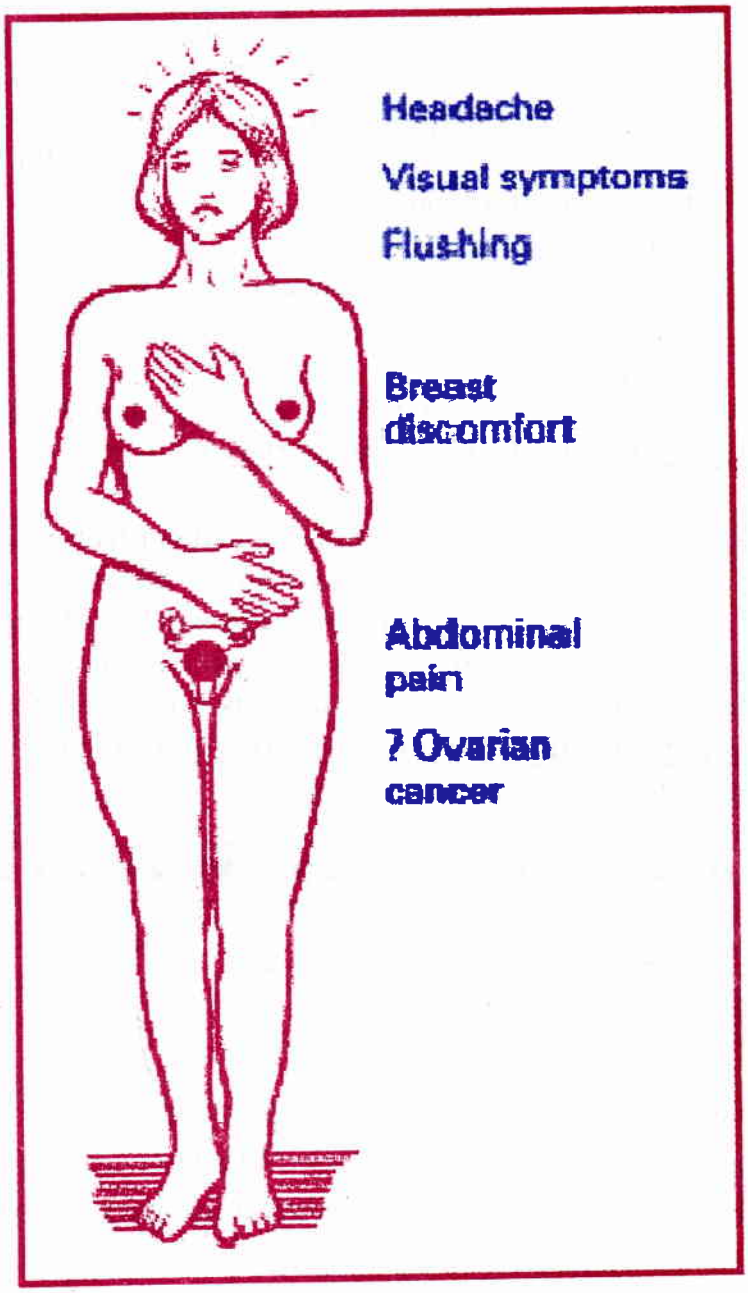

Complications of Cloniphere Citrate

- **Administration of FSH Preparation:**
  - 1-2 ampoules IM/day start on 3rd day of cycle.
  - Measure response by Ultrasound or estrogen level.
  - If unsatisfactory response, ↑ dose by 1 ampoule/day every 4-7 days.
  - Maturation of follicle: follicle is 17-27 mm or E2 is 200-300 pg/ml/ follicle → 1000-1500 pg/ml (not given if > 2000 to avoid OHSS)
  - When follicle is mature, give HCG 5000- /10000 IU IM.
- **Side effects of FSH preparations:**
  - Multiple gestations: 10-15 %
  - Ovarian hyperstimulation syndrome (OHS) 2%
  - Abortions and preterm delivery 15—30%.
  - Ectopic pregnancy 3%.
- **Success rate after 6m** → 50-90% (in properly selected pts)

4- **Clomiphene then FSH preparations then HCG**

5- **GnRH**
- **Indications (mainly in resistant cases without fear of OHSS)**
  - In hypothalamic disease, but difficult & expensive.
  - Every 90 minutes via computerized pump for 2-4 weeks.
  - Monitoring. (The risk of ovarian hyperstimulation is nearly absent).

6- **In Hyperprolactinemia**: Bromocriptine/ Lisuride/ quinagolide/ cabergoline.

7- **Treat hypothyroidism & increased adrenal activity**

8- **Surgical induction** as ovarian drilling

2- TUBAL (20%) & PERITONEAL FACTORS

Commonest cause of 2ry infertility

CAUSES

- **Aplasia**
- **Surgical trauma** as in ectopic pregnancy or tuboplasty
- **Infection** (gonorrhea, Chlamydia اهم سبب, fibroids)
- **Miscellaneous** (as spasm or salpingitis isthmica nodosum, endometriosis, pelvic adhesion, ovarian encapsulation, PG luteolysis)
- **Pelvic causes:** adhesions preventing ovum transport as in endometriosis (10 – 25% of infertility) or surgery or PID.

CLINICAL PICTURE

- History of surgery,
- Symptoms of infections (abdominal pain, discharge)
- Signs: tenderness, scars of previous operations

تذكر دائماً أن اسباب

tubal infertility

هم اسباب Ectopic Preg

بس هناك Complete obstruction

دي كلمة بس

INVESTIGATIONS

1. Hysterosalpingogram سؤال نظري لوحده:

- **Timing**:
  - Day 6 – 11 = 2- 5 days postmenstrual
  - it is done Postmenstrual to avoid
    - Embolism, endometriosis,
    - Disturbing a possible pregnancy
    - False +ve results (by thick endometrium → apparent tubal block)
- **Indications**:
  - Infertility,
  - Preoperative (as myomectomy)
  - Postoperative (after salpingoplasty or myomectomy)
- **Contraindications**:
  - Pregnancy or amenorrhea of unknown etiology, Premenstrual.
  - Post infections **(flaring)** or Post curettage **(Embolism, endometriosis)**
- **Uses in infertility:**

1- **Evaluate tubal factor of infertility**:
  - HSG reveal tubal patency versus occlusion
  - In case of occlusion,
    - It clarifies the site of tubal obstruction,
    - Hydrosalpinx, and Salpingitis isthmica nodosa (SIN).
    - Peritubal & pelvic adhesions.

2- **Evaluate peritoneal factor of infertility**:
  - HSG reveals the normal peritoneal spill of the dye (after 24 hours)
  - The delayed film shows pelvic adhesions (peritubal adhesions).

3- **Evaluate uterine factors of infertility**:
  - It reveals the size, shape, & position of the uterus:
  - It shows intrauterine adhesions, malformations, polyps & fibroids,

4- **Occasionally it has a curative value**:
  - It clears the tubal lumens of mucus
  - It relieves uterotubal spasm.

- **Drawbacks of HSG:**

1- It is not as accurate as laparoscopy.
2- It has **high false positive** rate because of transient tubal blockages induced by smooth muscle spasm.
3- It also **has a false-negative** rate as in stenosed tube or intravasation.
4- **Complications** as
  - Oil embolism or oil granuloma.
  - Iodine allergy

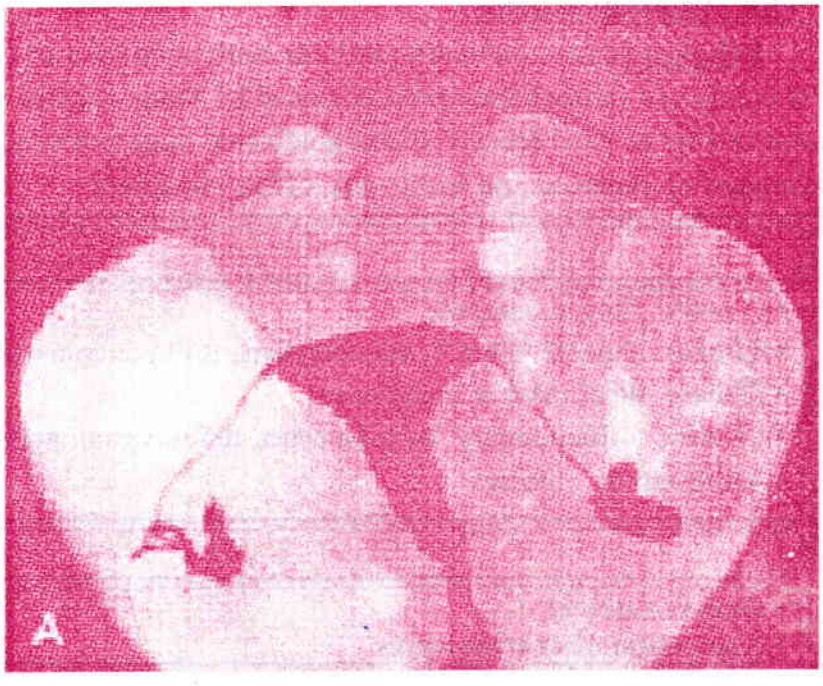

Bilateral Hydrosalpinx

Lipidol	Urograffin
• 40% iodide in poppy seed oil زيت بذره الخشخاش • More clear image • More complications (oil granuloma & oil embolism) • 2nd film after 1 day	• 40%iodide in water • less clear image • less complications • 2nd film after 1 hour

2. Hysterosalpingo contrast-sonography (HYCOSY):

- **Method:**
  - The substance used:
    - **Echovist** (galactose micro particles containing micro bubbles)
  - It is injected through the cervix & traced by Trans vaginal U/S.
- It shows uterine & tubal lesions. (Contraindicated in galactosemia)
- **Advantages**: no radiation, no anesthesia, office procedure

USES OF US IN INFERTILITY	
	Diagnostic:
	▪ Cervix: fibroid, masses ▪ Uterus: Tumors, fibroid, adenomyosis, RVF, endometrial thickness ▪ Tubes: tubal mass & complexes. ▪ Ovary: folliculometry, ovarian cysts, tubo-ovarian masses. ▪ Peritoneum: masses
	Therapeutic
	▪ Oocyte retrival ▪ Aspiration of ovarian cysts.

3. Laparoscopy:

- **The dye used:**
  - **Methylene blue ®** → for tubal patency
- **Advantages**: diagnostic & therapeutic

	DIAGNOSTIC	THERAPEUTIC
Tubes	▪ Tubal block (confirm HSG) ▪ Salpingoscopy	▪ Salpingolysis ▪ Salpinostomy
Ovary	▪ PCO ▪ Ovarian swelling	▪ Ovarian drilling in PCO, ▪ ovarian cystectomy
Endometriosis	▪ Diagnosis & classification of endometriosis	▪ Cauterization of implants ▪ dissection of adhesion
Others	▪ assessment of unexplained infertility	▪ ovum pick up in IVF

4. Hysteroscopy & tubal cornual cannulation:

- For proximal tubal block as known by HSG or laparoscopy.
- **Types:**
  - **Transcervical tubal cannulation**
    - Pass a catheter through the corneal end
    - It can treat a ***non organic*** tubal obstruction (mucus plugs)
    - Advantage:
      - **DIAGNOSTIC**: selective diagnosis of cornual obstruction
      - **THERAPEUTIC**:
        - It can bypass tubal spasm
        - Thickened endometrium
        - Thick intratubal plugs
  - **Transcervical balloon dilatation :** for ***organic*** tubal obstruction

USE OF HYSTEROSCOPY IN INFERTILITY		
	THERAPEUTIC	DIAGNOSTIC
Tubes	▪ Trans cervical cannulation ▪ Transcervical balloon dilatation	▪ falloposcopy ▪ proximal tubal block
Uterus	▪ dissection of adhesion ▪ Removal of masses or tumors.	▪ adhesion, fibroid, tumors, ▪ premenstrual end. biopsy
Cervix	▪ removal of cx polyps & masses	▪ Masses, stenosis, polyps

5. Tuboscopy:

- **Salpingoscopy** transabdominal visualization of the tube (through laparoscopy)
- **Falloposcopy** transcervical endoscopy of the tube (through hysteroscopy)
- **S.E** → perforation of the tube

6. Tubal insufflations (Rubin `s test >> old) &

Chymography (on rotating drum, Co2 is used instead of air)

حاجات قديمه لا تذكرها الا لو سالت عنها

- **Criteria of patent tubes:**
  - Persistent low intrauterine pressure
  - Hissing sound in the iliac fossa
  - Right shoulder pain
  - Air under the diaphragm in X ray abdomen

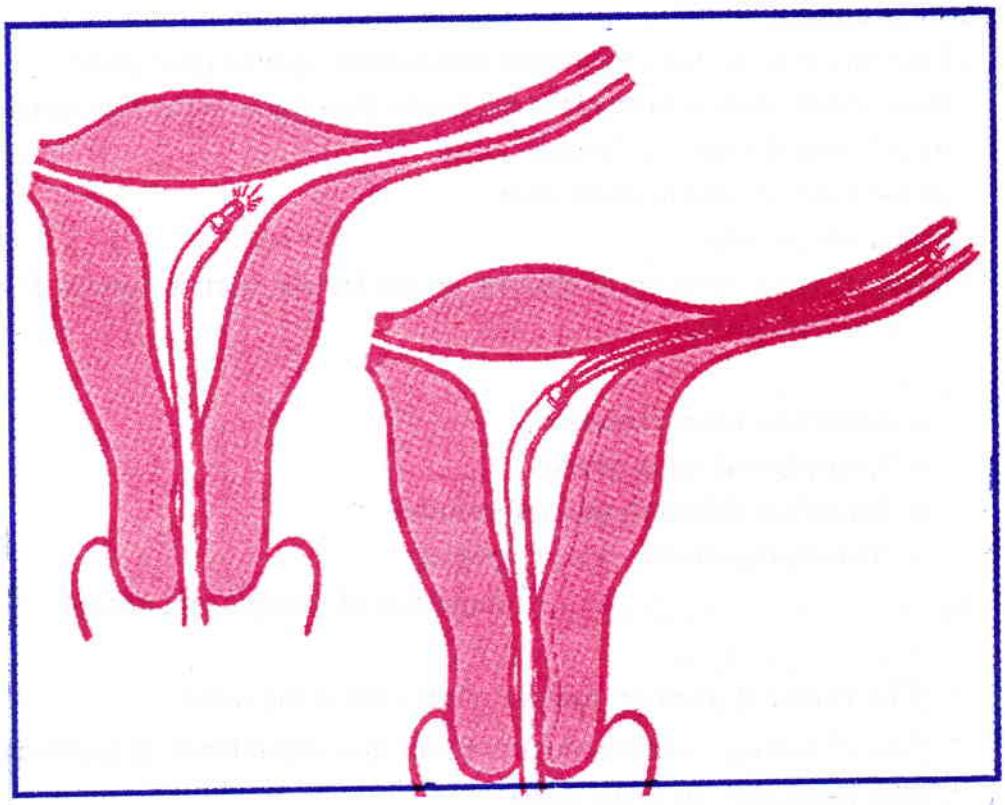

Tubal cannulation

TREATMENT

- **TREATMENT OF THE CAUSE**

- **TUBOPLASTY (SUCCESS RATE 10-40%)** علاج قديم
  - **By laparoscopy (better) or laparotomy.**
  - **Precaution on performing microsurgery:**
    - Wide incision
    - Fine suture & special instruments (binoculars, special glass rods)
    - Hemostasis: laser is better than diathermy (bipolar is better than monopolar)
    - Avoid serosal injury & dryness
    - Avoid excess tissue manipulation
    - Avoid talc powder
    - Intraperitoneal infusion of dextran, ringer lactate, corticosteroids & heparin → to ↓ adhesions
  - **Forms:**
    - **Resection reanastomosis**
    - **Reimplantation in uterus**
    - **Peritubal adhesiolysis** (best results)
    - **Neosalpingostomy** → new opening
  - **Restore anatomy not function** (↑ incidence of ectopic pregnancy)
  - **Prognosis depends on:**
    1- *The extent of damage*: damage of the cilia is the worst
    2- *Site of damage*: isthmic block is better than distal block & hydrosalpinx.
    3- *The pathogen*: TB is the worst

- **TRANSCERVICAL CANNULATION** (in functional obstruction) & **TRANSCERVICAL BALLOON DILATATION** (in organic cause)

- **ASSISTED REPRODUCTIVE TECHNIQUES** هو العلاج الحديث

- **OLD METHODS** لا تذكر ابدا **→HYDROTUBATION:** **by chemotrypsin + streptomycin + hydrocortisone**

- **TREATMENT OF PERITONEAL FACTORS:**
  - Remove any gross pathology
  - Treatment of endometriosis then induction of ovulation.

3- CERVICAL FACTORS (5%)

CAUSES

- **Congenital:** Artesia
- **Traumatic:** Amputation, Conization
- **Inflammatory:** Cervcitis
- **Neoplastic:** Fibroid
- **Miscellaneous:** hostile cervical mucus (antibodies, ↓ estrogen, infection).

CLINICAL PICTURE

- **History:** of the cause.
- **Signs:** trauma, deformities.

INVESTIGATION

1. **Cervical mucus assessment "just pre-ovulatory"**
   - **Quantity:** 0.3 ml
   - **Quality:**
     - Runny clear
     - +ve **fern** & **Spinnbarkeit** test
     - **WBCS** are 0-1/HPF
2. **Post coital test (Sims-Huhner test)**
   - **Male** → semen analysis must be normal + abstinence from SI for 2 – 3 d
   - **Female** → just pre-ovulatory "known by folliculometry → 20 mm"
   - **Aspiration of cervical mucous** 2 – 12 h after intercourse (by tuberculin needle or pipelle)
   - **Normally** → Number of sperms > 20 motile/HPF
   - **Cx mucus assessment (as above) each take (0,1,2,3)** → **Moghissi scoring:**
     - **11 – 15** → favorable
     - **5 – 10** → unfavorable
     - **<5** → poor
   - **Causes of abnormalities:-**
     - Bad cervical mucus
     - ↓Number of sperms or dead
     - infection with leucocytosis
     - immunological → shaking movement of sperms
     - improper timing or technique
     - Coital factors: dyspareunia, impotence, premature ejaculation
   - **Management:** → repeat semen analysis, cervical mucous assessment & PCT

Q:What is the fractional PCT?

- Sim-Huhner PCT can differentiate between CX & vaginal hostility

Voginal pool examination	Cervical pool examination	Interpretation
No sperms	No sperms	Azospermia or deposition faliure
All dead	No sperms	Vaginal hostility (acidity or infection)
Living motile	Dead	Cervical hostility
Living motile	Living	Normal (give score)

3. **Cx mucus contact test "in-vitro PCT"** can be performed in test tube or on slide
   - **Indication**
     - ⇨ When in vivo PCT is -ve
   - **Types**
     - ⇨ **Slide test (Miller-Kurzok الاسماء مهمه للازهر):**
       - A drop of cx mucus just preovulatory + drop of donor healthy semen → detect abnormalities in mucus
       - A drop of donor healthy cervical mucus just preovulatory + drop of semen → detect abnormalities in semen
     - ⇨ **Capillary tube test (Kremer الاسماء مهمه للازهر):**
       - Semen is present in a reservoir & cx mucus is sucked in a Capillary Tube which is Ex microscopically for sperms after 30-60-120-180 min
   - **Normally**
     - ⇨ Forward progression of sperms penetrating the cervical mucus
4. **Cervical mucus culture** in infection
5. **Mixed agglutination reactions** to detect immunological infertility

TREATMENT

- ♣ Treatment of the cause
  - ⇨ **If thick** → give estrogen (0.625 mg at days 8 -13)
  - ⇨ **Infections** → give antibiotics
- ♣ Immunological: Corticosteroids كلام فارغ, condoms كلام فارغ or AIH الحل

4- UTERINE FACTORS تاليف

CAUSES

- ♣ CTINM

INVESTIGATION

- ♣ U/S, hysteroscopy, hysterosalpingiography

TREATMENT

- ♣ TREATMENT of the cause

5- VAGINAL FACTORS:

CAUSES

- CTINM

INVESTIGATION

- Smear & C&S in infections

TREATMENT

- Treatment of the cause

6- IMMUNOLOGICAL FACTORS

- **Male autoantibodies** after surgery on the genital tract
- **Female antibodies:**
  - **IgM (large in serum only):** against blastocyst preventing implantation
  - **IgG (small in serum & cervical mucus):** against the sperm.
- **Antibodies are either:**
  - **Agglutinating:** head to head, head to tail & tail to tail.
  - **Immobilizing:** rotatory (against head) or shaking movement (against tail)

II. COITAL FACTOR

- **Too frequent or too infrequent (best every other day)**
  - DECREASE FREQUENCY → Decrease chance of conception
  - INCREASE FREQUENCY → produce immature & ↓ count of sperms
- **Coital difficulties:**
  - Vaginismus, dyspareunia, impotence
  - Anorgasmia, orgasm is important to:
    - Relieve uterotubal spasm
    - Increase vaginal secretions → ↓ vaginal acidity
- **Effluvium semenis** كلام فارغ
  - Escape of seminal plasma from vagina after intercourse (occurs normally)
  - Has no effect
- **Post coital douches or use of lubricants:**
  - Kill sperms.

Types of sperm agglutination

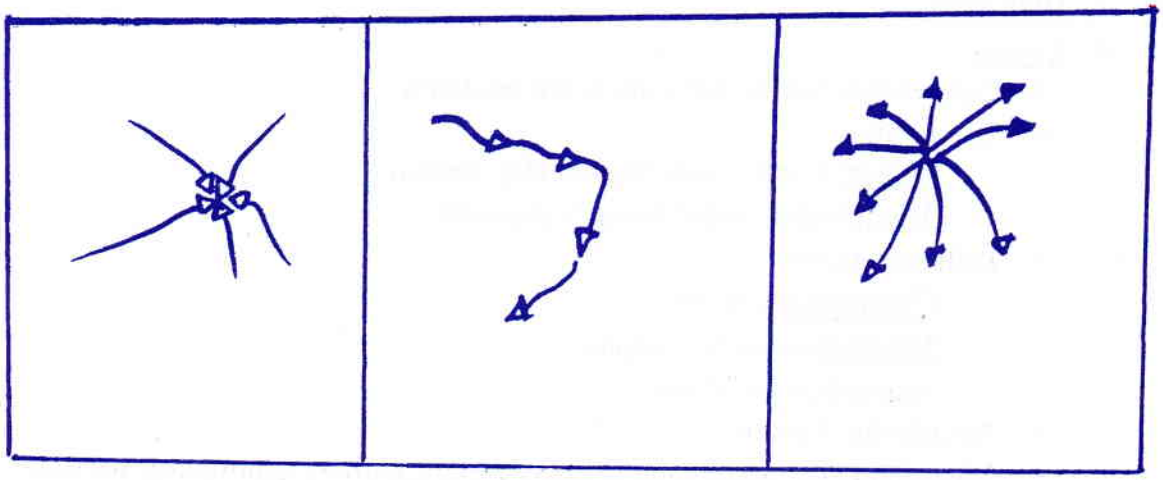

head to head | head to tail | tail to tail

III. MALE FACTORS

CAUSES دي أحسن تقسيمه

The commonest cause is infections (Chlamydia & gonorrhea)

- **PRE-TESTICULAR:**
  - Low FSH
  - Causes
    - Hypothalamic pituitary lesions (CTINM)
- **TESTICULAR:**
  - High FSH
  - Causes
    - **Congenital:** Sertoli cell only $, Klinefelter $
    - **Traumatic:**
      - **Direct:** compression (Hydrocele), torsion
      - **Heat:** Undescended testis, Varicocele
    - **Inflammatory:**
      - **Chlamydia:** ↓motility
      - **Mumps:** testicular atrophy
      - **Syphilis** damage of testis
    - **Neoplastic:** Tumors
    - **Miscellaneous:** occupation in heavy metals, chronic debilitating diseases.
- **POST-TESTICULAR:**
  - Normal FSH
  - Causes:
    - **Congenital:** Absence of vas, cystic fibrosis, Kartagener syndrome, hypo or epispadius
    - **Traumatic:** pelvic, hernial & scrotal operations
    - **Inflammatory:** Chronic Non specific prostatitis (damage of motility & morphology), Funiculitis.
    - **Neoplastic:** tumors of epididymis or prostate
    - **Miscellaneous:**
      - **Diseases:** DM, deblitating diseases
      - **Drugs:**
        - Anti HTN→Impotence.
        - Anticancerous→↓ Spermatogenesis
      - **Faliure of deposition of sperms:**
        - **Anatomical:** hypo or epispadius
        - **psychological :** impotence & premature ejaculation

- **Retrograde ejaculation :** due to DM, transurethral resection of prostate, trauma to spermatic cord → known by urine analysis.

CLINICAL PICTURE

- **History of the cause**, Impotence
- **Signs:** general signs of Klinefelter, hypo or epispadius, ↓testicular size

INVESTIGATIONS

1. Semen analysis حفظ اكتر من اسمك:

- **Precautions:**
  - 2-3 days abstinence,
  - done in 2 different labs
  - Collection in the lab by masturbation or at home by special condoms.
  - Transported in a sterile container of a non toxic plastic
  - If abnormal → repeat 72 days after treatment
- **Norma criteria (WHO):** → Semenogram
  (Abnormalities → Oligo – Terato – Asthenospermia (OTA) System)
  - **Macroscopically:**
    - **Volume:** 2-6 ml
      - NONE → aspermia (no semen)
      - LARGE VOLUME → treat by split ejaculation or AIH الحل الاحسن
    - **Color:** whitish
    - **Odor:** characteristic odour.
    - **pH:** 7.4-8
    - **Liquefaction** after ½ hr
  - **Microscopically:**
    - **Count: 20 millions/ml**
      - **Azoospermia**: semen + no sperms (obstructive or productive)
      - **Oligospermia**:
        - < 20 million/ml (usually cause infertility)
        - **Treatment**: induction of spermatogenesis or AIH or ART
      - **Polyspermia**:
        - > 250 millions
        - Interfere with nutrition → weak sperms
    - **Normal forms: >30%** (increase in teratospermia)
    - **Motility: > 50% within 1 h**
      - ↓ in **asthenospermia**: due to infections or immunological.
      - Absent in **necrospermia**: due to infections as prostatitis
    - **Pus cell: 0-1/HPF** (pyospermia in infection)

2. **Analysis of seminal plasma:**
   - ⇨ **FRUCTOSE** (function of seminal vesicles)
   - ⇨ **ZN, URIC ACID, PG** (function of prostate)
   - ⇨ **GLUCOSIDASE** (function of epididymis)
3. **Post ejaculatory urine sample** →(In retrograde ejaculation as in DM)
4. **Test for sperm function:** As zona pellucida penetration test(Hemi zone test)
5. **Hormonal assay** (prolactin , thyroid , FSH)
6. **In azospermia:**
   - ⇨ **Testicular biopsy:**
     - ✱ **Types:**
       - Testicular extraction (**TESE**)
       - testicular aspiration (**TESA**)
       - Percutaneous epididymal sperm aspiration (**PESA**)
       - Microsurgical epididymal sperm aspiration (**MESA**)
     - ✱ **Results:**
       - ★ **If no sperms** → karyotyping
       - ★ **If sperms are present** → vasography (determine the site of obstruction) مش بتتعمل الان
7. **Mixed agglutination reactions** for detection of immunological infertility

TREATMENT مش مهم

♣ **Treatment of the cause :**

- ♦ **CHRONIC PROSTATITIS**: antibiotics according to C&S for long time
- ♦ **PERSISTENT LOW SPERM COUNT**: clomiphene 25mg/d for 25days + mucolytic
- ♦ **GONADOTROPHINS**: if FSH is low
- ♦ **TESTOSTERONE**: 200 mg/week for 20 weeks: they suppress spermatogenesis temporarily. On cessation there is a rebound increase in sperm count.
- ♦ **HYPERPROLATINEMIA** → bromocriptin
- ♦ **VARICOCELE**: surgery
- ♦ **IMPOTENCE, PREMATURE EJACULATION**: AIH (AID حرام)
- ♦ **OLIGOSPERMIA**: TESA, MESA → ICSI
- ♦ **VITAMINS**: Vitamin C & Tonics

♣ **AIH or ART**

♣ **In retrograde ejaculation:**

- ⇨ Alkalinization of urine
- ⇨ Centrifugation of urine to get sperm
- ⇨ AIH

IV. UNEXPLAINED INFERTILITY

- **DEFINITION:**
  - The couple ***anatomy*** & ***function*** appears to the normal.
- **THE KNOWN CAUSES OF INFERTILITY ARE EXCLUDED:**
  - Normal **ovulation** (folliculometry),
  - Normal **uterus** (normal hysteroscopy),
  - Normal **tubes** (normal HSG or laporoscopy),
  - Normal **semen analysis** (done twice at least),
  - Normal **post coital test**.
- **INCIDENCE:** 5%
- **POSSIBLE CAUSES:**
  - **ENDOMETRIOSIS**: 75% may be early mild cases (asymptomatic)
  - Immunological disorders
  - Subclinical inf ecrions (Chlamydia, mycoplasma hominis, TB, Bilharziasis)
  - Early pregnancy loss, genetic abnormalities & linical hypothyrodism
  - Sperm dysfunction: inability of sperm to attach or penetrate ZP
  - Some psychological factors: anexity >>> uterotubal spasm
  - Improper history taking: as use of lubricants & vag. Douche
  - LPD
  - LUFS
  - Hyperprolactinemia
- **INVESTIGATION:**
  - **LAPAROSCOPY** (1st step مهم جداً جداً),
  - Test for immunological factors, infection,
  - Sperm function tests.
  - If all tests are normal→ **IDIOPATHIC INEFRTILITY**.
- **TREATMENT:**
  1- If there is a cause→treat.
  2- If not→**EMPIRICAL** treatment.
     a. Induction of ovulation.
     b. Antibiotics for chlamydia &mycoplasma (Azithromycin, Doxycycline)
     c. AIH.
     d. **ART**. مهم جداً

ASSESSMENT OF A CASE OF INFERTILITY

Always remember male evaluation *semen analysis are done FIRST

Assessment of the male

HISTORY:

Personal

- **AGE** → ↓ testicular function with age but no ♂ menopause.
- **ADDRESS** → Bilharziasis → obstruction of vas or epididymis.
- **OCCUPATION**: Bakers, farmer, exposure to lead, irradiation.
- **SPECIAL HABBITS**: smoking, marijuana (impotence).
- **PREVIOUS MARRIAGE** & if has children.

C/O: any genital or urological problems.

Past history: drugs, diseases, surgery (pelvic, hernia, urinary, genital, CNS)

EXAMINATION:

- Klinefelter, hypospadius, decrease testicular size
- Gynecomastia, and thyroid abnormalities.

INVESTIGATIONS & TREATMENT : LOOK BEFORE

Assessment of the female

HISTORY

Personal history:

- **Age:** very young or very old age; ovarian factors.
- **Marital status:** to determine the period of infertility &if pervious marriage.
- **Parity:** 1ry or 2ry infertility.
- **Address:** for endemic diseases as Bilharziasis.
- **Occupation:** irradiation, heavy metals.

C/O:

- Faliure of contraception +/- menstrual irregularities
- Galactorrhea +/- virilization.

Menstual history

- **Menarche** if delayed menarche→ovarian cause.
- **D&C** for any irregularity.

⇨ **Personal history:**

- Amenorrhea, bleeding, discharge, masses, pain,
- **Investigations** done.
- **Treatment** received.

⇨ **Past history:**

- **Medical**: TB, DM, HTN, fever.
- **Surgical**: CS, D&C.

⇨ **Family history:** DM, TB.

⇨ **Sexual history**

EXAMINATION :

⇨ **General Ex:**

- Weight, height, galctorrhea, increase androgen, thyroid dysfunction.

⇨ **Specific finding suggestive of each factor :**

INV, TREATMENT : LOOK BEFORE.

OTHER LINES OF TREATMENT

1. AIH

♣ Assisted insemination of husband semen (0.3 - 0.8 ml) into the female genital tract **intra cervical** or **intravaginal** (can use raw semen) or **intrauterine** use processed semen (**washing or swimming up method**) to avoid anaphylaxis by semen proteins

♣ ± Induction of ovulation & ± HCG

♣ AIH done **twice** 18 & 42 hours after HCG injection

INDICATIONS :

⇨ **Poor semen quality** (assisted insemination of donor semen can be done but unethical)

⇨ **Immunological** (also cervical hostility)

⇨ **Unexplained in fertility**

⇨ **Coital difficulties**

PREPARING THE SEMEN TRANSFERRED :-

⇨ **↓PG content** as it leads to uterine cramps & expulsion of the semen

⇨ **In pyospermia** centrifuge & add specific antibiotics

⇨ **In asthenospermia** Add pentoxiphylline, kallikerines , & caffeine

⇨ **In high viscosity** Add chemotrypsin

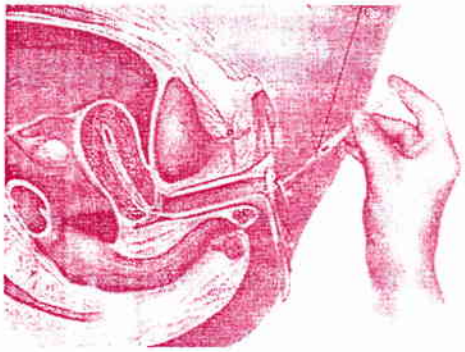

INTRAUTERINE INSEMINATION

Indications of AIH & ART

المشترك بينهم

- ♂ infertility
- Immunologic
- Unexplained

AIH

Coital

ART



- Ovum donation
- Surrogate mother

حرام

2 - ASSISTED REPRODUCTIVE TECHNOLOGIES (ART)

INDICATIONS :

1. **Male infertility**: in oligospermia, low motility, ↑ abnormal forms, few thousands are needed in IVF (50.000 sperms at least are needed to fertilized one oocyte)
2. **Ovarian factor**: absent ovaries, streaked ovaries, failed induction of ovulation, donated ova & husband semen (not accepted in moslim communities)
3. **Tubal factor**: absent tubes, bilateral irreparable tubal disease
4. **Peritoneal factors**: dense adhesion e.g endometriosis
5. **Uterine factor**: absent or diseased uterus in the presence of normal ovaries, the embryo is transferred to a surrogate mother, not accepted in moslim communities
6. **Immunological cause**
7. **Unexplained infertility**

SUPEROVULATION :

1. **MEDICAL HYPOPHYSECTOMY** by GnRH agonist intra nasally (Buserlin) at day 20.
2. **HMG** or **PURIFIED FSH** (metrodine) **10 days after** GnRH till the ova reaches 17 ml.
3. **HCG IS given** when the **ova reaches 20 ml** → ovulation usually occurs after 36 hr.
4. **RETRIEVAL of 13 - I5 oocytes** just preovulatory **(guided by TVUS or laparoscopy)**
5. **SEMEN** is transferred in a culture media (**Ham's F10, Tyrode's or Earl's medium)**
6. If the **GAMETES** are transferred to the tube → **GIFT** (gamete intrafallopian transfer)
7. If the **ZYGOTES** is transferred to the tube → **ZIFT** (zygote intrafallopian transfer)
8. If the **ZYGOTES** is cultured for 2 days (4 - 8 cells) then transferred to the uterus
   - in vitro fertilizahon enbryo transfer
   - →**IVF-ET** without anesthesia to the fundus of the uterus.

THE REMAINING EMBRYOS ARE FROZEN (CRYOPRESERVATION) FOR LATER USE IN THE SAME WOMAN, FOR PGD (PRE-IMPLANTATIOM genetic diagnoris)

9. **MICROINJECTION OF 1 SPERM** in the cytoplasm of a metaphase II oocyte → **ICSI**
   - **Indications:** failure of IVF trial (3 times), marked oligo/ asthenospermia.

Technique of ART

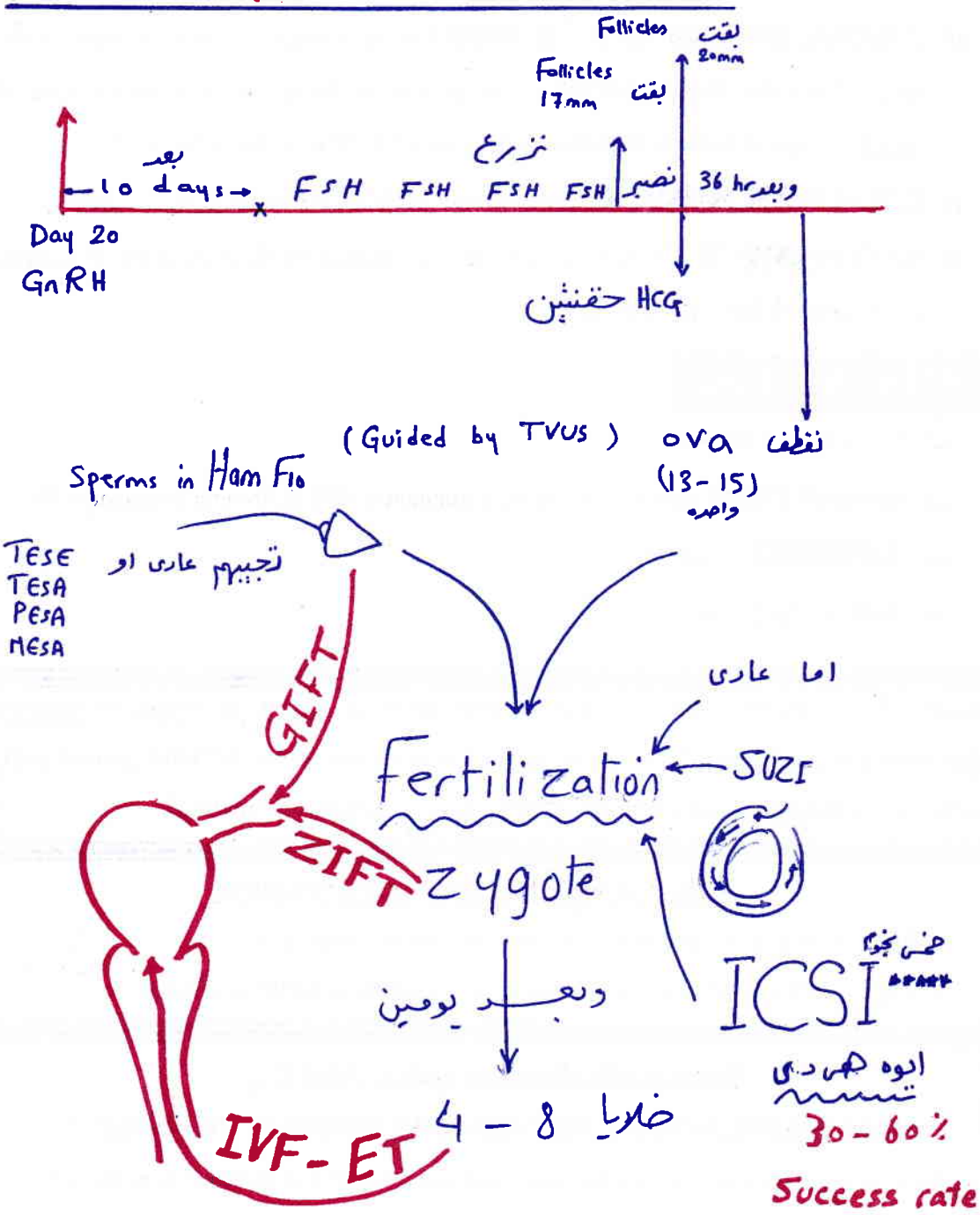

luteal phase Support ولا تنس بعد ذلك

- It is the most commonly done, success rate is 30-60% pregnancy in 25%

10. **SUBZONAL INSERTION OF 5 - 10 SPERMS** by microinjection into the perivitteline space of oocytes then transferral of the embryo to the uterus or Fallopian tube → **SUZI** (↑ triploid embryo & success rate is only 15-30%, replaced by ICSI)
11. **LUTEAL PHASE SUPPORT BY** progesterone or HCG(5000-10000 IU/2-3 days)
12. **SUCCESS RATE:** 20 - 30 % when the age is 25 years& 10 % at 40 years. It is better to be repeated for 3 or 4 cycles.

DEPENDING UPON:

- Underlying **CAUSES**
- **Number OF ZYGOTE** transferred (multiple pregnancy 35% & Ectopic Pregnancy 3%)
- **EXPERIENCE** of the team
- **AGE** of the female

Some ART procedures are unethical & unreligious as **sperm** or **ovum** or **embryo donation** and **surrogacy** (a surrogate mother donates her uterus for fetal growth until delivery). **Cloning** (asexual reproduction) is also unreligious & unethical.

How to predict the poor ovarian response:

1- **age**: > 40 y, presence of single ovary or ovarian volume < 3 cm

2- Day 3 FSH is > 25 u/l, low inhibin & low Mullerian inhibitory factor

Prophylactic Measures against Infertility

THESE INCLUDE AVOIDING ALL FACTORS MENTIONED IN THE ETIOLOGY,

1- Prevention and treatment of genitourinary infections whether in the male or in the female

2- Avoid agents that are toxic to spermatogenesis

3- Mumps: Immunoglobulin and corticosteroid as prophylactic against testicular atrophy

	IVF-ET	GIFT	ZIFT	ICSI	SUZI
Indications	General	General – tubal factors		General + weak sperms	

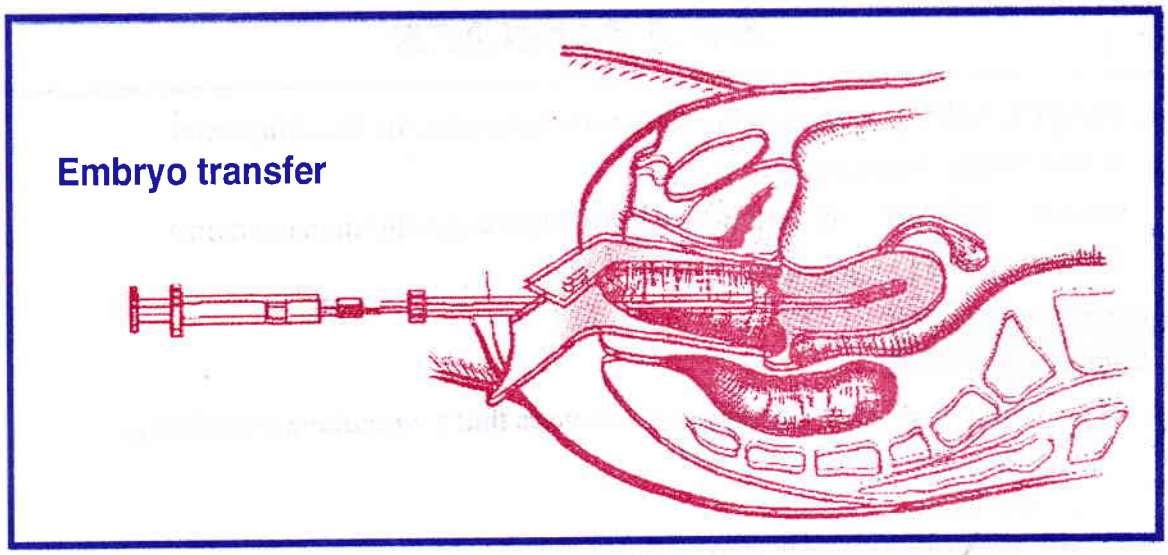
Embryo transfer

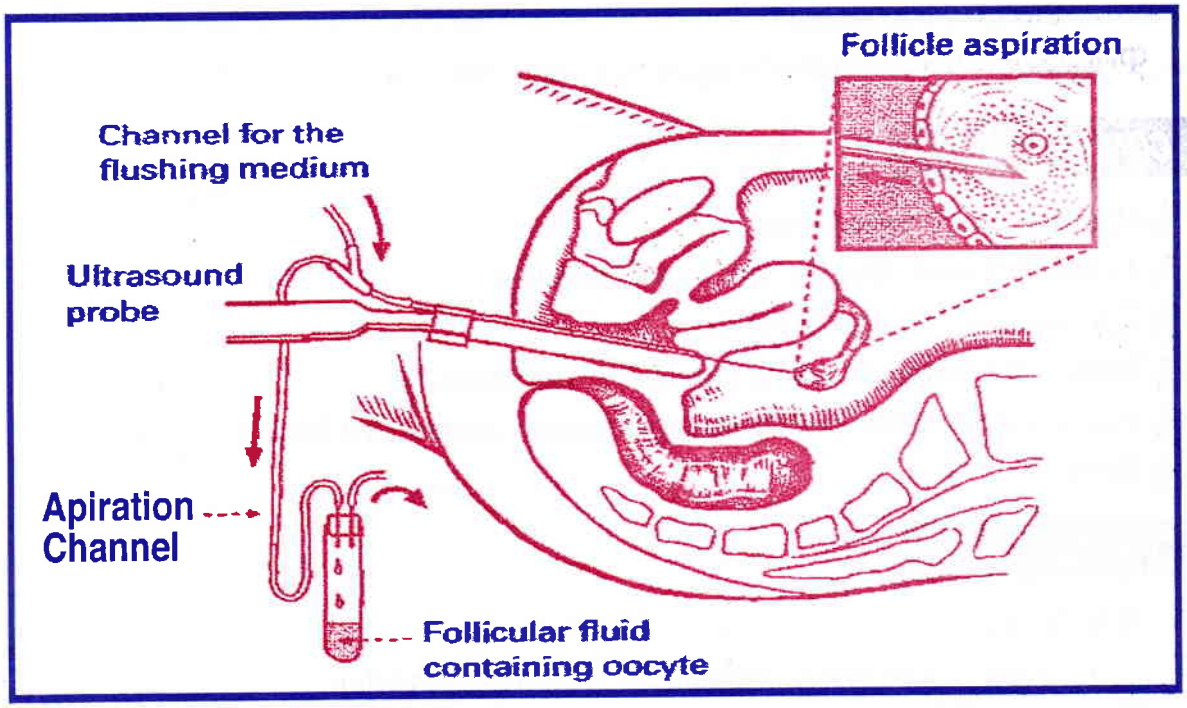
Follicle aspiration
Channel for the flushing medium
Ultrasound probe
Apiration Channel
Follicular fluid containing oocyte

OVARIAN HYPERSTIMULATION SYNDROME

- **MAINLY WITH** gonadotrophins classically only after the HCG injection.
- **RARE WITH** clomiphene citrate
- **NEARLY ABSENT** with GnRH (produces physiologic hormonal pattern)
- **COMMON IN** PCO patients

PATHOGENESIS

- **Hyperstimulated ovary produces substances that ↑ vascular permeability:**
  - PG
  - Histamine
  - Vascular epithelium growth factor
- **Increase vascular permeability leads to:**
  - Ascites, hydrothorax
  - Hemoconcentration, thrombosis
  - Electrolyte imbalance.
- **Prognosis will be worsened** if pregnancy test is +ve

COMPLICATIONS

- Hypovolaemia &hypotension.
- ↓ renal perfusion, oliguria, salt & water retention
- ↑ K, acidosis, ↑ weight & edema.
- Hemoconcentration & venous thrombosis with embolism.
- Poor tissue perfusion, permanent organ damage (hepatorenal failure)
- Death.

CLINICAL TYPES

- **Mild OHS:**
  - Ovarian enlargement, weight gain, abdominal distension.
- **Moderate OHS:**
  - As above + ascites, pain, nausea, vomiting, and diarrhea.
- **Severe OHS:**
  - As above + pleural effusion, hemoconcentration, electrolyte imbalance.

Ovarian hyperstimulation Syndrome

Pathogenesis

Ovary

- FSH (2%)
- CC (rare)
- GnRH (Nil)
- الشيطان
- HCG

↓

Histamine, PG, VEGF

↓

↑ Cap permeability

- effusions: pleural, pericardial, ascites
- edema
- hemo conc.
  - DVT, PE
  - RF
  - LCF
  - electrolyte imbalance

Degrees

Mild : انتفاخ

Moderate : انتفاخ + GIT ill

Severe : الاعراض + compl.

MANAGEMENT OF OHS

- **Prevention of OHS:**
  - Adjusting doses + good monitoring
  - Withhold HCG injection
    - If more than 3 follicles of 16 mm
    - Serum E2 > 2000 pg. /ml.
- **Active management:**
  - Mild form:
    - No treatment (rest at home +frequent follow up)
  - Moderate & severe form:
    - Hospitalization even in ICU
  - Conservative support until spontaneous resolution within few days
    - General rules: avoid palpation→ rupture of ovarian cysts
    - Antihistaminics, antiprostaglandins
    - Fluid charts but diuretics are contraindicated.
    - Frequent lab investigations: hematocrit, BUN, creatinine, electrolytes, Coagulation studies.
    - Severe types: Colloid & **ALBUMIN SUPPORT**, dialysis, paracentesis & **ANTICOAGULANT**
  - Laparotomy only in acute abdomen (ovarian cysts rupture/ bleed / torsion)
  - In pregnancy there is delayed recovery (release of endogenous HCG) & treatment is conservative

Prophylaxis

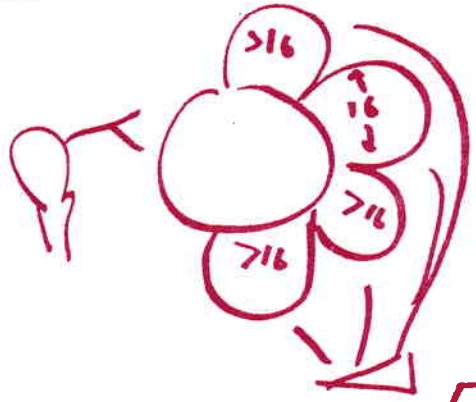

> 3 Follicles
> 16 mm

E_2 > 2000 pg/ml

Treatment

Conservation

B:

D: Fluid chart

S

Obs

Specific
- Anti PG, Antihist., Alb, Anticoag
- paracentesis
- Colloid support
- Dialysis & Avoid diuretics

التدخل جراحياً
Only if.....

GYNA 2

GYNA

GYNA 2

CONTENTS

Family planning

Infections

GENITO-URINARY

- Displacements.
- Incontinence
- Fistula

Genital displacement التقسيمه الجديده مهمه جدا

I-Vertical displacement

- **Ascent**: during pregnancy, big cervical fibroid
- **Descent**: prolapse

II-Anteroposterior displacements

- **Posterior** ...RVF
- **Anterior** ...acute AVF

III-Lateral displacement

- **More to right**, pulled by adhesion, pushed by mass on left side
- **More to left**, pulled by adhesions, pushed by mass on right side

IV-Inside displacements

- **Inversion** of uterus acute or chronic

V-Outside displacement

- **Anterior sacculation**: in fixed incarcerated gravid RVF
- **Posterior sacculation**: in gravid ventrofixed uterus

Support of vagina نقطه مهمه

1- Anterior wall support:
   - Pubocervical ligament
   - Urinary bladder
   - Attachment to the cervix
2- Posterior wall:
   - Uterosacral ligament
   - Levator ani
   - Attachment to the cervix
3- Paracolpos (paravaginal fascia) & Mackenrodt`s ligament.

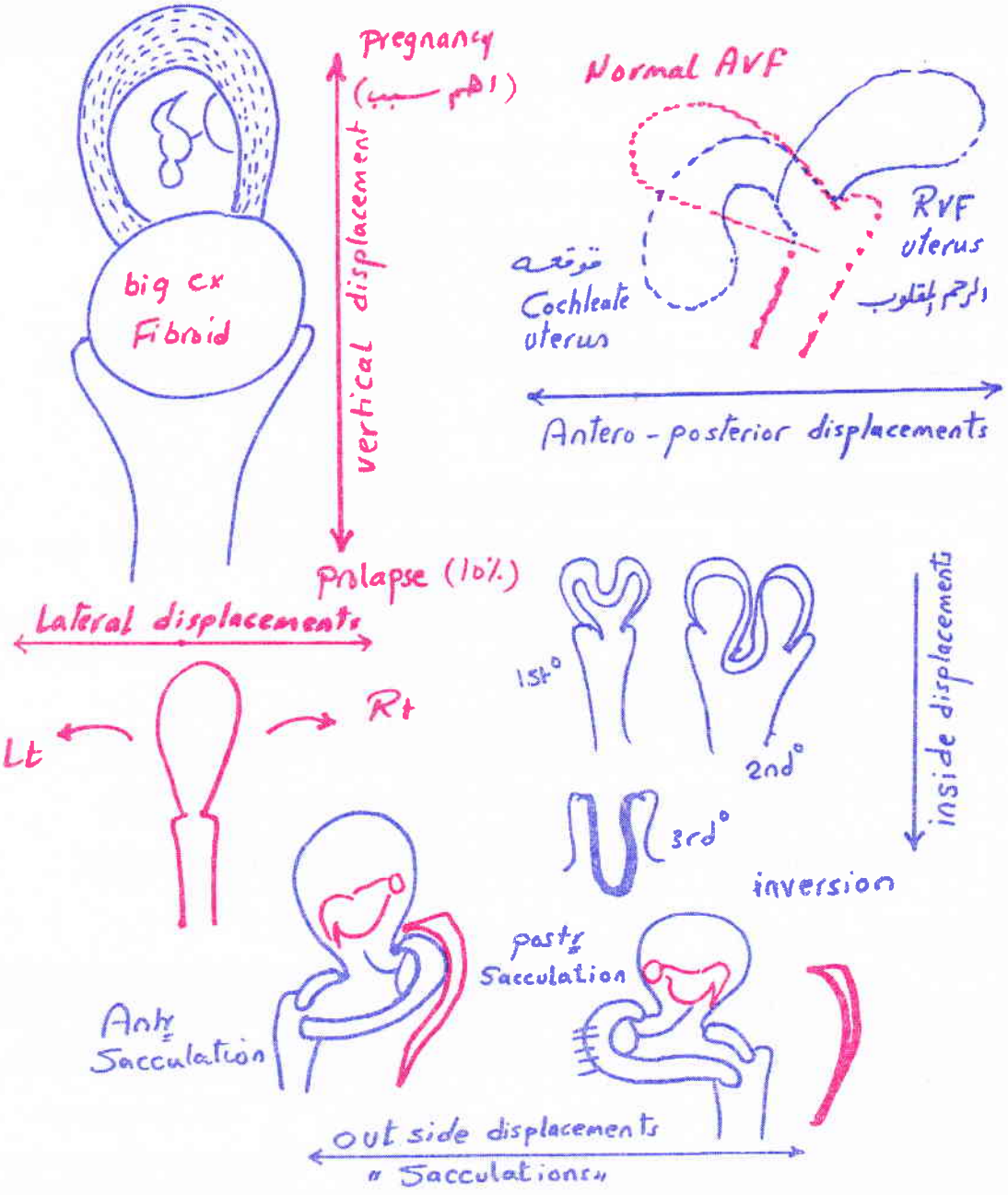
Pregnancy
(اهم سبب)
big cx
Fibroid
vertical displacement
Normal AVF
RVF
uterus
الرحم المقلوب
مقوقعه
Cochleate
uterus
Antero - posterior displacements
Prolapse (10%)
Lateral displacements
Lt
Rt
1st°
2nd°
3rd°
inversion
inside displacements
Ant.
Sacculation
post.
Sacculation
out side displacements
" Sacculations "


Ant. wall
Cx
pubo cx
lig
UB
Supports
of the
Vagina
Mack. lig
paracolpos
post. wall
cx
utero
sacral lig
levator ani

Retroverted Retroflexed uterus (RVF)

Definition:

- Retroversion (the fundus is directed towards the sacrum)
- Retroflexion (the anterior wall of the uterus becomes uppermost).
- The angles of version & flexion look backward

Incidence:

- 20% most of them are perfectly normal (asymptomatic), usually congenital.

Causes

- Mobile RVF (can be corrected manually):
  - Congenital RVF (commonest): It is asymptomatic & thus no treatment.
  - Fibroid or dermoid cyst pushing the uterus backwards.
  - Uterine prolapse due to laxity of ligaments
  - During puerperium "puerperal RVF":
    - **Due to** lax supports of the uterus & ↑ uterine weight.
    - **Liable if** the puerperal woman lies in the dorsal position.
- Fixed RVF **due to adhesions e.g. endometriosis or chronic salpingitis.**

Degrees:

	1st degree	2nd degree	3rd degree
Fundus direction	Promontory	sacral concavity	tip of the coccyx
Cervical direction	Downwards	forwards	Up & forwards
The uterus	In line with vagina	horizontal	Upside downwards

Diagnosis:

- Symptoms: No symptom in most of cases & it is discovered accidentally.
  1. Pain:
     - **Backache** caused by traction on the uterosacral ligaments.
     - **Dyspareunia** due to presence of congested ovaries in Douglas pouch.
     - **Congestive dysmenorrhea.**
  2. Menorrhagia due to pelvic congestion.
  3. Leucorrhea due to pelvic congestion.

- Angles of version & flexion:-



- Causes of RVF:-

Congenital خلقه ربنا
"most common by far"

Others
مزقوق - مشدود
puerperal - واقع

- Degrees:-

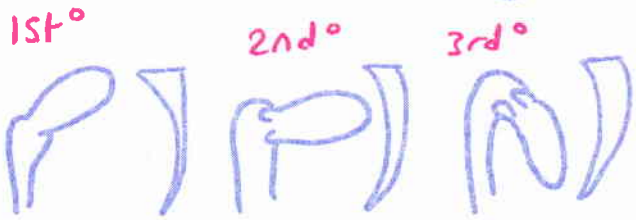

لاحظ منين Fundus
واتجاه ال cx

- Clinical picture:-

Asymptomatic
"most common by far"

Others

- Pain
- Bleeding
- discharge
- Abortion
- Pressure
- Infertility

4. **Pressure manifestations:** on bladder & rectum
5. **Infertility** (very very rare) due to;
   - ✱ Presence of the external Os away from the semen pool (posterior fornix),
   - ✱ Dyspareunia, pelvic congestion
   - ✱ Pelvic adhesions causing fixed retroversion.
6. **Abortion (rare):** In incarcerated retroverted gravid Uterus (at 14-16 weeks).

⇨ **Signs:** By vaginal examination, the following is detected;

A. **The external Os** is directed downwards & forwards OR forwards only.

B. **The fundus of the uterus** is felt through the posterior fornix.

C. **Uterine sounding** determines the position of the uterus.

D. **Special test**: pessary test مكتوب تحت

⇨ **Differential diagnosis : mass in Douglas pouch**

◈ In masses of DP, PR is done to detect relation of the mass to the rectum

1- **Uterine:**
   - ⇨ **Retroverted uterus** is the commonest mass.
   - ⇨ Posterior wall fibroid.

2- **Tubal**
   - ⇨ Hydrosalpinx, hematosalpinx or pyosalpinx.
   - ⇨ Tubal pregnancy.

3- **Ovarian** masses.

4- **Mass in peritoneum of Douglas pouch:**
   - ⇨ Pelvic hematocele or pelvic abscess.
   - ⇨ Endometriotic nodules of the pelvic peritoneum & rectovaginal septum.
   - ⇨ Metastatic nodules from cancer ovary.
   - ⇨ Tuberculous nodules.

5- **Ectopic kidney.**

6- **Mass in the rectum:**
   - ⇨ Cancer
   - ⇨ Fecal mass (could be indented by the Fingers).

7- **Retroperitoneal tumor**

-D.D. of masses in Douglas pouch:-

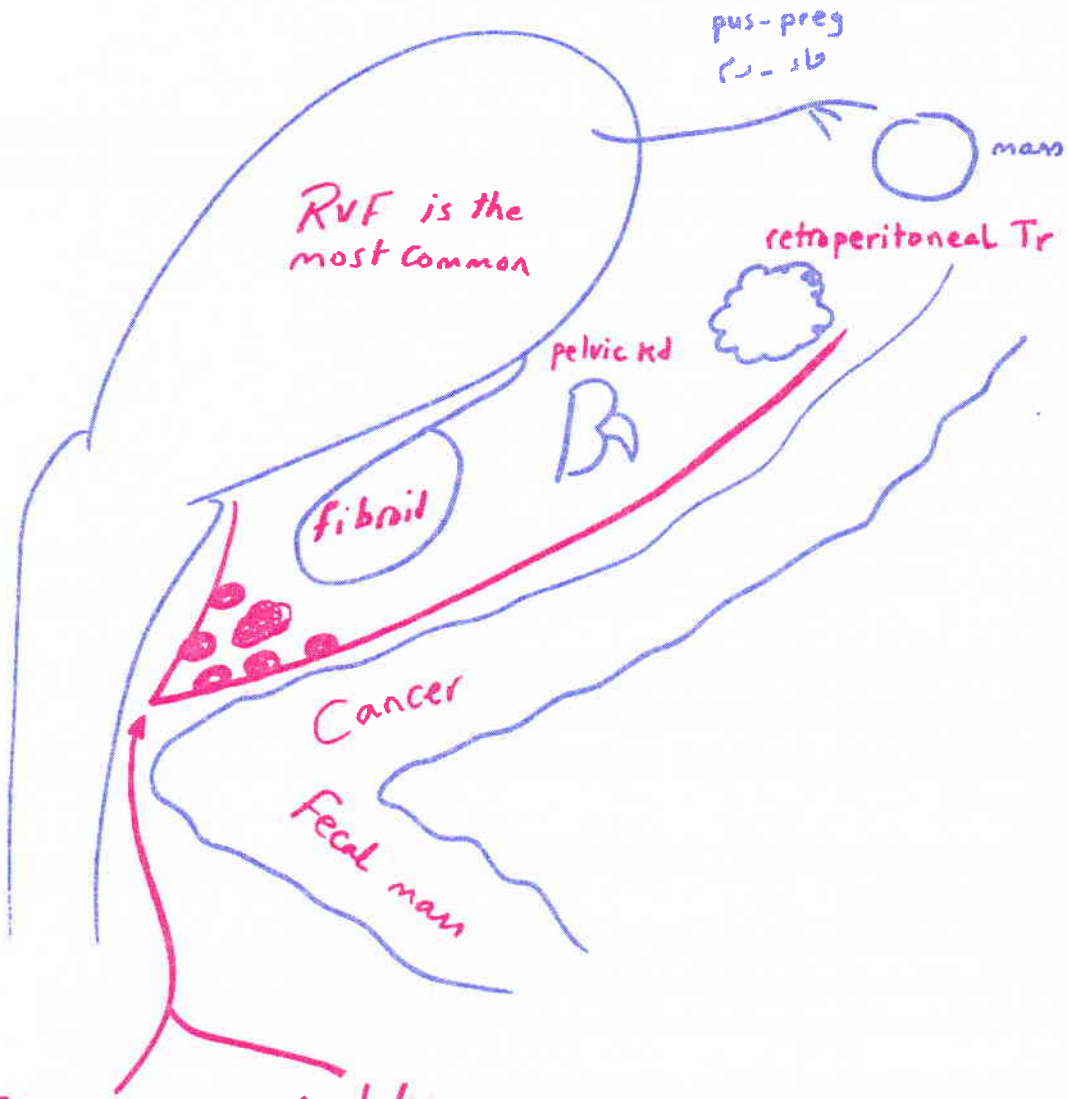

Fluid
- pus
- blood

nodules
- CA
- TB
- endometriosis

Treatment

If no symptoms, no treatment is required.

Treatment only if symptomatic & +ve pessary test

a) Prophylaxis

- **During puerperium**
  - Avoid prolonged lying on the back.
  - Frequent bladder evacuation
  - Pelvic floor exercise
  - If the uterus is RVF it is corrected and a pessary is used for 2 months.
- **Plication of the round ligament** to pull the uterus forwards in operations in which adhesions between uterine back & sacrum are expected

b) Palliative: Smith Hodge pessary (plastic)

- **Indications:** for cases of mobile retroversion,

1. **During lactation.**
2. **Early pregnancy:** If causing previous abortions.
3. **Bad surgical risk patient.**
4. **Pessary test determines**
   - If RVF is the cause, symptoms are ↓ed when the pessary is inserted.
   - RVF is corrected 1st & broad posterior end stretches posterior fornix.

c) Surgery (when the symptoms are improved by pessary):

- **Indications:** Symptomatic RVF whether mobile or fixed.
- **If RVF with prolapse** the cardinal ligaments are sutured in front of the cervix.
- **Ventrosuspension: operations depend on Suturing the round ligament to:**
  - The anterior rectus sheath "Modified Gilliam's abdominal operation".
  - Or plicated in the inguinal canals "Alexander Adams inguinal operation".
  - Or sutured together behind the uterus "Baldy Webster vaginal operation"
- **Ventrofixation of the uterus to the back of rectus sheath** وحشه جدا
  - It is not done as it leads to posterior sacculation & rupture uterus
  - Not done unless accompanied with bilateral tubal block

Gilliam's operation: the round ligaments are pulled up through the peritoneum and rectus muscle & sutured together across the recti but in Modified Gilliam's, the round ligaments are pulled up through the internal inguinal rings.

٤ كلمات

Treatment of RVF

- No Symptom
  ↓
  No Treatment

+

- Prophylaxis
  - "Smith Hodge pessary"

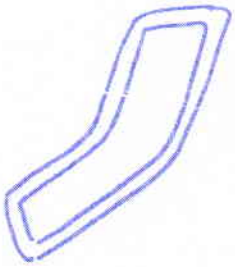

- Palliative (pessary)

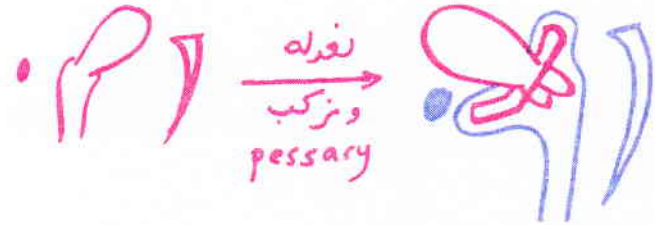

- Surgery
  - ventro Suspension ✓✓✓
    - Gilliam
    - اهمها
  - ventro Fixation ×××

Retroverted gravid uterus مهمه

Incidence:

- It occurs in about 10% of early pregnancy.

Fate:

- Usually RVF is corrected spontaneously by 10-12 weeks in most of cases
- **If not corrected:**
  - **Spontaneous abortion** (14-16 weeks)
  - **Incarceration** محشور is due to:
    - Jutting sacral promontory due to contracted pelvis→ tripping the uterus.
    - Pelvic adhesions or posterior wall myoma.
  - **Anterior sacculation** (the uterus expands on expense of its anterior wall) & subsequent rupture uterus.

Clinical picture & Complications:

- **Pressure symptoms & Retention** of urine due to stretch of the urethra.
- **Tender pelvi-abdominal mass** disappears by catheterization (full bladder)
- **PV ex**: soft mass in Douglas pouch + Cx is anterior pointed upwards & forwards

DD

- Pelvic hematocele, ovarian cyst & posterior wall fibroid

Management

- **If discovered early:**
  - Allow spontaneous correction & help by lying on abdomen + frequent emptying of the bladder.
- **If leads to habitual abortion:**
  - **Non pregnant:** ventro-suspension.
  - **Pregnant:** Hodge pessary till 14 weeks
- **If incarcerated:**
  - **Catheterize** the bladder + lying on face
  - **If fails:** try manual correction
  - **If fails:** manual correction under GA
  - **If fails:** may need to evacuate (may need hysterotomy as cx is high)
- **If anterior sacculation**→CS

RVF gravid uterus

10%

Fate

- كويس
  يتعدل لوحده
- وحش
  - حظ نحس مركب
    - Sacculation
      - CS
  - Incarceration
    - استره
    - manual نعدله
    - " " under anesthesia
    - evacuate
  - Abortion (14-16 w)
    - حامل
      - pessary
      - 3 m اول
    - مش حامل
      - ventro suspension

Genital prolapse غايه في الاهميه

Definition:

- Vertical descent of any genital organ (±UB, rectum)
- The ovary prolapse with RVF لازم

Incidence:

- 5-10 % depending on **obstetric care** تنقص لو لم تذكرها
- it is less common in blacks due to strong pelvic CT
- The commonest is **cystocele**, the least is **urethrocele**

Etiology:

- **Predisposing factor العوامل الرئيسيه**
  - **Congenital: (Usually uterine, in young ± rectal prolapse & viscero-ptosis)**
    - Cong. mesenchymal weakness or cong. weakness of endo-pelvic fascia
    - Short vagina or RVF uterus (the uterus is in line with the vagina)
    - Split pelvis or Spina bifida
  - **Acquired:**
    - Obst. Causes: (most common cause®☺)
      1- Delivery of macrosomic fetus طفل فيل صغير, large number of deliveries, rapid succession of delivery ارنبه.
      2- **Poor management of 1st stage:** excessive bearing down, forceps, ventouse, breech extraction (before full Cx dilatation).
      3- **Poor management of 2nd stage:** delivery in squatting position, prolonged 2nd stage, excessive fundal pressure
      4- **Poor management of 3rd stage:** Crede's method, unrepaired (or hidden) perineal trauma
      5- Precipitate labor, subinvolution & early ambulance
    - **Menopausal atrophy**: due to loss of the trophic effect of E.

- **Activating (precipitating) المساعده factors:** act when PDF are present
  - ↑ Intra abd. pressure e.g chronic cough, obesity, constipation
  - ↑ Size of the uterus or traction on uterus by a Cx polyp.
  - Iatrogenic as after colposuspension or sacrospinous fixation

N.B: 3rd **degree perineal tear** does not lead to prolapse, as patients are continually contracting their **levator ani** to control stool → abnormal strong levators

Genital prolapse



Vertical downward descent



Tube + ovary in RVF uterus

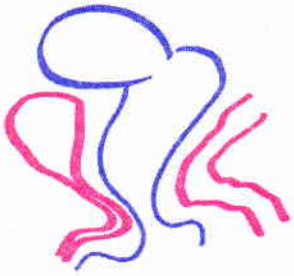

Genital displacement is usually associated with prolapse of UB or rectum

Etiology:-

العوامل الرئيسيه

العوامل المساعده

Predisposing Factors

- Cong.
- Acq.
  - Obs
  - Menopausal

Precipitating Factors

فرفوره

Types

(Cystocele (commonest) > uterine > rectocele > urethrocele مهمه)

1- **Uterine prolapse (procedentia):**
- **1st degree:** the cervix is below the level of ischial spine
- **2nd degree:** the cervix is outside the vulva
- **3rd degree:** the uterus is outside the vulva (complete procedentia).

2- **Vaginal prolapse:**
- **Anterior vaginal wall:**
  - **Upper 2/3 :** Cystocele (between bladder & transverse vaginal sulci)
  - **Lower 1/3 :** Urethrocele (between trans. vaginal & submeatal sulci)
  - **Both:** cystourethrocele

Posterior vaginal wall:
- **Upper part:** Enterocele (Hernia of Douglas pouch)
- **Lower part:** Rectocele

- **Both anterior & posterior vaginal walls:** cystorectocele
- **Vault prolapse:**
  - **More** in subtotal than total hysterectomy الكلام الجديد

3- **Combined prolapse:**
- **Utero-Vaginal:**
  - **Uterus** descends followed by the vagina (Acystocelic prolapse)
  - **More** in the young (congenital)
- **Vagino-Uterine:**
  - **Large** cystocele→traction on uterus (Cystocelic prolapse)
  - **More** in MP & postmenopausal (acquired)

Effects & Complications :

- **Genital system:**
  - **Tubes, ovaries & uterus** → congestion
  - **Cx & vagina**: congestion, dryness, hypertrophy, infection, trophic (Decubitus) ulcers, elongation of supra-vaginal part of cervix
- **Urinary system**
  - **Ureter:** kink → hydroureter & hydro-nephrosis, infections & uremia.
  - **On bladder:** residual urine → stasis, infection & stones
  - **On urethra:** descent of the urethra, kinking with severe degree
- **Rectum & anal canal:** kink

Types of prolapse

	Vaginal	uterine
Antr	upper 2/3 — Cysto-cele; lower 1/3 — urethrocele; Cysto urethro cele	Isch. spine — 1st degree
Postr	upper part — entero cele; lower part — recto cele	vulva — 2nd degree
vault	Vault prolapse	vulva — 3rd degree

Combined

- antr + postr vaginal walls → Cysto recto cele
- uterine + vaginal
  - utero-vaginal
  - vagino-uterine

N.B.

Two Types of cysto cele
- Midline
- lateral (paravagina

Clinical picture:

Symptoms

- **Genital system:**
  - **Symptoms due to descent**
    - Sense of lack of support then heaviness then mass protruding from vulva
    - Interfere with walking & sitting (↑ by straining & ↓ by lying down)
  - **Symptoms due to stretch:** lower Abd pain, back ache
  - **Subfertility & sexual difficulty** (Dyspareunia due to patulous vagina)
  - **Congestive (↑ 3)**"pain, bleeding, discharge"
  - **Trophic ulcer**
- **Urinary system**
  - **Upper UTI:** loin pain, fever, rigors, vomiting, renal failure
  - **Lower UTI:** supra-pubic pain dysuria
  - **Urethra:** early (SUI), later (Retention & dysuria, the patient may need to reposit the prolapse to urinate)
- **Rectum & anal canal:**
  - **Incomplete** or difficult defecation (dyschasia, the pt may need to reposit the prolapse to defecate)

Signs

General	Abdominal
Anemia **Chest** → bronchitis **Renal failure**	**A cause** → ascites, masses **Complication** → tender loin **Association**:spina bifida, visceroptosis
local examination	**Special tests**
Inspection: Lithotomy or squatting o Type & degree o Stress Incontinence & complication **Palpation:** o Raise bladder neck + cough test → SUI "Bonney test" o Tone of levator ani o Gurgling sensation of enterocele o Differentiate 2nd & 3rd o ut. descent **PV & Cusco:** 1st o ut. descent, gurgling in enterocele & associated condition	**Bimanual:** ovary, tube, uterine masses. **PR:** differentiate enterocele from rectocele **Malpus test** (combined PR & PV) **Volsellum test** : to see maximal degree of uterine prolapse **Sound:** differentiate prolapse from congenital cervical elongation **Catheter test** in cystocele

• effects & Clinical picture

on → urinary sys.
→ Genital sys.
→ Rectum

Kink in ureter →
hydro
hydro
pyo
pyo
Chr. RF
↓
UUTI

• ↑ residual urine
• infection
• stones
↳ LUTI

Kink → Dyschasia

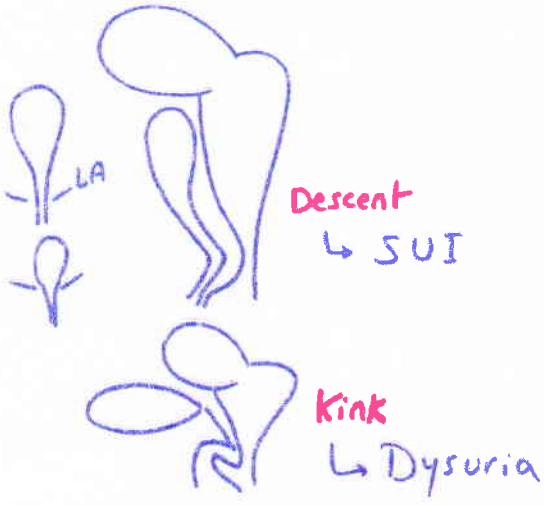

Descent
↳ SUI

Kink
↳ Dysuria

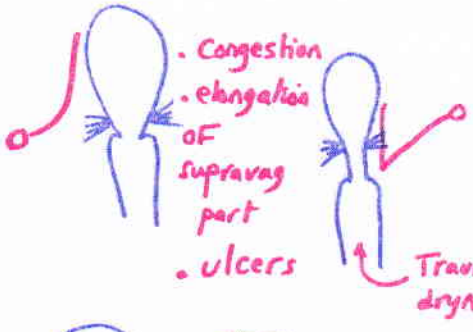

• Congestion
• elongation of supravag part
• ulcers

Trauma
dryness

DSCT

• Cause of subfertility
- Dyspareunia
- lack of sex. satisfaction
- Congested ov (↓ ovulation) endom. (↓ implantation)

Investigation:

- Clinically diagnosed مهمه جدا
- Pre-operative → CBC, chest X ray, ECG
- Complications: RFT, IVP, urine analysis & C&S

What is the D.D of prolapse?

- From other types of displacement (vertical, lateral, anterior & posterior)
- Differential diagnosis of prolapse:

Anterior vaginal wall

- **Differentiate cystocele from urethrocele:**

Cystocele:

- Bulges in upper vagina between transverse vaginal sulcus &bladder sulcus
- It is compressible, ↑ on straining.

2- Urethrocele:

- Bulges on lower vagina between transverse vaginal & submeatal sulci.

- **Differentiate cystocele from anterior vaginal wall cyst:**

1- **Gartner's cyst:**
   - Not compressible
   - Do not increase on straining
   - Introduce catheter: it will not reach the bulge in the vagina
   - Usually to one side ,
   - Treated by excision.
2- **Dermoid cyst:** Same signs as Gartner's cyst
3- **Urethrocele from urethral diverticulum:**
   - Not reducible, & if reducible, pus comes out from the meatus
   - Does not increase on straining.
4- **Simple redundant anterior vaginal wall:** Differentiated by catheter test.

Posterior wall prolapse

- **Differentiate rectocele from enterocele:**

Rectocele	Enterocele
- In lower part of posterior vaginal wall. - On reduction no gurgling - No doughy sensation - P/R: fingers in the bulge - Malpus test: finger can be approximated	- In upper part of posterior vaginal wall - Gurgling sound on reduction - Doughy sensation if it contains omentum - P/R: finger not in the bulge - fingers are apart from each other

• Special Tests in prolapse :-

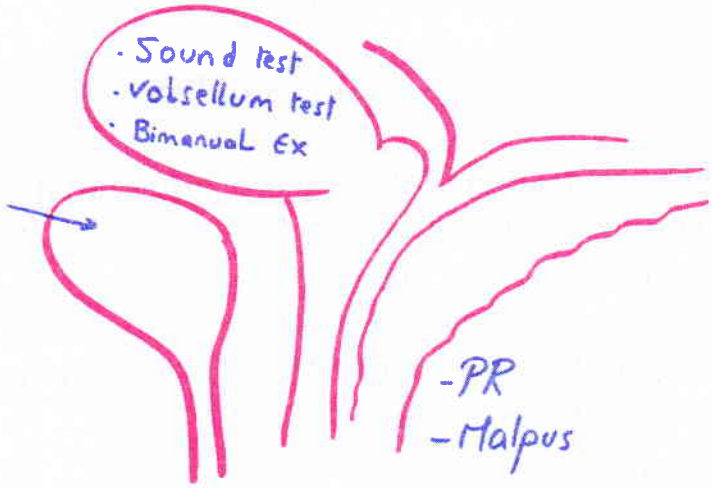

• Differential diagnosis of prolapse :-



- enterocele x hernia of DP
- enterocele x rectocele
- prolapse x post^r wall cyst
- Cystocele x urethrocele
- prolapse x ant^r wall cyst (Gartner / Dermoid)
- urethrocele x urethral diverticulum
- prolapse x redundant vag
- ut prolapse x mass protruding from vag
  - 1st
  - 2nd
  - 3rd
  - polyp
  - CA cx
  - inversion

- ut descent X cong cx elongation

- **Posterior wall prolapse is differentiated from:**
  - **Posterior wall cyst (commonly implantation dermoid):**
    - ⇨ Not compressible
    - ⇨ Does not increase on straining.
- **Enterocele & hernia of Douglas pouch:** gurgling sensation in enterocele, anatomic site (Malpus test), +ve impulse on cough

Uterine prolapse

- **Uterine prolapse is differentiated from:**

1- **Congenital elongation of the cervix is differentiated by:**
   - ⇨ Young age, Nulligravida,
   - ⇨ Deep fornices, AVF uterus,
   - ⇨ Cervix do not descend on straining
   - ⇨ By sound test: the elongation is found in the portiovaginal part of cervix not in the supravaginal part.

2- **Fibroid polyp:**
   - ⇨ Absence of external os.
   - ⇨ The cervix is at its normal level with the pedicle of the tumor coming through it.
   - ⇨ A sound can be introduced for a long distance into the uterine cavity.

3- **Inversion of the uterus:**
   - ⇨ Absence of external os.
   - ⇨ The body of the uterus is not felt abdominally.
   - ⇨ The mass is covered by smooth endometrium.
   - ⇨ Uterine sound is introduced for short distance or can`t be introduced at all.

4- **A cauliflower carcinoma or sarcoma of the cervix or vagina:**
   - ⇨ May appear at the vulva.
   - ⇨ The mass is friable, necrotic, hemorrhagic & indurated at its base.
   - ⇨ Congenital elongation occurs in young, vaginal vault above ischial spine.

5- **1st, 2nd & 3rd degree uterine descent** by approximating the fingers above the prolapsed swelling (grip test)

N.B.: Sound can differentiate:

Cervical elongation, polyps, inversions (sound uterus is not felt abdominally)
Cauliflower carcinoma or sarcoma (friable mass which bleeds easily)

N.B. Malpus test

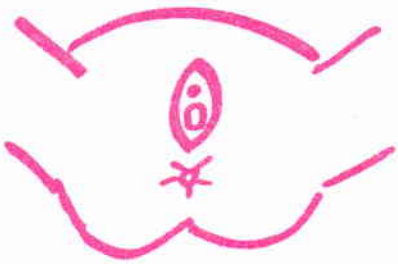

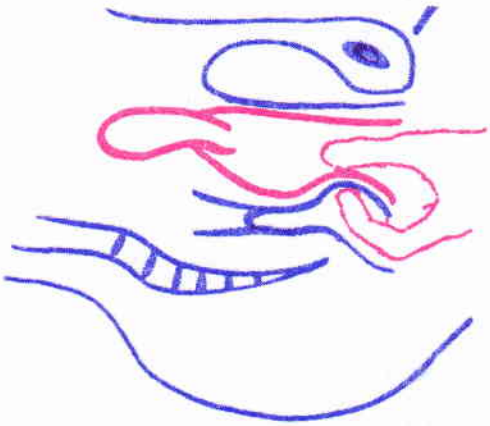

- index in the rectum & thumb in vagina

The patient is standing (ومكان تايم) & adducting thighs, ask her to strain after approximating the 2 fingers, if the fingers are still approximated → rectocele but if become apart → enterocele

Treatment:

Prophylactic

- Good **antenatal**, **intranatal** & **postnatal** care
- Prevent causes of increased intra-abdominal pressure
- Proper support of vaginal vault after hysterectomy to avoid vault prolapse.
- If prolapse is detected → pelvic floor exercise or pessary

Palliative

- **General indications:**
  a) Minor degrees
  b) Congestion: during pregnancy or till 3 – 6 months after delivery
  c) Till healing of trophic ulcers
  d) Unfit or refusing surgery

- **It includes:**
  - **Behavioral changes** (↓ smoking & weight)
  - **HRT** in menopause.
  - **Physiotherapy (Kegel's exercise)**
    - Identify the pelvic floor muscles by asking the patient to hold urine
    - the contracting muscles are the pelvic floor muscles
    - Voluntary contraction of these muscles in gradually increasing times
  - **Pessary** (Ring الحلقه or Smith Hodge pessary, cup & stem لا يذكر قديم جدا)
    - **Indications:**
      - Too young or too old
      - Unfit or refusing surgery
      - During pregnancy or shortly after delivery
      - Smith Hodge pessary is used also in RVF (palliative & therapeutic test)
    - **How to test it:**
      - Place the pessary and ask the pt strain
        - ✱ If remained in place it is a fitting size
        - ✱ If not, use a larger one.
    - **Complications:** Infection, ulceration, failure & discomfort if too large
    - **Precautions**:
      - **Daily**: vaginal douching
      - **Monthly**: cleaned
      - **Every 3 months**: it must be changed (now up to 1 year)

Summary of treatment

- Prophylactic
- Palliative
- Surgery
  - preop
  - operative
  - postop.
  - Compl.
  - recurrence



② vault operations
④ vaginal operations
⑥ uterine operations

- palliative:-

pessary:-

X تنس

- Indications
- Complication
- How to use
- Precautions

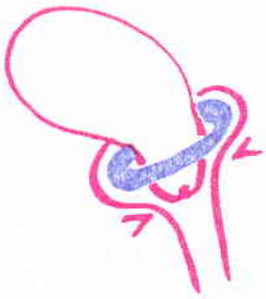

Ring pessary

Surgical خمس نقط

A-Preoperative preparation:

- **General:** treat anemia, chest condition, uremia, stop smoking & ↓ weight.
- **Abdominal:** treat UTI, masses
- **Vaginal:-**
  - **Treat ulcers:**
    - Reposition of prolapse → restores circulation & ↓ hypoxia
    - Estrogen creams in menopausal women but ↑ intraoperative bleeding
    - Resistant ulcers are painted with silver nitrate.
  - **Local estrogens** in postmenopausal female

B-Operations:

Vaginal wall prolapsed اربع عمليات

Cystocele: ant. Repair (anterior colporrhaphy تصليح مهبلي امامي)

- **Incision**: T shaped incision of the anterior wall of the vagina
- **Reposition**: Cut pubo-cervico vaginal fascia to reposit the bladder
- **Plication**: of peri-vesical fascia & approximation of pillars (**most important**)
- **Excision**: of redundant vagina & closure

  If urine retention → supra-pubic catheter clamped on 2nd day postoperative removed when residual volume < 100 ml & UOP / d > 200 ml

Urethrocele : Kelly's suture

- Incision: till submeatal sulcus & V shaped suture in periurethral tissue
- Catheter is left for 5 days
- Some prefer classical repair in TREATMENT of Urethrocele

Rectocele: Posterior repair: "posterior colpo-perineorrhaphy"

- **Incision**: Rhomboid shaped incision of the posterior vaginal wall.
- **Reposition**: Dissection & reposition of the rectum
- **Suturing**: of pubo-rectalis of levator ani (most imp) ± mesh is used
- **Excision: of redundant vagina & closure**

  Complication : bowel injury , constipation

Enterocele : culdoplasty

- **Either: Abd (Moscowitz)** or **vaginal approach (Mccole)**
- **Remove** redundant peritoneum & suture uterosacral lig. obliterate DP

- **Anterior repair (done first) + posterior repair = classical repair**
- **In SUI → Kelly's or Burch colposuspension**
- **Key step in all operations is the repair of the fascial defect.**

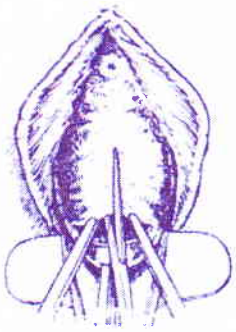

ANTERIOR REPAIR 1. Opening up the anterior vaginal wall.

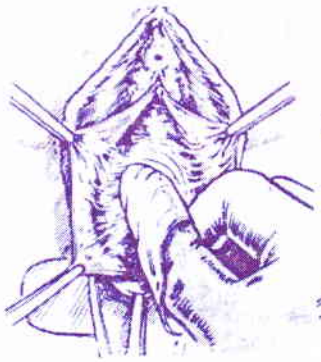

2. Mobilising cystocele from vaginal walls.

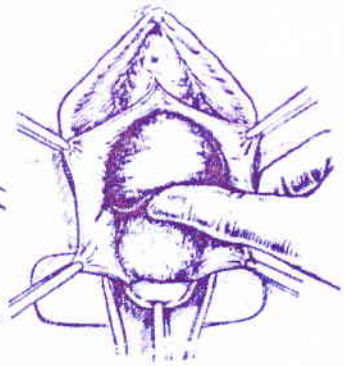

3. Mobilising cystocele from cervix.

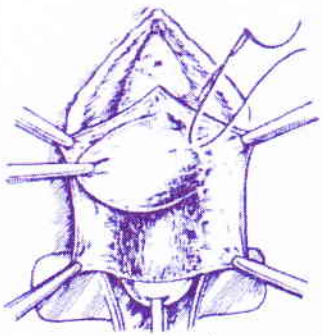

4. Placing the tightening suture as far laterally as possible.

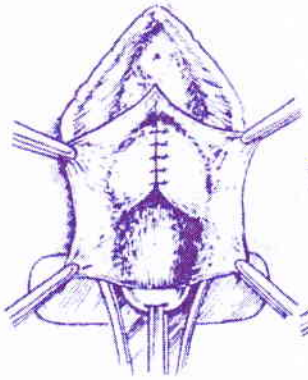

5. Obliteration of the cystocele completed.

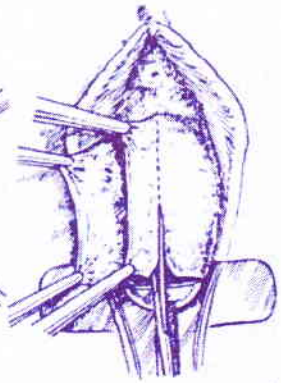

6. Removing redundant vaginal wall. This is followed by closure with a continuous catgut suture.

Anterior repair





1. Mobilisation of the posterior vaginal wall

2. Separating rectocele from posterior vaginal wall.



3. Obliterating the rectocele by tightening the fascial layer (cf. obliterating the cystocele.)



4. Excess vaginal skin is removed. The perineal muscles are sutured over the obliterated rectocele. The skin and vagina are closed as in perineorrhaphy (p. 180).

Kelly's Sutures

posterior repair

Vaginal vault prolapse اثنين

- **Definition:** Prolapsed vault following hysterectomy
- **Causes:**
  - Sub-total hysterectomy
  - Bad operation choice as abdominal hysterectomy in presence of weak pelvic floor
  - Enterocele not corrected
  - Vaginal hysterectomy without pelvic floor repair if needed
- **Treatment of vault prolapse:-**
  - **Vaginal:** Sacrospinous fixation or Le Forte
  - **Abdominal:** Sacral Colpopexy or suturing the vault to Mackenrodt's ligament

Uterine prolapse ستة عمليات

- **1st º+ vaginal prolapse:** classical repair + shortening of Mackenrodt`s ligament.
- **Young Female:**
  Abd sling direct or indirect (the aim is to form artificial utero-sacral ligament extending from Cx to mid-sacral piece).
- **Around 40 y:**
  Fothergill or Manchester op (٤ x 1 عمليه):
  - **D & C** (curettage is done to exclude pathology while dilatation to avoid post operative stenosis)
  - **Classical repair** (start by anterior colporrhaphy)
  - **Amputation of Cx** (not done in modified Manchester)
  - **Shortening of Mackenrodt** (either placation or resection advancement or sutured together in front of the cervix)
- **Older:** Vaginal hysterectomy + Pelvic Floor Repair مهمه جدا خلي بالك
- **Very old:** **LE forte** (partial colpocliesis) under local anesthesia
- **Sacro-Spinous Fixation** → Makes artificial uterosacral.
  - It preserves the vaginal axis but may lead to cystocele.

C-Post operative care:

- **Early:**
  - Vaginal pack for 24 hs to avoid reactionary he
  - Analgesics, Antibiotics
  - Residual urine should be assessed before discharge
- **Remote:**
  - Avoid (lifting heavy weight for 1m, coitus for 2m, pregnancy for 2 y)
  - Delivery is by generous episiotomy + prophylactic forceps or CS

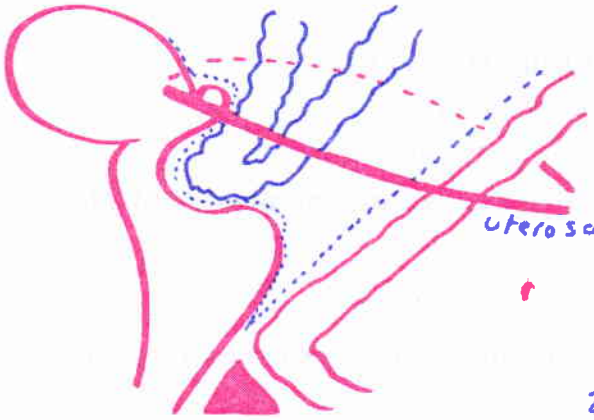

- رجع intestine
- اقفل 2 utero sacral
- قص Redundant vag + peritoneum

Uterine prolapse

1st °

young :. cervical sacrapexy

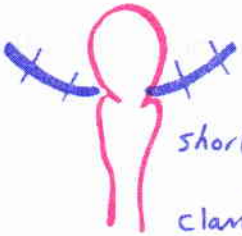

shortening of Mack.
+
clamical repair.

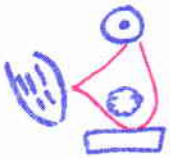

It Psoas

indirect sling

Direct sling

"Nylon tape by aneurysmal or Shirodkar needle Fixes The cx to ant. long. lig. of sacrum"

oral نتأل 6mm x 70cm

LE Fort

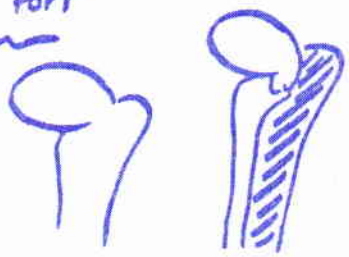

= partial colpocleisis

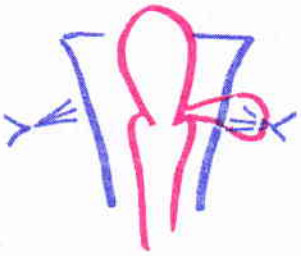

SSF

fixing The cx to sacro spinous ligament

D-Postoperative complications:

- **Immediate:**
  - **Complication of anesthesia**, DVT, PE
  - **Injury** to urinary bladder, rectum
  - **Infection** to wound, UTI, pelvic infection
  - **Hge:** 1ry, reactionary (slipped ligature or dislodged clot) or 2ry (infection)
- **Delayed:**
  - **Vaginal stenosis**→Dyspareunia & soft tissue obstruction
  - **Fistula**
  - **Recurrence of prolapse** (5-10%)
  - **Special complication** according to the type:
    - Anterior repair: UR, SUI, Bladder injury
    - Post. Repair: Dyspareunia
    - Abd. Sling: Intestinal obstruction, Ureteric injury, LL pain (psoas spasm)
    - Fothergill op.: Infertility, Incompetent cx, Habitual abortion, cx stenosis & dystocia
    - Le Forte: Apareunia, No D&C if postmenopausal bleeding occurred

Recurrence:

- 5-10% usually in the 1st 2 years.
- Correction (more difficult) is at least 3- 6 m after previous op & treat the cause
- Causes of recurrence
  - **Preoperative:**
    - Developmental weakness.
    - Undiagnosed enterocele.
    - Bad preparation.
  - **Operation:**
    - Bad dissection or bad choice of operation.
    - Excessive shortening of the vagina.
  - **Postoperative:**
    - Infection, Hge.
    - Rapid pregnancy & delivery.
    - Recurrence of predisposing factor.

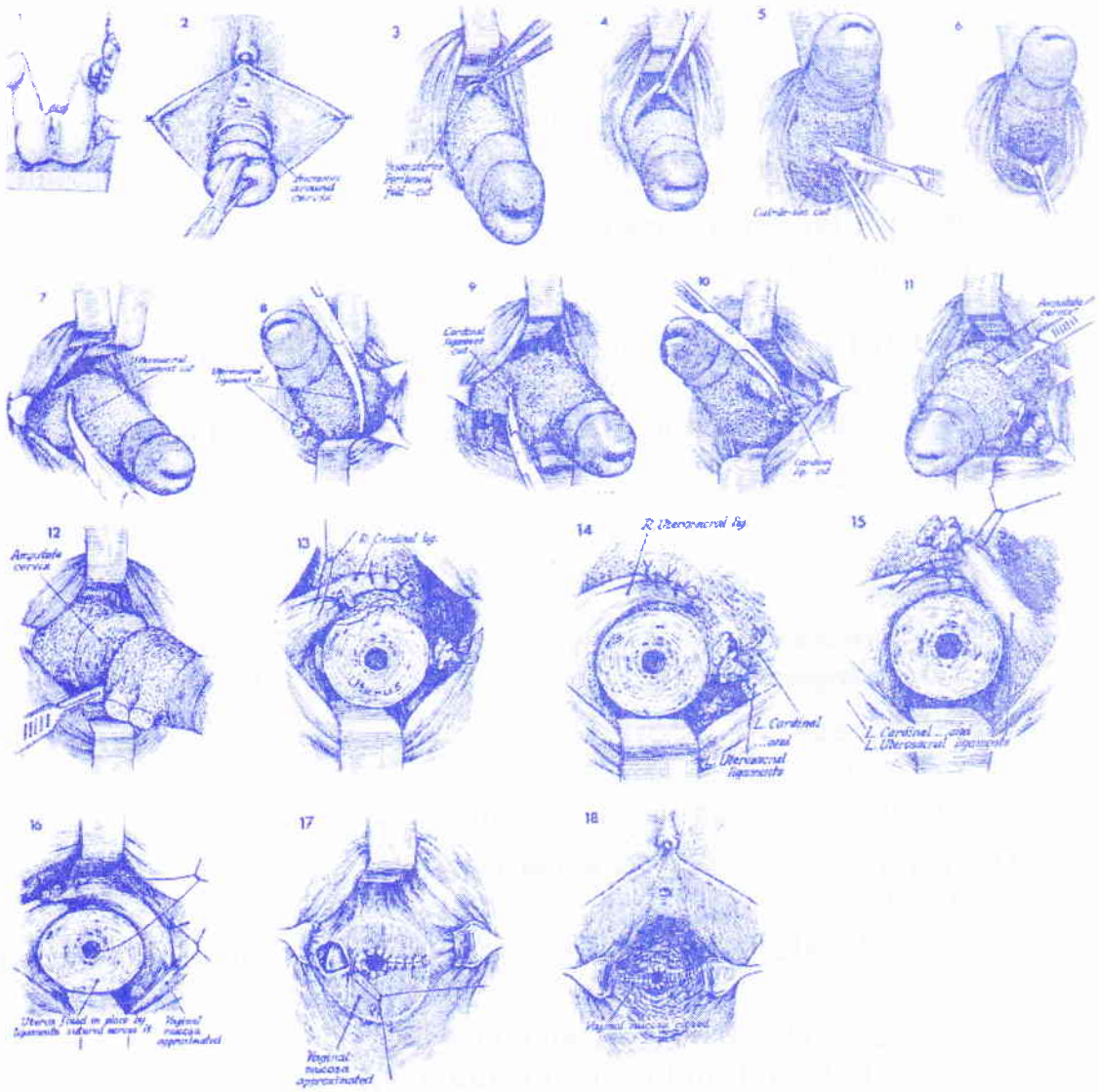

Manchester operation

oral

Most imp step in

- Ant^r repair :- plication of perivesical fascia
- post^r repair :- suturing of levator ani
- Abd sling :- good grip in ant^r long lig
- V H :- Fixation of vault to Mack. or utero sacral lig.

oral

What's POPQ classif.?

- stage 0 :- No prolapse
- stage 1 :- The leading point is 1 cm above hymenal ring
- stage 2 :- leading point is within 1cm above HR & 1cm below
- stage 3 :- leading point is below 1 cm below HR
- stage 4 :- as 3 but with complete vaginal eversion

Incontinence

- **Definition:** Involuntary loss of urine.
- **Anatomical considerations**

1. **Urinary bladder (dome):**
   - Pyramidal in shape
   - Layers:
     - **Detrusor muscle**: outer longitudinal, middle circular & inner longit.
     - **Mucosa (urothelium)**: 2 – 3 layers of transitional epithelium
2. **Trigone (base):**
   - A △ area between both ureters & bladder neck, lies anterior to midvagina
   - Layers:
     - **Superficial trigonal muscle**: circular extends around urethra & ureters
     - **Deep trigonal muscle**: continuous with deep longitudinal layer of urethra.
3. **Bladder neck** مهمه:
   - It has little sphincteric action
   - It is lined by transitional epithelium.
4. **Urethra** غايه في الاهميه : **3-4 cm in length**
   - **Muscles**:
     - **Urethral intrinsic smooth muscles** (inner longitudinal, outer circular.)
     - **Urethral extrinsic striated muscles:**
       - **External sphincter (involuntary):**
         - At mid urethra مهمه جدا
         - It keeps continence at rest
       - **Levator ani (voluntary):**
         - At junction bet mid urethra & lower 1/3.
         - Keeps continence at stress
   - **Epithelium**: Pseudo-transitional (external meatus; stratified squamous)
   - **Submucosa**: 2 venous plexuses → watertight (hermetic) seal
     - **Proximal**; E dependant (weak at menopause)
     - **Distal**: isn`t E dependent.
   - **Ligaments**:
     - **Anterior**: Pubourethral lig (most important) has cholinergic supply.
     - **Posterior & lateral**: endopelvic fascia attached to arcus tendinus.

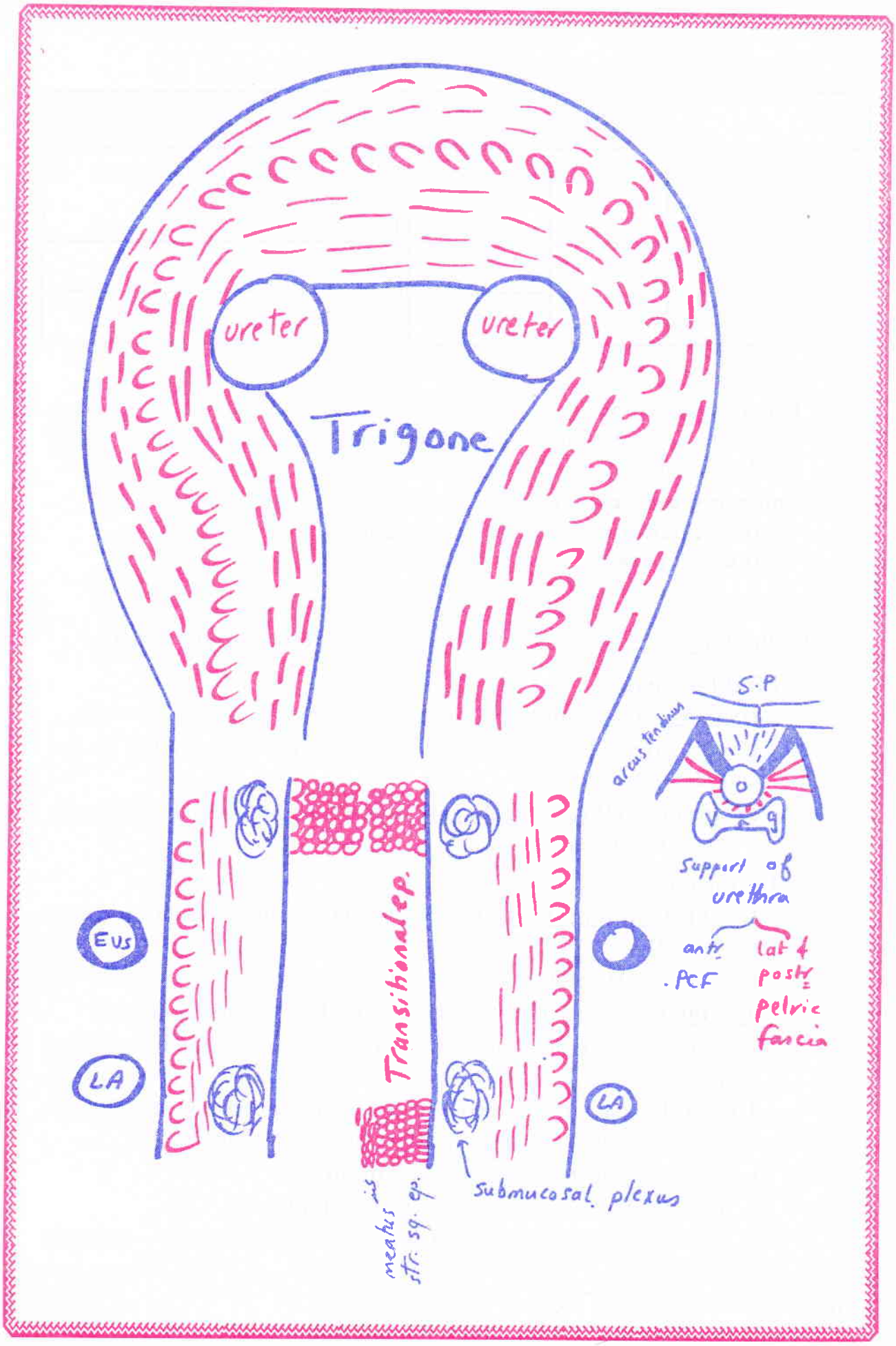
ureter
ureter
Trigone
Transitional ep.
EUS
LA
LA
meatus
str. sq. ep.
submucosal plexus
S.P
arcus tendinus
O
V
g
Support of urethra
anty. PCF
lat & posty. pelvic fascia

Innervation of the lower urinary tract:

	Root	Nerve	Action
Sympathetic	T10 - L2	Hypogastric	α: contract bladder neck & urethra. ß: relax bladder wall.
Parasympathetic	S2,3,4	Pelvic	(+) micturition
Somatic		Pudendal	(-) micturition

Physiology of micturition:

- **Local stimulation** (+) of the bladder → afferent to the pontine micturition centre without relay → efferent to sacral micturition centre → Micturition (-SS & +P).
- **Voluntary control**: Pyramidal Detrusor area (Frontal Cortex)
  - **Direct pathway**: (+) pudendal nerve in sacral area
  - **Indirect pathway**: (-) pontine centre

Mechanism of Continence:

⇨ **Urethral closing pressure** (50 cmH2O) > **intra-vesical pressure** (5 cmH2O).

A- Bladder factors:

- **Hydrostatic pressure** at bladder neck < 10 cmH2O الوحيد اللي ضدنا.
- **Compliance:** bladder reacts to ↑ volume by distensibility & not contractility.
- **Posterior urethro-vesical angle** (Functional not anatomical) at rest = 100-120°, at voiding = 180°.

B- Urethral factors:-

- **Urethral closing pressure** (50cmH2O) > intra-vesical pressure (5cmH2O)
- **Hermetic seal** by the sub-mucosal plexuses.
- **The intrinsic & extrinsic urethral muscles** (smooth & striated)
- **Presence** of proximal urethra & bladder neck above urogenital diaphragm
- **Urethral supports**: hammock effect of the pubocervical fascia & levator ani compresses the urethra against the vagina.

C- At stress, 2 Synchronous actions occur:

- The bladder neck is pulled upwards & forwards
- while bladder base is pushed downwards & backwards → urethral kink

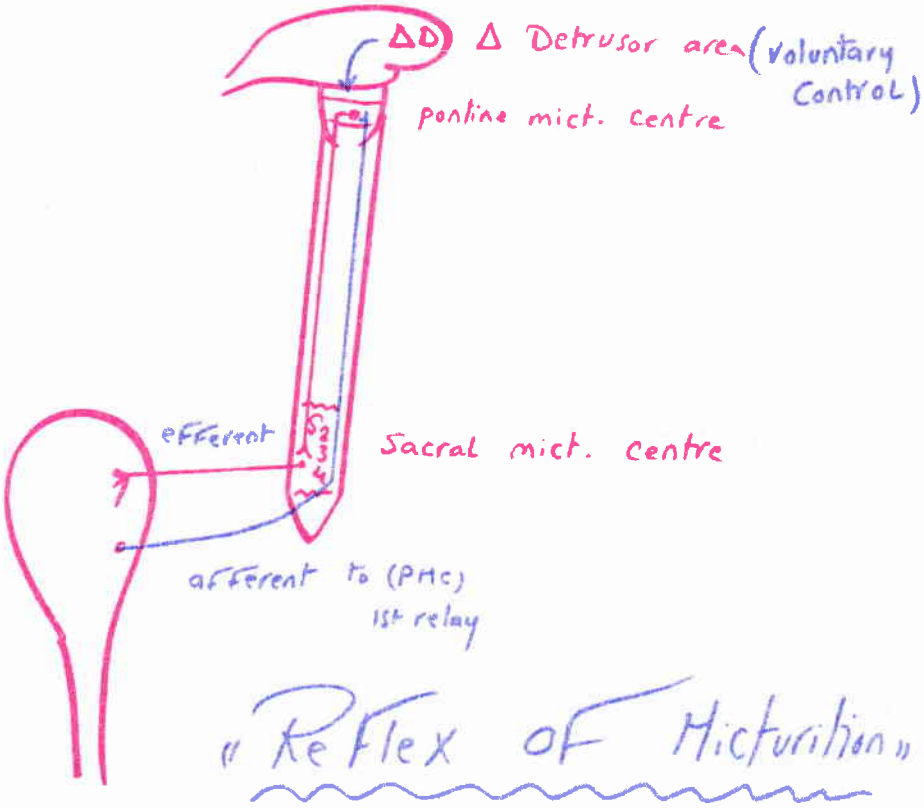

"Reflex of Micturition"

Mechanism of Continence

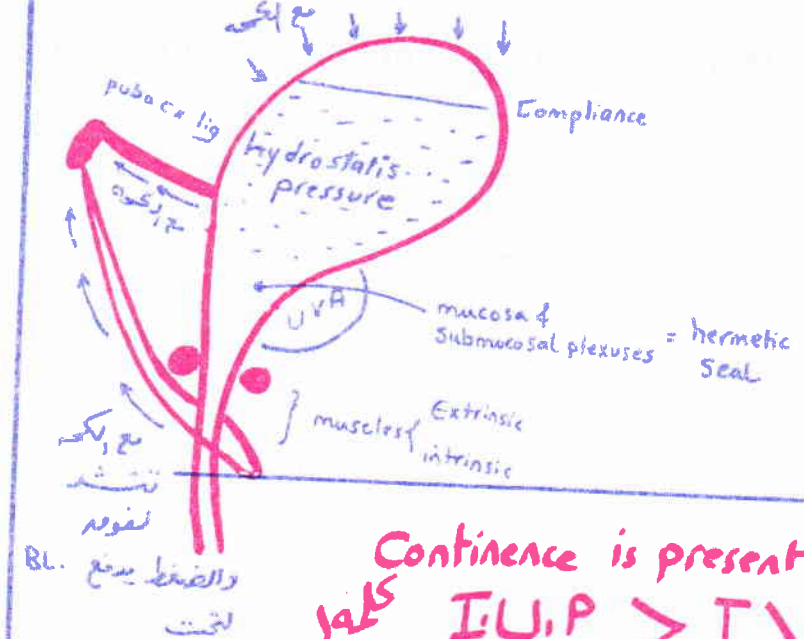

This part above L.A
So any ↑ in intra-abd pr. will be distributed equally to bl & urethra "O"

Continence is present

$$I.U.P > I.V.P$$

(50 cm H_2O) (5 cm H_2O)

Etiology of incontinence:

Extra urethral (True ncontinence)	Transurethral:
• **Congenital** as ectopic ureter or • **Acquired** as fistula	• **Urethral** sphincter incompetence • **Detrusor** instability • **Urine** retention with overflow

Clinical Picture الانواع:

- **True incontinence:** urine escapes continuously + no desire (due to fistula)
- **Paradoxical incontinence** urine escapes continuously + desire غريبه
  - Causes:
    1- Vesicovaginal fistula (small, high or valvular)
    2- Unilateral ureterovaginal fistula
- **False incontinence:** Chronic retention with overflow e.g. paraplegia (no sensation)
- **Urge incontinence: commonest cause of incontinence after menopause.**
  - The patient feels the desire to micturate, passes urine involuntary before reaching the W.C. due to detrusor over-activity
- **Nocturnal enuresis:** Bed wetting in neurological or psychological disorders.
- **Stress incontinence: Most common cause of incontinence during CBP.**
  - **Def:** Involuntary loss of urine with any act that ↑ intra-abdominal pressure, that makes a social & hygienic problem, in the absence of any detrusor activity {stress urinary incontinence (symptom) = demonstrable UI (sign) = genuine UI (urodynamic diagnosis)}
  - **Incidence:** 30% (5% only are symptomatic)
  - **Degrees:**
    - **Grade 1:** Incontinence with severe stress (coughing).
    - **Grade 2:** Incontinence with moderate stress.
    - **Grade 3:** Incontinence with mild stress. (Standing).
  - **Green Classification مهمه جدا:**
    - **Type 1:** loss of post urethra-vesical angle.
    - **Type 2:** loss of post urethra-vesical angle + rotational urethral descent (more severe + need abdominal approach).
  - **Types of stress incontinence:**
    - **True stress incontinence:** urethral sphincter incompetence.
    - **Detrusor over-activity.**
    - **Mixed.**

Urethral sphincter incompetence

Causes

- **Anatomic loss of support (40%):** descent of bladder neck (hypermobile urethra)
- **Intrinsic sphincter deficiency (60%) النسب مهمه جدا:** congenital or damage by
  - Birth trauma
  - Surgery (improper surgery on bladder neck or spinal cord)
  - Postmenopausal atrophy (lack of E trophic effect)

History

- **Stress** incontinence (immediate loss), frequency & urgency + History of the cause

Examination

- **Chest:** Bronchitis, asthma
- **Abdomen:** Scars, distended bladder (retention overflow).
- **Back:** Spina Bifida
- **PV:** prolapse, tone of levator ani

Specific Tests

- **Cough stress test ثلاث خطوات:**
  - **Bladder** is moderately full & the patient is in lithotomy & ask pt to cough,
  - **If -ve** → repeat while the perineum is depressed by 2 fingers to eliminate the reflex contraction of levator ani.
  - **If still -ve** → repeat in standing position
- **If stress test is +ve with prolapse:**
  - **Bonney T:** repeat cough test + 2 fingers inserted into the lateral vaginal fornices
  - **Marshall T:** cough test + Allis clamp elevates the ant vaginal wall
  - **If became –ve** = it is due to descent not sphincteric weakness.
- **If stress test is –ve with prolapse:**
  - **Youseff test:** Reduction with volsellum pushing the cervix
  - **Pessary test:** Create the effect of surgical reduction
  - **If still –ve** = normal & if +ve = hidden stress incontinence.
- **Bulbo-cavernous reflex test:** denote intact sacral region
- **Q tip test:**
  - A lubricated cotton swab is inserted in the urethra & patient strains
  - Normally the change in swab angle < 30°
  - If ranges from 30-60° → hyper-mobile bladder neck.

- Cough Stress test +

prolapse

+ve — مريضه

-ve — سليم

~~Prolapse~~

Bonney in Gyn.
- Bonney Myomectomy clamp & screw
- Bonney test
- Bonney hoodop.

- Bonney
- Marshal
- Youseff
- pessary

Tests

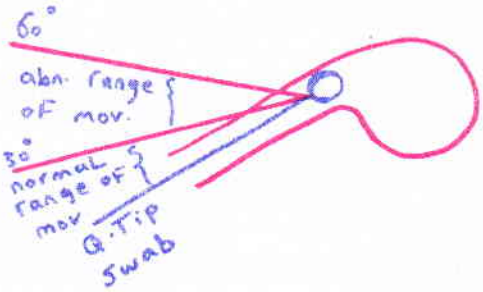

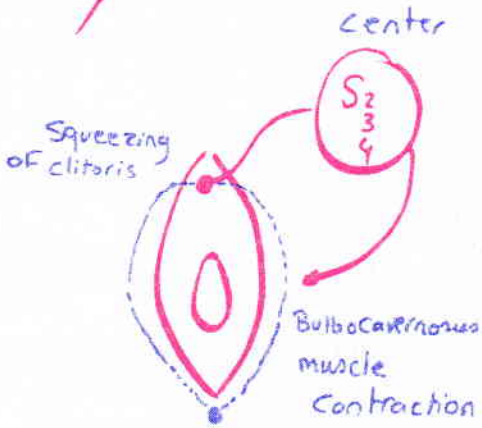

Investigations

Basic tests:

- Midstream urine analysis & C&S to exclude cystitis (causes DOA)
- **Urinary dairy**: fluid chart
- **Pad فوطه test**:
  - Patient wears a pad for 1 hr (simple pad test) or 1 day (extended pad test)
  - Reweight the pad to know the degree of urine escape

Urodynamic (multichannel video urodynamic): assess pressure/volume changes

1- **Cystometry:**	2- **Urethrometry دى الاساس:**
✱ **Normal residual urine** (50 ml) ✱ **Normal bladder capacity & sensation** (1st sensation at 150 ml & max at 400 ml) ✱ **No involuntary detrusor contractions** ✱ **Urine leak on strain with no ↑ in detrusor pressure** ✱ **Pressure at rest** 5cm H_2O ✱ **Voiding pressure** 60-70 cmH2o If more obstruction	✱ ↓ functional length + ↓ closing pressure of urethra ✱ Valsalva leak point pressure (normally –ve) ✱ Static & dynamic (on series of cough) urethrometry

3- **Cystourethro-metry:** Combined simultaneous 1+2

4- **Uroflowmetry:**

✱ Assess occult voiding problem before surgery

✱ Measuring rate of urine flow through the urethra (Normal rate is 25-50 ml/sec)

✱ Patient is asked to urinate while sitting on special chair on revolving containers

Radiology:

- **Video-cystourethrography:** Loss of angle, bladder neck descent & funneling
- **Micturating cystourethrography:** to assess the angle, filling defects, fistula
- **U/S & transvaginal sonography with Echovist:** Position of bladder neck

Endoscopy: Urethroscopy, cystoscopy for any pathology (in SUI the bladder neck is opened on straining)

EMG: to evaluate any muscular or nerve damage.

Urodynamics

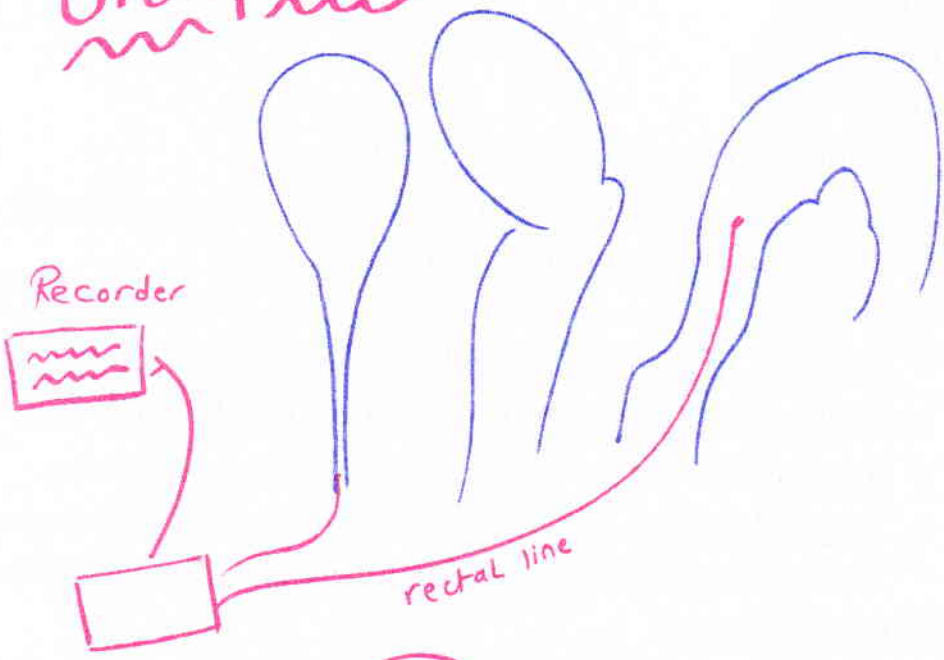

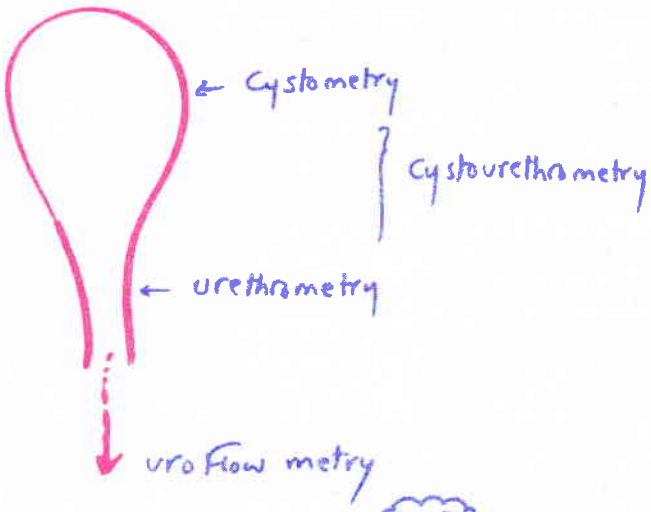

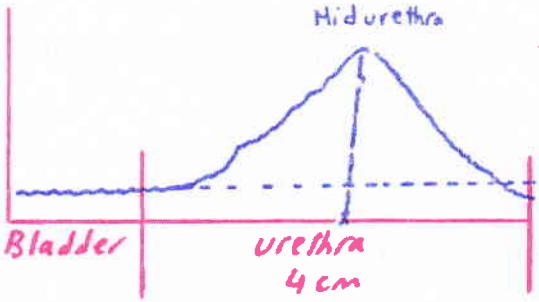

N.B.

- urethral closing pr
  = Intra urethral pressure − intra vesical "
- Functional urethral length (3-4 cm)
  = The urethral length along which The urethral pr. is exceeding bladder pressure

Treatment:

- **Prophylactic:** Good management of labor & postnatal exercises
- **Non-surgical:**
  - **Conservative:**
    - **Indications:**
      - Mild or Mixed SI (treat 1st DOA)
      - Too young (better postponed after delivery وممكن لا) or too old.
      - Refusal or contraindicated to do surgery.
    - **Options:**
      - Change life style (↓ weight, stop smoking)
      - Pelvic floor exercises, faradic stimulation
      - Drugs: ERT (oral or local) in post menopausal females
      - Vaginal cones: (20-100g) a set of cones with gradual increase in weight, inserted twice daily in vagina for 15 min.
  - **Surgical treatment:**
    - **Vaginal operations:** Kelly's sutures

- **Advantages:**
  - Easy, can be done under local anesthesia
  - Other gynecological operations can be done as prolapse
- **Disadvantages:**
  - Recurrence 50%
  - Vaginal narrowing
- **Procedure:**
  - 3 sutures in perivesical & periurethral fascia
  - Kennedy modification: sutures throughout the whole urethral length
- **Complications:** Bladder injury, hemorrhage, urine retention
- **Others vaginal measures:**
  - **Sphincteroplasty:** indicated after repeated failures as urethra will be short & destroyed by fibrosis
  - **Periurethral injections of GAX collagen:**
    - Injection of GAX collagen in submucosal layer of the bladder neck, leads to increased urethral closing pressure
    - Disadvantages: transient success, re-injection usually is needed

Summary of Treatment

- prophylactic
- palliative
- Surgery
  - preop
  - op.
    - Vaginal (3)
    - Abdomino Vag. (3)
    - Abdominal (2)
  - postop
  - Compl
  - Recurrence

The Best is Burch

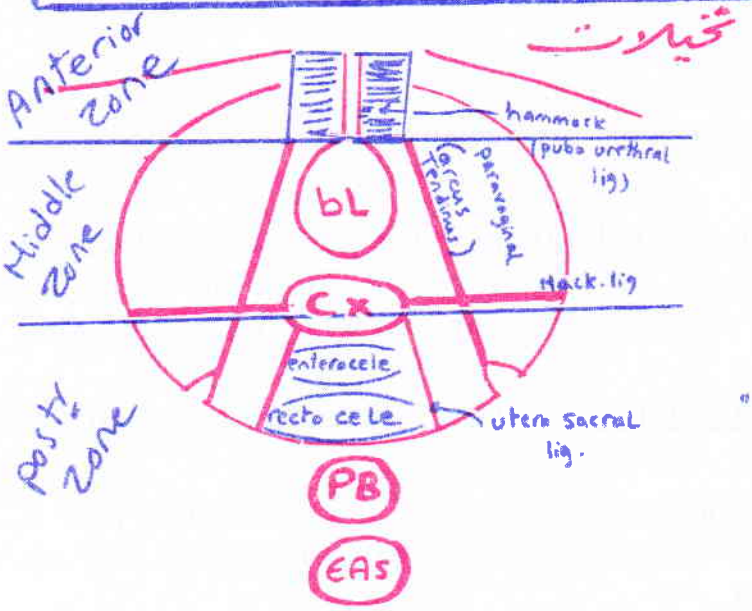

"Hammock effect of pubo cx Fascia"

- **Abdominal operations:** Burch & Marshal-Marchetti-Krantz operation:
  - **Advantages:**
    - Burch is the gold standard, 96% Success rate, used in recurrent cases
    - Other gynecologic operations can be done as hysterectomy
    - Can be done by laparoscopy
  - **Disadvantages:**
    - More difficult
    - Ostitis pubis (in MMK)
    - Enterocele (17%) as the vaginal axis is pushed anteriorly.
    - Urine retention if overcorrection
  - **Procedure:**
    - 3 sutures from ant. vaginal wall on bladder neck sides to the iliopectineal (Cooper`s) ligament (in Burch) or to the pubis (in MMK)
  - **Complications:** Bladder injury, hemorrhage, urine retention

- **Abdomino vaginal:** TVT, TOT & Bladder neck suspension
  - **Advantages:**
    - Simple, rapid, high success rate (90%), used in recurrent cases
    - Local anesthesia
  - **Disadvantages:**
    - Difficult, **expensive** اهم مشكله
    - Failure with time, tape erosion
    - Abdomino-vaginal, blind procedure
    - Urine retention, bladder injury (avoided by use of cystoscope)
  - **Procedure:**
    - **TVT (tension free vaginal tape):** a tape is suspended below urethra, pass it blindly on both sides till it appears from the anterior abdominal wall, tension is adjusted by pulling the needles up while straining
    - **TOT (transobturator tape):** the tape is introduced through the Obturator foramen
    - **Bladder neck suspension** مش في كتاب القسم **:** by a needle, pass a nylon tape from anterior abdominal wall to ant vaginal wall on both sides of urethra
  - **Complications:** Bladder injury, hemorrhage, urine retention

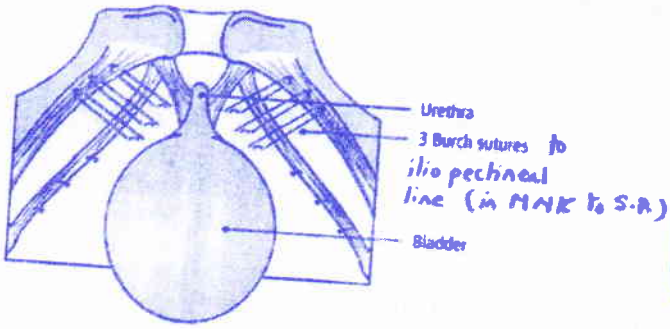

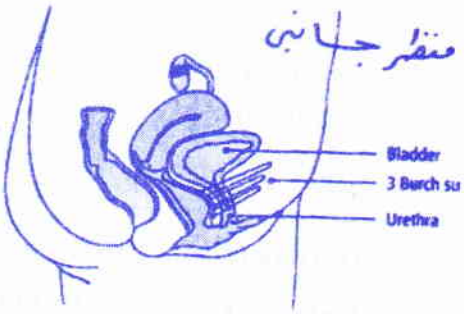

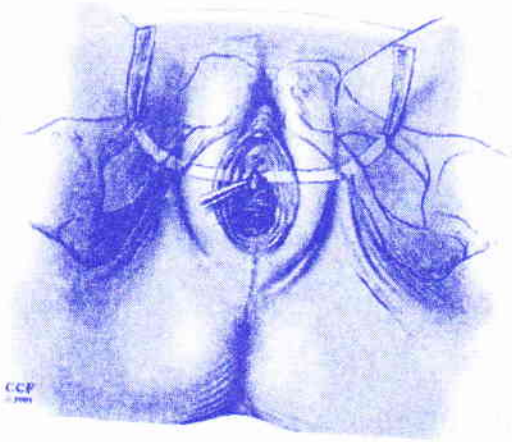

TOT procedure

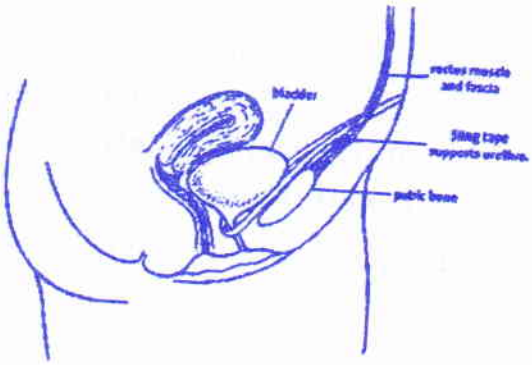

Figure 6-3: TVT PROCEDURE

TVT procedure

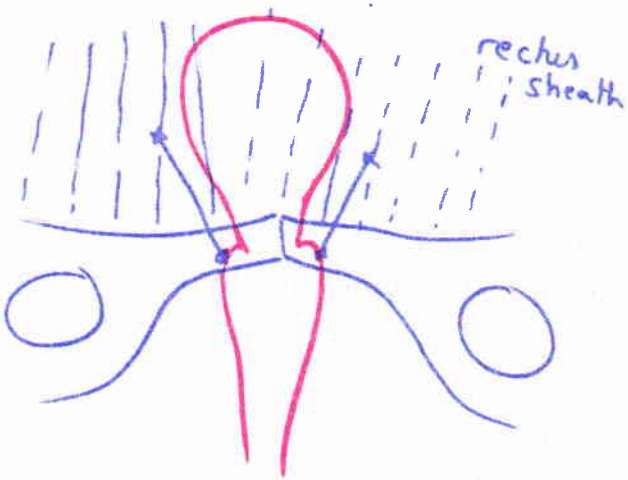

- Needle neck Suspension procedure:- Sutures From vagina to rectus sheath by a special long needle

Detrusor overactivity

Definition:

- Uninhibited contractions of the detrusor muscle leads to involuntary loss of urine.

Etiology:

- **Detrusor instability**: idiopathic & local bladder diseases
- **Detrusor hyperreflexia (neuropathic)**: strokes & parkinsonism

Clinical picture:

- Stress incontinence:
  - Large gush, after **few seconds after any stress**
  - **at orgasm (in intrinsic sphincter deficiency, SUI occurs at penetration)**
- Frequency (>6 by day) & nocturia (>2 by night) & urgency.

Investigations:

- **Cystometry** ده الاساس:
  - Systolic contractions on filling the bladder
  - Filling > 15 cmH2O provocates bladder contraction
- **Normal urethrometry** مهمه جدا
- **Cystoscopy**: calculi tumors
- **Urine analysis** for DM & any infection

Treatment:

- **Change life style:** ↓ fluid & caffeine intake
- **Bladder drills:** self training by trying to hold urine for progressively ↑ times.
- **Drugs:**
  - Anticholinergics (tolterodine)
  - Tricyclic antidepressant (steprine)
  - Ca Channel blocker (epilat)
  - Muscle relaxants (oxybutinin)

N.B. oral

- The Key Success in incontinence operations is proper positioning (Suspension) of bl. neck & not elevation.
- Abdominal operations have better outcomes than other approaches
- a common side effect of incontinence operations is **urine retention**
- TVT & Burch الاحسن على الاطلاق are of choice in Recurrence
- CS is the preferred route of delivery after incont. operations

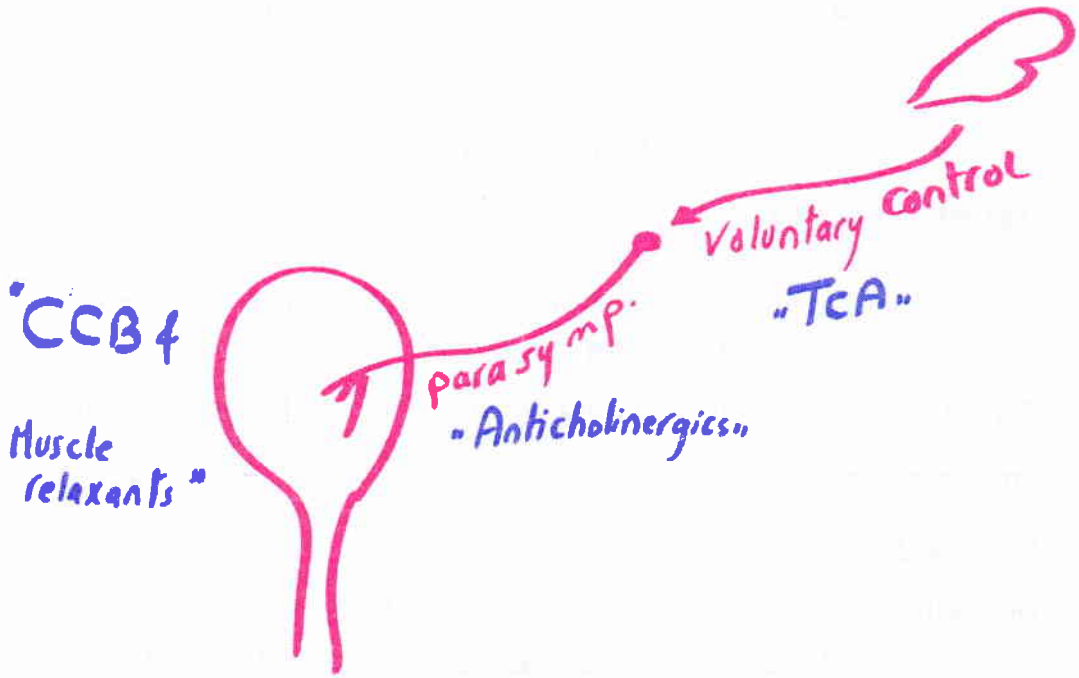

Genito urinary fistula

- **Definition:** it is an abnormal communication between the genital & urinary tracts
- **Types:**

1- Ureter	2- Bladder	3- Urethra
- Uretero - uterine - Uretero - cervical - Uretero–vaginal (2nd most common)	- Vesico - uterine - Vesico - cervical - Vesico - vaginal (commonest)	- Urethra - vaginal
There may be combinations as vesico – urethra – vaginal fistula		

Vesico-vaginal fistula

- **Definition:** it is an abnormal communication between the bladder & vagina
- **Causes:**
  - **Congenital**: persistent urogenital sinus
  - **Trauma**:
    - ⇨ **Surgical (commonest): → immediate incontinence**
      - ✱ **Gynecological operations**: vaginal hysterectomy, anterior colporrhaphy.
      - ✱ **Obstetric operations**: CS
      - ✱ More common in **developed** countries
    - ⇨ **Obstetric causes:**
      - ✱ Obstructed or prolonged labor → necrotic fistula appears in 7 days
      - ✱ Forceps or rupture uterus → incontinence appears immediately
      - ✱ More common in **developing** countries
    - ⇨ **Direct** as fracture pelvis, falling on sharp object, defloration (rare)
  - **Inflammatory** pelvic abscess rupturing in the bladder & vagina
  - **Neoplastic** as cancer vagina or bladder
  - **Miscellaneous** irradiation fistula → EAO → ischemic necrosis → sloughing → **large**, **very resistant to heal**, may **appear after years** from the irradiation.



" Types of Genital fistulas "

Clinical picture:

- Symptoms
  - **Incontinence of urine**
    - **True:** incontinence + no desire
    - **Partial:** incontinence + desire (high, small or valvular fistula
  - **Infections:** UTI, vulvitis & phosphatic encrustation
  - **Amenorrhea** (psychological, Sheehan, pregnancy, pills or the cause)
  - **History of possible cause of fistula**
- Signs
  - **General:** anemia or uremia
  - **Abdominal:** tender loin, scars of previous operations
  - **Vaginal:** (**fistula is seen in Sim's position by Sim's speculum**)
- Inspection:
  - Constant stream of urine
  - Red, excoriated vulva with phosphate deposition
  - Other trauma as perineal tear
- Palpation & PV:
  - **Fistula**: size, site, number
  - **Margin**: degree of fibrosis
  - **Mobility**: degree of mobility of the vaginal wall

Investigations

- Urine analysis, renal function tests & CBC.
- **IVP:** kidney functions, hydro ureter or nephrosis, Course of ureter
- **Methylene blue test** مهم جدا بكل تفاصيله
  - **Procedure:**
    - The vagina is packed with 3 gauzes. 200 cc of 1% methylene blue are injected in the bladder by sterile rubber catheter, which is then removed. The patient should walk 10 minutes.
    - The lowest gauze is discarded as it is stained during injection.
  - **It is the best test to diagnose fistula & must be done in every case.**
  - **Results:**
    - **In vesico-vaginal fistula,** the upper or middle gauzes are stained blue.
    - **In uretero-vaginal fistula,** the upper gauze is soaked with urine.
    - **If both pieces are dry,** incontinence is due to another cause (no fistula).

SIMS' SPECULUM (the duckbill speculum) is designed to hold back the posterior vaginal wall so that air enters the vagina, due to negative intra-abdominal pressure, and the anterior wall and cervix are exposed.



In this picture the patient is in Sims' position (semi-prone) which is useful if the anterior wall is to be studied (e.g. if fistula is suspected).

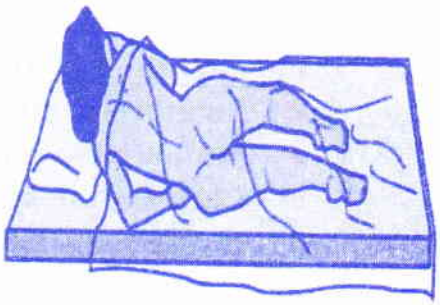

Sim's position.

oral

- Sims' position:- The pt lies on the left side with
  - Rt thigh & Knee Flexed
  - lt " " Extended
  - The pelvis is raised, so intestine is displaced from the pelvic floor & air distends the vagina.

Oral

- How to obtain urine sample from a patient with a fistula ?
  1- a catheter is fixed & the patient is kept lying on her face until specimen is obtained.
  2- obliterate the fistula by inflating a condom in the vagina
  3- collect directly from the fistula by special receptacle introduced into the vagina.

- **Cystoscopy** مهم جدا بكل التفاصيل :
  - For determining the site, size, number of the fistula & relation to the ureter.
  - For detection of associated bladder pathology as cystitis.
  - **For exclusion of ureteric fistula in which there is:**
    - **No ureteric efflux** on the affected side.
    - **If a ureteric catheter is passed,** it stops at the site of injury.
    - **Chromocystoscopy: IV Indigocarmine (4 cc 4%)**
      - **Normally** the blue dye appears at the ureteric orifice after 4 minutes.
      - It is also used for assessment of the kidney function.
- **Metal catheter** in bladder + sound in vagina → click
- **Examination under anesthesia**

Treatment

- **Prevention** "it is the most important part of management"
  - Evacuation of the bladder is essential before the following:
    - **Before labor**
    - **Before operations** as hysterectomy or CS.
  - Proper mobilization of the bladder during hysterectomy & CS
  - Injuries during surgery should be repaired & a catheter is left 10-14 days.
  - After successful repair of vesico-vaginal fistula, delivery by CS
- **Active**

A- Timing:

- **In cases discovered intraoperative**: immediate repair
- **Cases discovered later on** مهمه جدا:

  No operative intervention except after 3-6 months, this is due to:
  - Prepare the patient generally & locally
  - Resolution of edema, congestion & infection
  - The fistula may close spontaneously if small, or shrink in size

B- Preoperative preparation:

- **General**: Treat anemia, uremia
- **Abdominal**: UTI → antibiotics, acidifying agents
- **Local**:
  - **For urinary tract**: suprapubic cystostomy may be useful in some cases.
  - **For genital tract**:
    - **Ulcers**: short wave, hot douches to ↑ vascularity, silver nitrate
    - **Phosphatic encrustations**: dissolve by vit C or scrapping.
    - **Zinc oxide** or **Vaseline** to avoid irritation of the skin.

C- Operations

- **Vaginal repair (preferred route)**
  - **Dedoublement (Flap splitting operation) the most preferred**
    - The patient is put in the elevated lithotomy position, general anesthesia
    - A circular incision is done in the vagina around the fistula
    - The vagina is dissected from the bladder& the fistula is excised.
    - The bladder is closed in 2 layers by interrupted 3/0 delayed absorbable sutures e.g. vicryl. Sutures should not pierce the mucosa to avoid infections ± methylene injection in the bladder to ensure closure
    - The vagina is closed by interrupted sutures.
  - **Saucerization (Sim's operation)**
    - The fistula is excised removing a wider part of the vagina > bladder
    - The edges of the bladder & vaginal opening are sutured together.
    - It is usually reserved for cases with excessive fibrosis.
  - **Latzko operation (For vault fistula)**
    - The upper part of the vagina is removed.
    - The hole in the bladder closed 1st followed by closure of the vagina
- **Abdominal repair:**
  - **Indications:** high, inaccessible vaginally or failure of vaginal repair.
  - **Types**
    - Intraperitoneal, either trans-vesical or extra-vesical.
    - Extraperitoneal, either trans-vesical or extra-vesical.
- **Post irradiation fistula:** bulbo-cavernosus flap is used
- **If malignant fistula:** anterior exentration

Schuchardt incision: (mediolateral like episiotomy) is done for better exposure

D-Postoperative care

- **Catheter care:**
  - Observe /2hours for amount, color & reaction to urine:
  - **No urine passes through the catheter for 2 hrs either:**
    - Blockage of catheter (by blood clot or phosphate deposits) is managed by gentle injection of saline or replacement of catheter
    - Anuria
  - **Bloody urine:** Silver nitrate 1% is injected through the catheter
  - The catheter is removed after 10-14 days & urination every 2 hours by day & 4 hours by night to avoid distension.
- **Vagianl pack** for one day, Antibiotics, fluid at least 3 L/d
- **Coitus is** avoided for 2m & no pregnancy for 2y "delivery by USCS"

Dedoublement op. اصعب عملية

"vaginal route"

"Key step"

vag from bl. تفصل

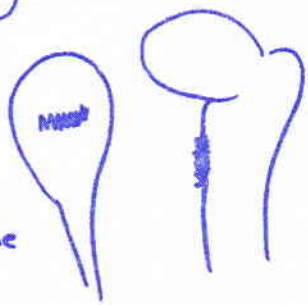

suture The vag بالطول

suture The bl. بالعرض

Sauceri zation الطبيه (Sims' op.)



vagina

bl. (غالبيه) قوى

Freshening of edges مرناصيه بس vag.



شبه طبيعه ومرهنا مرسم

غرزه واحده ونقفل Fistula (بتخيط vag + bl. مع بعض)

Lat zko operation ٢ خطوات

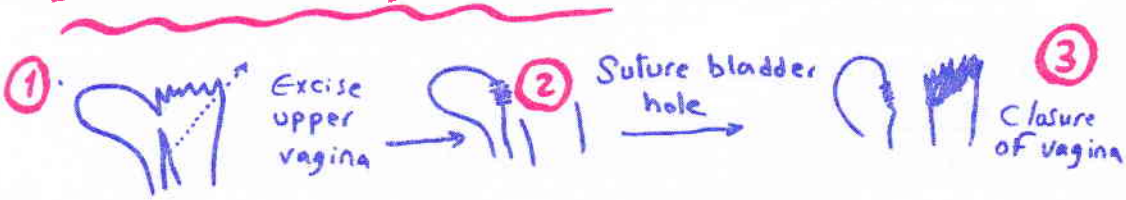

Recurrent fistula

- **Causes of recurrent fistula "Causes of failure of the operation"**
  - **Pre-operative causes:**
    - Infection or friability of the tissue if 3-6 months are not awaited.
  - **Intra-operative causes:**
    - Faulty surgical technique e.g. tension on the suture line.
    - Bad choice of the operation.
    - Improper suture material (the best is polyglycolic acid = Vicryl)
  - **Post-operative causes:**
    - Blockage of the catheter
    - Post-operative infection or hematoma.
- **Treatment:** it is done 3-6 months after the first repair
  - If failed **vaginal repair, abdominal repair** is tried.
  - If repeated failure, **colpocliesis** (closure of the vagina) after menopause.
  - **Uretrocolic implantation** (ureter implanted into sigmoid colon),
    - ★ **Disadvantages**: ascending infection, stricture, hypercholaermic acidosis
  - **Ileal conduit**: ureter implanted into loop of ileum then to skin

Uretero - vaginal fistula

- **Cause:** As vesico vaginal fistula (commonest after hysterectomy)
- **Clinical picture:**
  - **Symptoms:** either true or partial incontinence (if unilateral ureteric fistula)
  - **Signs:** -ve methylene blue with soaking of the gauzes
- **Investigations:**
  - **Cystoscopy** & indigo carmine: efflux only from healthy side
  - **Ureteric** catheterization ...blocked pathway
  - **IVP** ...unilateral hydroureter +hydronephrosis
- **Treatment:**
  - **Ureteric repair**: end to end anastomosis, end to side anastomosis, Reimplantation
  - **If short ureter**: replace the defect by ileal loop or rolled up flap of the bladder
  - **If high fistula**: Ureterocloic implantation
  - **Nephrectomy** if the kidney is infected with impaired function

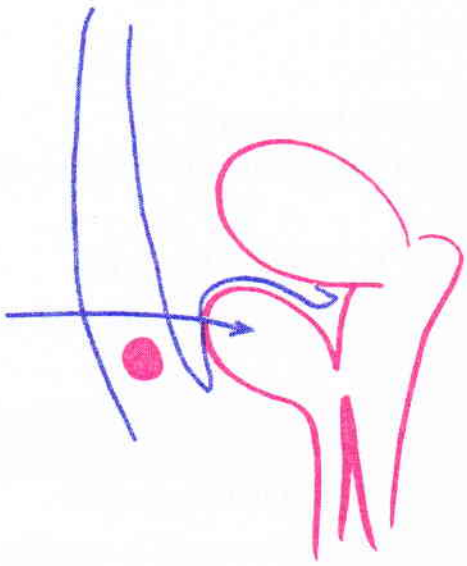

Transperitoneal
Transvesical
Approach

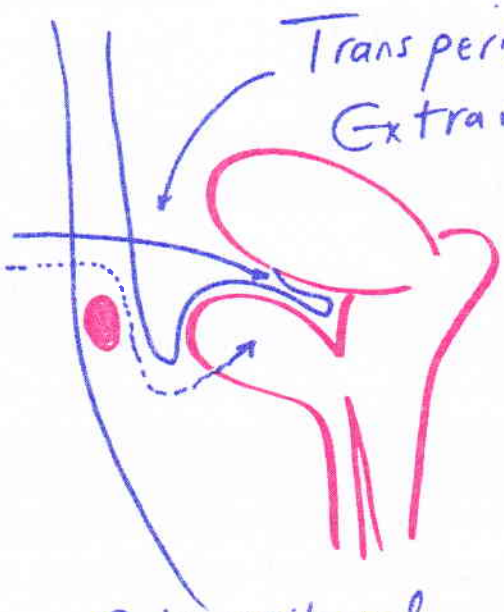

Extraperitoneal
Transvesical.

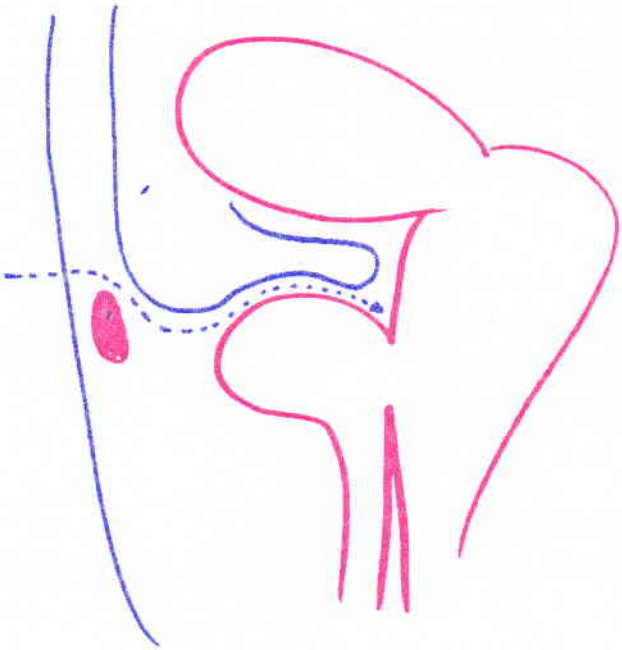

Extraperitoneal Extravesical
approach.

Utero - Vesical fistula

- **Cause:** usually CS
- **Clinical picture:**
  - Menuria **(YOUSSEF SYNDROME):** cyclic hematuria
  - No incontinence (as the uterus is higher & sphincteric effect of the cervix).
- **D.D.**: bladder Endometriosis of **(cystoscopy is differentiating).**
- **Treatment:** Abdominal repair **or** OCPS to induce amenorrhea for 6 months.

Urethrovaginal fistula

- The patient is **continent** but during micturition → **bifid urine** خطين بول
- **Treatment:** Urethral reconstruction (if markedly destroyed a vaginal flap is used)

Fecal fistula: 1- Recto vaginal fistula

- **Causes**
  - **Congenital**: ectopic anus
  - **Trauma**: surgical or obstetric or direct
  - **Inflammatory**: pelvic abscess
  - **Neoplastic**: tumors
  - **Miscellaneous**: irradiation
- **C/P :**
  - **Symptoms**:
    - Incontinence to stool & flatus
    - Vaginal feculent discharge
  - **Examination**: my be felt by P/R
- **Investigations:**
  - Proctoscopy, proctosigmoidoscopy
  - Barium enema or oral charcoal & look for it in the vagina.
- **Treatment:**
  - **Prophylaxis:** proper management of labor, repair of peritoneal tear.
  - **Preoperative preparation (for 3 – 5 days)**
    - Enema 2-3 times daily & low residue diet
    - Antibiotics to ↓ rectal flora as neomycin + flagyl, vaginal antiseptic douches

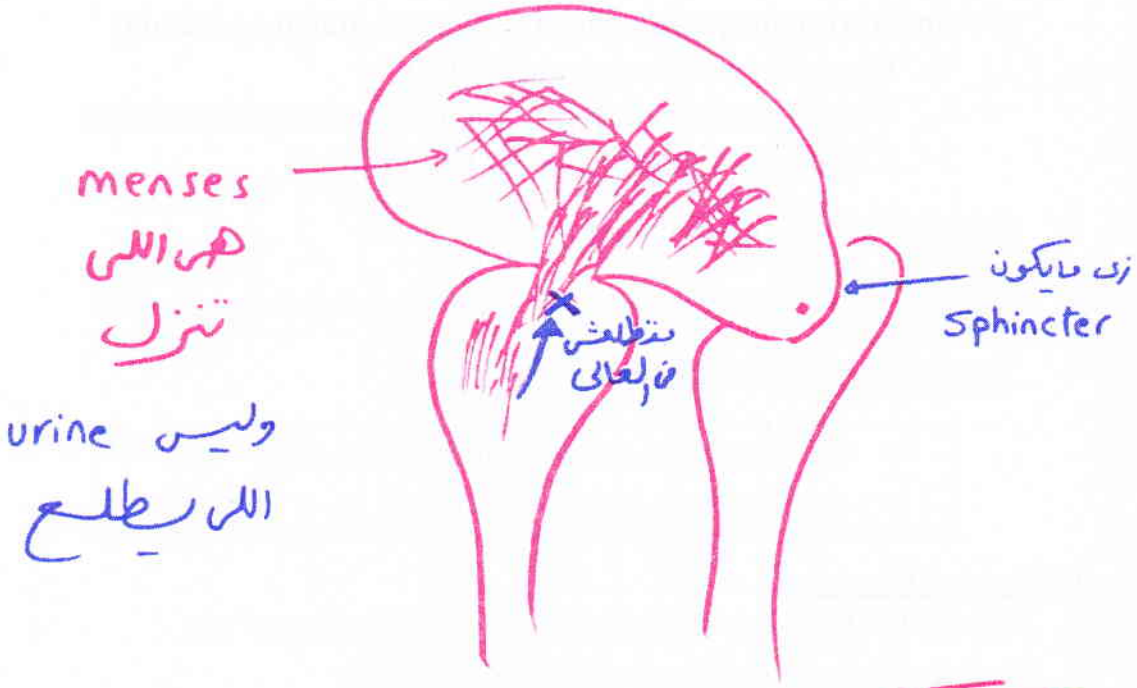

"YOUSEFF Syndrome"

تحيا مصر

- **Operative:** 3-6 months after delivery
  - **Lower 1/3:**
    - **Large with deficient perineum (Lawsaon Tait operation)**
      1- Transform fistula into complete perineal tear
      2- Complete steps as usual
    - **Small with adequate perineum (Vernon-David operation)**
      1- Circular incision around fistula
      2- Fistula tract is dissected & inverted into the rectum
      3- Close in layers; rectum & vaginal wall
  - **Middle 1/3:** Dedoublement
  - **Upper 1/3:** abdominal repair ± colostomy, close colostomy after 2 m
  - **Vaginal vault:** Latzko repair

  - **Malignancy:** exentration + colostomy
  - **Irradiation:** bulbo-cavernosus fl

- **Post operative care**
  - NPO for 48 h then low residue diet for 3 days, paraffin oil on 5th day
  - Oral & systemic antibiotics (metronidazole).
  - Avoid enema, intercourse for 2 m & pregnancy for 2 years.
  - Vaginal delivery may be allowed in some cases with generous episiotomy.

2- Intestino - uterine fistula

- The disease usually in the bowel (TB or malignancy or diverticulitis)
- **Symptoms:** **Feculent discharge**
- **Treatment:** Hysterectomy + bowel resection

3- Tubo intestinal fistula

- Usually with tuberculous pyosalpinx
- **Symptoms:** feculent discharge is unusual due to tubal obstruction.
- **Treatment:** rarely needs Treatment

4- Vagino perineal fistula

- **Due to** unhealed perineal tear
- Usually asymptomatic & needs no treatment.

ONCOLOGY

TUMORS OF UTERINE BODY التقسيمه مهمه

- **Benign:** leiomyoma, adenomyosis, adenoma, adenofibroma, angioma,
- **Malignant:**
  - **1ry:** endometrial carcinoma, sarcoma, mixed Mullerian tumors (carcinosarcoma)
  - **2ry:** from genital or extragenital malignancies

FIBROID (LEIOMYOMA الاسم الاصح)

- **Definition:**
  - A benign tumor of the myometrium
  - It is due to hyperplasia of smooth muscle fibers & fibrous tissue
  - It is commonly called fibroid as it contains CT fibers as well
- **Incidence نسب المحاضرات مهمه:**
  - **20% of female** (commonest benign tumor but most of them are asymptomatic).
  - **77% of uteri** after hysterectomy contain fibroids.
  - Cause **40%** of abdominal hysterectomy & **17%** of vaginal hysterectomies.
- **Etiology is unknown but risk factors are:**
  - **Age:** between 30-40 years.
  - **Race:** More in Negroids may be due to genetic factors
  - **Parity:** nullipara or low parity.
  - **Hyper-estrogenemia:**
    - The most important risk factor
    - Rare before puberty or after menopause
    - Contains estrogen receptors > surrounding myometrium☺® مهمه
  - **Exact histogenesis:**
    - **May be from مهمه جدا:**
      - Embryonic myoblasts or
      - Adult smooth muscle cells, fibroblasts
      - Adventitia or media of blood vessels
    - The growth then, becomes estrogen dependent
    - It usually starts as a pure myoma
    - Then more fibrous tissues are deposited → Firm consistency

Q: oral what are the hyperestrogenic states

- Tumors:-
  - Benign:- Fibroid
  - Malignant:- end. hyperplasia & c
- Others:-
  - DUB
  - PCO
  - endometriosis
  - Precocious puberty

Pathology (MAC: 4S BNC3 & MIC):

Sites:

- **Uterine 99%:**
  - **Corporeal (95%):** Intramural 60%, subserous 20% or sub mucous 15% ,
    - **All fibroids start as interstitial then grow either**
      - Towards the peritoneal cavity (subserous & pedunculated subserous). **Rarely** it attaches to a nearby structure & takes its blood from it → parasitic fibroid
      - Or into uterine cavity → submucous & pedunculated submucous. **Rarely**, it protrudes from cervix & vulva to outside → polyp
    - **The nearer to the uterine cavity**, the more symptoms regardless its size
  - **Cervical (4%):**
    - **Starts** & **remains** in the wall → pressure (post, ant, lat) or
    - **Bulges** to cervical canal (barrel shaped) or through ectocervix → polyp
    - **Grows faster** > corporeal fibroid & presents with pressure symptoms.
- **Extra-uterine sites 1%:** ligaments or extra-genital as intestine, vagina or vulva

Size: may be microscopic (seedling → recurrence) or huge size (over 10 kg)

Shape: spherical, becomes flattened if compressed by surrounding organs

Cut section:
- **Whorly** دوامات in appearance (interlacing fibrous & muscle tissues)
- **Paler** than the surrounding (relatively poor blood supply)

Consistency:
- **More firm** than surrounding myometrium.
- **Soft:** in pregnancy, cystic changes, vascular, inflammatory
- **Very soft (brain like)** in malignant change
- **Hard** in calcification (womb stone).

Capsule: the capsule is formed of 3 layers راي مهم
- **Outer**: compressed normal muscles, it is false capsule فيه راي ان هو ده الوحيد
- **Intermediate layer:** CT, blood vessels ramify in it
- **Inner layer:** outer layer of the tumor

Number: solitary or multiple (may be hundreds)

Blood supply: either through
- **The capsule** (center is the least vascular) or
- **The pedicle** (the tip is the least vascular)

pathology تجميعة ال

"4 S B N. C 3"

L. sup.

site — size — shape — 2ry changes — Capsule — Cut section — consistency

Site

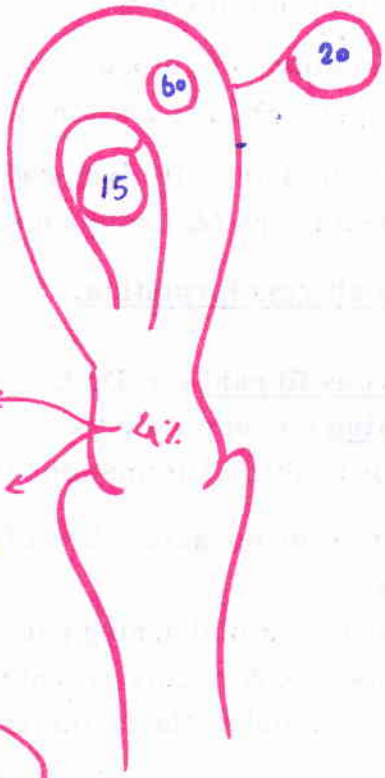

1% of uterus

× endo cx → Barrel shaped جميل.

× ecto cx → polyp

Cut section

whorly

Lost in:
- hyaline, pseudocystic deg
- Red degeneration
- inflammatory changes
- Sarcomatous change
- Calcification

Capsule

False (طبقة واحدة) → Compressed surrounding normal Tissue

3 Layers



Compressed Tr cells

True CT capsule.

⇨ Secondary changes:

1- Vascular changes:

A. Torsion:

- **Occurs** in medium pedunculated subserous fibroids (with no adhesions).
- **Predisposed** by trauma, sudden change in posture or pregnancy
- **Maintained** by lashing كرباج effect of vascular pulsations
- **C/P:**
  - **Acute torsion**: acute abdomen → vomiting & collapse
  - **Gradual torsion**: parasitic fibroid

B. Telangiectasia: dilatation of blood vessels in pregnancy or malignant change. If rupture → intra-peritoneal hemorrhage.

C. Lymphangiectasia: dilatation in lymphatics in menopause. If rupture → intraperitoneal lymph (& dense adhesions).

2- Inflammatory changes & abscess formation:

☆ **Ways of infection:**

- **Trauma to submucous fibroid** e.g. D&C
- **Near by inflammation** e.g. appendicitis
- **Blood borne** →leads to abscess formation

3- Degenerations: common near menopause + loss of whorly appearance

☆ **Hyaline degeneration**

- Commonest 2ry change☺ → dull aching pain
- It starts around menopause & occurs in center.
- Homogenous waxy material replaces the center + loss of whorly appearance.

☆ **Myxomatous (pseudomyxomatous) change:**

- Near menopause
- Occurs in the center of myoma
- Gelatinous mucoid material replaces the central part

☆ **Pseudo cystic degeneration**

- Follows the hyaline or myxomatous degeneration.
- The central part liquefies (very soft tumor resembles gravid uterus)

☆ **Fatty changes**

- Occurs at menopause.
- Start at the periphery (precipitation of lipids in the blood vessels)→ yellow & soft fibroid

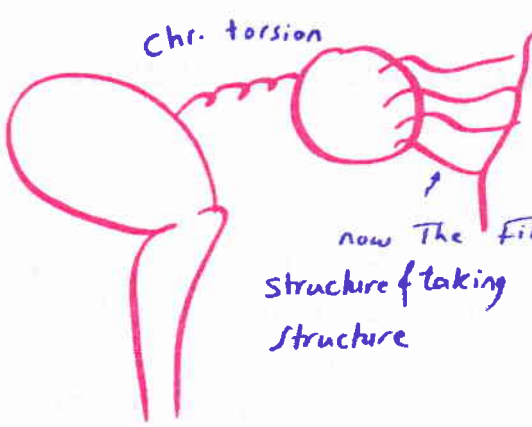

"Parastic Fibroid"

now The Fibroid is attached to another structure & taking its blood supply from This structure

Telangiectasia

if rupture

IPH

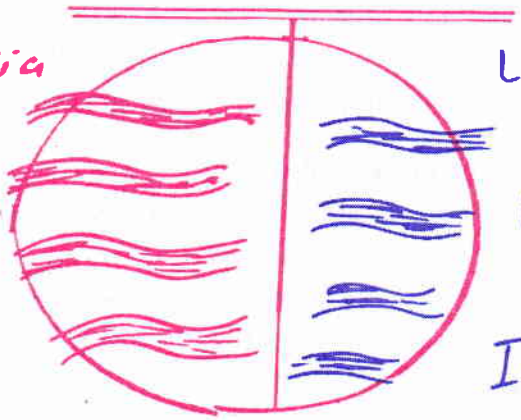

Lymphangiectasia

if Rupture

I.P lymph & adhesions

D.D. of Fibroid Fixed to surrounding tissue:-

1- previous myomectomy or surgeries
2- chr. PID
3- Mal. change
4- parasitic Fibroid
5- lymphangiectasia
6- Associated endometriosis

- **Calcification**
  - Follows fatty changes.
  - It becomes hard **(womb stone حجر الرحم),**
  - Radio opaque **(onion skin appearance or Egg shell appearance)**
- **Atrophy:**
  - After menopause, never complete.
  - Absent ® in calcification, HRT or malignancy
- **Red degeneration** (necrobiosis): dead (central) & living parts (peripheral).
  - Common in midtrimester of pregnancy or high dose MPA
  - ↑ Vascularity + hypercoagulable state → venous obstruction & hemorrhage into the fibroid → the tumor enlarges & becomes red.
  - **C/O** severe pain, tenderness, vomiting, fever (absorption of Hb).
  - **Treatment:**
    - Bed rest, fluids, antibiotics
    - Pain killers, analgesics (anti PG), antipyretics, steroids
    - Surgery if failed medical treatment → remove only affected one

4- **Malignancy (0.5% leiomyosarcoma)®:**

- The association of endometrial carcinoma > sarcoma
- **Symptoms**
  1- Rapid growth or Rapid recurrence after removal.
  2- Postmenopausal growth or bleeding
  3- Presence of pain & cachexia.
- **Signs:**
  - **General**: Cachexia, tenderness, LN metastasis
  - **Local**: Fixation, Rapid growth.
- **Investigations:**
  - **During laparotomy**
    - Infiltration of the capsule.
    - Very vascular, yellowish, soft (brain like)
    - Hemorrhage, infarction, necrosis & degeneration.
  - **Biopsy:** Mitotic figures >10/10 HPF

Microscopic picture :

- Interlacing muscle & fibrous tissues in concentric manner
- Mitotic figures less than 5 /HPF
- Stained with Van Geison stain: muscle (yellow or green), fibrous tissue (pink)

Symptoms:

- **Most important factor is the site not size®**
- **Asymptomatic** most common presentation☺, especially if small or subserous
- **Bleeding:** Most common → easy fatigability, dyspnea, palpitation,
  1. **Menorrhagia** أهم واحده
     a. ↑ Size & vascularity pelvic congestion),
     b. Underlying hormonal imbalance, associated endometrial hyperplasia
     c. Surface ulceration from a submucous fibroid
     d. Interstitial: acts as foreign body prevents full contraction to ↓ blood Loss
  2. **Metrorrhagia** (ulcerated polyp, Endometrial CA, sarcomatus changes)
  3. **Polymenorrhea** (ovarian congestion),
  4. **Contact bleeding** (cervical polyps)
  5. **Postmenopausal** (suspect malignancy especially endometrial carcinoma)
  6. **Amenorrhea** is never a feature → suspect pregnancy.
- **Pain**
  - **Acute abdomen** → in red degeneration, inflammations malignancy or torsion
  - **Congestive dysmenorrhea,**
  - **Spasmodic dysmenorrhea** as fibroid stimulates uterine contraction.
- **Discharge:**
  - **Leucorrhea** due to pelvic congestion → increase cervical mucous,
  - **Mucopurulent** (infection) & Bloody in malignancy
- **Pressure symptoms (4 D):**
  - **Bladder**: frequency
  - **Urethra**: dysuria, retention
  - **Ureters:** displaced, rarely obstructed
  - **Pelvic veins**: edema, varicosities
  - **Abdominal viscera**: dyspepsia, dyspnea, palpitation if large
  - **Pelvic nerves** are only affected in sarcoma
- **Mass:** Either abdominal (in large fibroid) or vaginal polyp.
- **Infertility:**
  - **Anatomical defects:** **tube** → submucus obstructs the ostia or subserous stretching the tube, prevent **implantation**, cervical fibroid obstructs the **canal.**
  - **Functional defects:** hormonal imbalance or associated endometriosis.
- **Recurrent abortion:** **submucus** → space occupying lesion (before myomectomy 40% & 20% after myomectomy)

oral

The symptom may indicate the site :-

- if the main symptom is pressure
  → Cervical.
- if Rapidly growing → Cervical
- if main sympt is bleeding
  Submucous > interstitial (Meno اكثر)
  (Metro اكثر)
- " " " " pelvi abd mass
  Sub serous Fibroid

Signs:

General:

- **Most common**: Anemia due to bleeding
- **Very rare**: Polycythemia due to pressure on renal veins or **ERYTHROPOIETIN** production by the tumor.
- **Very rare**: Hypoglycemia due to ↑ insulin release by pancreatic pressure (large fibroid)

Abdominal examination:

- **If large** → pelviabdominal mass which is usually firm, mobile, not tender
- **On percussion**: dull
- **Auscultation:** uterine souffle may be heard

PV:

- Mobile with movement of CX, not tender, firm بالاحساس والحركه طالع من الرحم
- **Uterus:** symmetrically or asymmetrically enlarged
- **Cervical** tumors or polyps
- **Speculum**: may see a fibroid polyp protruding from cervix

D.D

i. **Large fibroid: from pelviabdominal swelling**

1. Normal pregnancy.
2. Vesicular mole.
3. Hematometra, hematocolpos & pyometra.
4. Ovarian cyst or tumor.
5. Hydrosalpinx, encysted TB peritonitis.
6. Broad ligamentary cyst.
7. Full bladder, retroperitoneal tumors.

ii. **Submucous or single fundal interstitial fibroid from causes of symmetrically enlarged uterus:**

1. Pregnancy, subinvolution
2. Metropathia hemorrhagica
3. Diffuse adenomyosis
4. Pyometra & hematometra
5. Malignant tumors

iii. **Small subserous fibroid: from a mass in Douglas pouch** سؤال فى الازهر

1. Retroverted uterus (commonest).
2. Hydro or pyosalpinx
3. Ovarian swelling (e.g dermoid cyst)
4. Pelvic hematocele or abscess
5. Encysted TB peritonitis, Endometriosis.

oral N.B

in PV Ex, The Fibroid is

- Firm (soft if pregnancy, degenerations, Malignancy)
- Mobile (Fixed if ??)
- Not Tender (Tender if Torsion, red deg, INFL., Mal. changes)

iv. **Submucous fibroid polyp: from a mass protruding from the cervix**
   1. Cervical or corporeal polypi
   2. Inversion of the uterus
   3. Inevitable & incomplete abortion.

v. **Broad ligament fibroid: from broad ligament swelling:**
   1. Cyst or hematoma
   2. Parametritis
   3. Hydro or pyosalpinx.

vi. **Symmetrical & asymmetrical enlargement of uterus**

vii. **Acute abdomen**

viii. **Causes of anemia**

Investigations:

For diagnosis

- **Radiology:**
  - U/S: accurate, noninvasive, for site, size, number & associated pregnancy.
  - X-ray (calcification), HSG (for filling defects), CT and MRI.
- **Endoscopy:** Laparoscopy, hysteroscopy.

For complications:

- HSG or HYCOSY (Sonohysterography): for tubal patency & medico legal
- D&C for associated end. hyperplasia (esp. in postmenopausal bleeding).

Preoperative investigations:

- CBC, RFT, LFT and chest X-ray.
- IVP → Cx or broad ligamentary fibroid.

Complications:

- **P**athological (secondary) changes (mention)
- **P**regnancy complications (abortions or preterm labor).
- **P**rolapse & chronic inversion.
- **P**ressure manifestations (4D'S).
- **2 Common complications**: Infertility 1/3 cases, anemia.
- **2 Rare complications**:
  - Pseudo-Meig's syndrome in large subserous fibroids,
  - Polycythemia & hypertension due to erythropoietin.

Treatment

According to:

- Age, parity and if desire pregnancy
- Site --- size --- number of fibroid or malignant changes.
- Patient refusing or unfit for surgery.
- Associated pregnancy

1) **No treatment:** asymptomatic, small (< 5 cm) & perimenopause (follow up/ 6m).

2) **Medical treatment**
   - ☆ Vitamins, minerals & correct anemia.
   - ☆ **GnRH** for 3 m (not for long time for fear of osteoporosis) ↓ size by 50%.
   - ☆ **Antiestrogens, danazol** & progestins (recently ↑ fibroid size ☺).
     - **Indications**:
       - If the patient refuse surgery or unfit.
       - If young age or near menopause with mild symptoms & signs
       - Preoperative preparation
   - ☆ **In pregnancy:** red degenerations (antipyretics, analgesics & anti-emetics).

3) **Surgical treatment:**

✱ **Indications:**
- In symptomatic cases or uterine size > 12 weeks.
- Infertility
- Multiple huge fibroids or suspected malignancy.

✱ **Type of surgery:**

☆ **Conservative: Myomectomy (prepare blood & consent hysterectomy)**
- Young patients
- Who desire pregnancy tubes should be patent known by HSG
- Small number of fibroids
- Rarely if medical ttt of red degeneration fails

☆ **Radical: Hysterectomy (most common operation performed)**
- Old (40 years), completed her family or sterility
- Large number, broad ligamentary or cervical or malignant change
- Recurrence after myomectomy or uncontrollable intraoperative hge
- Easier than myomectomy
- Less blood loss & less mortality &morbidity

☆ **CS hysterectomy** in old patients with multiple fibroids

Treatment تجميع ال

1. No Treatment بشرط شروط
2. Medical امتى وازاى
3. Surgical امتى

New lines للاوائل
old lines انسى

ازاى

Myomectomy — hysterectomy

1- ind
2- CI
3- Types
4- compl
5- How to ↓
   - Intraop bleeding
   - postop adhesions

Measures to ↓ bleeding in myomectomy (more bloody than hysterectomy)

- **Preoperative:**
  - Post menstrual, GnRH for 3m preoperative → ↓ vascularity
  - Corrects anemia, prepare blood.
- **Intra-operative:**
  - Temporary occlusion of uterine artery by Foley's catheter or Bonney's myomectomy clamp, assistant hand for short period.
  - Temporary occlusion of ovarian artery by ring forceps in infundibulo-pelvic ligament.
  - Midline anterior uterine incision is the least vascular.
  - Do the least possible incisions & tunneling to bring myoma.
  - Meticulous ممل دقيق closure if the bed of the tumor
  - Methergine 0.25 mg IM, ADH (20 IU in 20 ml saline) in tumor bed.

Measures to ↓ adhesions after Myomectomy:

- Least possible incisions.
- Plication of the round ligaments to ↑ AVF position.
- Corticosteroids, dextrose, ringer lactate, & heparin intra-abdominal
- Avoid posterior wall incision (do Bonney's hood operation or transcavitary but if difficult → direct approach is done).
- Perfect hemostasis

Complication of myomectomy:

1. **Persistence of symptoms** e.g. bleeding due to ↑ uterine size, tumor recurrence, underlying hormonal imbalance.
2. **Recurrence: 10-15% within 10ys (missed fibroids or new fibroids).**
3. **Intra operative bleeding.**
4. **Intrauterine (Asherman`s syndrome) or intra-abdominal adhesions.**
5. **Rupture in next pregnancy.**

Contraindications of Myomectomy:

- Conditions that need hysterectomy as malignancy.
- Inadvisable in patients who doesn't need pregnancy.

Types of Myomectomy:

- **Abdominal approach** (conventional)
- **Vaginal:** if fibroid polyp < 8 weeks pregnancy size.
- **Laparoscopy:** if small subserous with less hospital stay.
- **Hysteroscopy:** if small submucous (< than 5 cm)
- **D & C polypectomy:** if submucous polyp

anemia

preop – GnRH

post menstrual
or
after delivery by
3 – 6 m

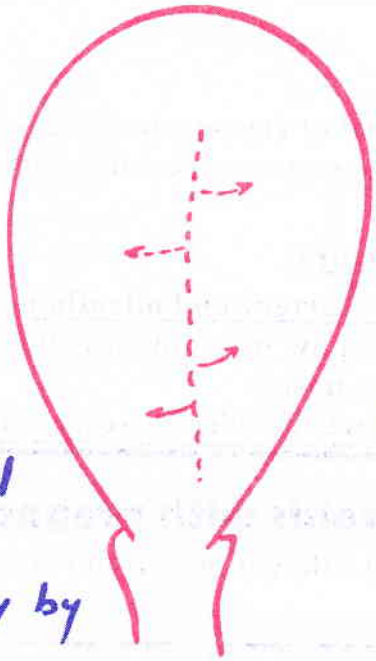

0 incisions

2 [illegible]

2 M

" How to ↓ Intraop bleeding "

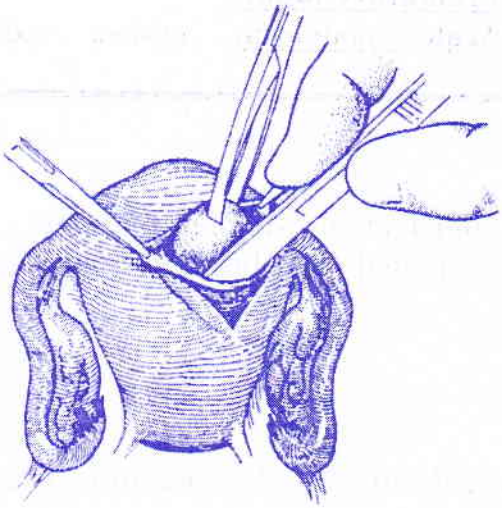

Removing a solitary fibroid.

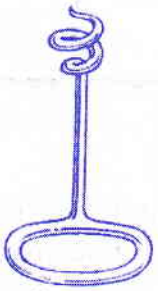

Myoma screw can be used to steady fibroid

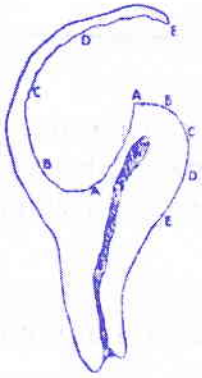

The capsule is left after enucleation

The 'hood' in place.

Bonney hood op for post wall fibroids

- **Old lines:** irradiation to induce artificial menopause → lead later to malignancies
- **New lines:**
  - **Myolysis**: thermal or cryo-cautery via laparoscopy
    - **Disadvantages**: extensive adhesions, rupture uterus in next pregnancy
  - **Anti growth factors**.
  - **Bilateral uterine artery embolization**: via fluoroscopic directed angiography, injection of gelfoam (polyvinyl alcohol) → 50% decrease in size
    - **Disadvantages:** bladder necrosis & fistula

Fibroids with pregnancy

- **Incidence:** 1/100 to 1/200 but only 1/800 is symptomatic
- **Effect of fibroid on pregnancy:**

Early	Later
Abortion (esp. submucous) **Ectopic pregnancy** (stretch of tube) **Incarcerated RVF gravid uterus**	**Pressure manifestations:** 4D"S. **Malpresentations & non engagement.** **Premature labor.** **Acute abdomen:** torsion, red degeneration

- **Effect on labor**
  - **1st stage** → inertia.
  - **2nd stage** → obstruction if cervical, impacted or Malpresentations.
  - **3rd stage** → Retained placenta {implanted on fibroid (accrete) or
- **Effect on puerperium**
  - 4S, Inversion of uterus.
- **Effect of pregnancy on fibroid**
  - ↑ **Hormones** → ↑ size & vascularity & degeneration (Red degeneration).
  - **Complications** as torsion or Hge in sub serous fibroid.
  - **Sub mucous fibroid** may be traumatized or extruded.
- **Management in pregnancy (CONSERVATIVE MAINLY)**
  - **In pregnancy:**
    - **No myomectomy**
    - **Red degeneration**: bed rest, antipyretics, analgesics, no Myomectomy except:
      - If torsion or hemorrhage from subserous fibroid.
      - Red degeneration if failed medical treatment (rare)

للعلم بالشيء

N.B. polypectomy & D&C (For submucous Fibroid polyp)

- using ring Forceps or volsellum to catch the polyp
- Twist several times to Kink the pedicle & cut Bl. supply
- Then D&C is done for hypeplastic end. to (↓bleeding post op & Exclude CA) لازم

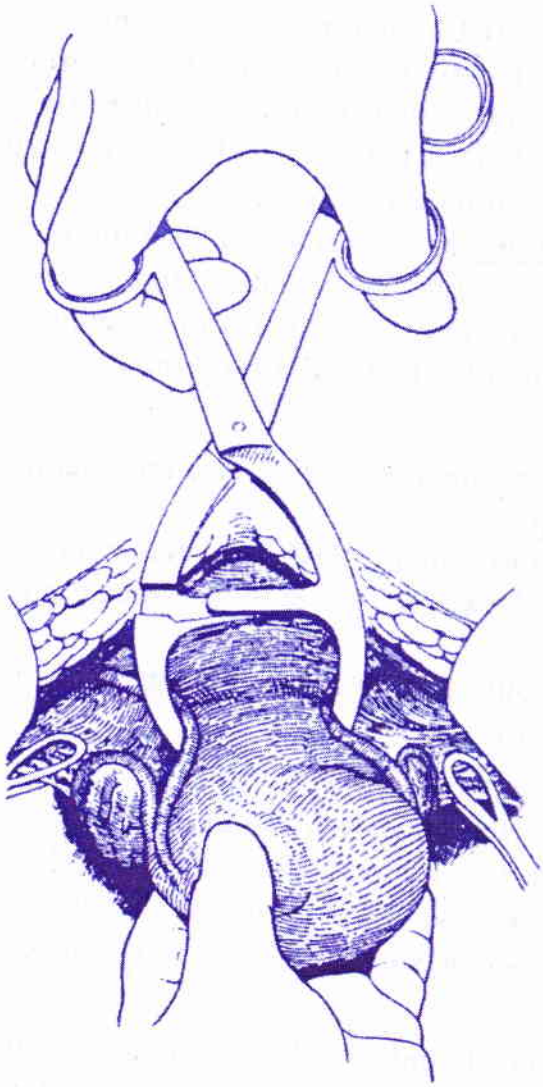

Bonney's myomectomy clamp applied to the lower

- **In labor**
  - **No obstruction** → allow vaginal delivery.
  - **Obstruction** → CS (no Myomectomy unless if pedunculated subserous
  - **If old patient** → Caesarean hysterectomy.
  - **Myomectomy** should not be done except after 6 months.
- **In puerperium:** myomectomy done after 3-6 m, myomas will be less vascular

Special fibroids ® مهمه

I-Cervical fibroid (4%)

- **Pathology:** site (see before), usually single
- **Symptoms:** mainly pressure $ (esp acute urinary retention)
  - ⭑ Minimal or no menstrual disturbances (normal corpus)
- **Signs:** barreled cx, long cx canal (known by sound) + normal corpus
- **D.D**: causes of barrel shaped cx
- **Investigations:** as fibroid but in HSG uterine cavity is normal
- **Dangers:** lateral displacement of uterine artery & ureters
- **TTT:** Hysterectomy, however if pt is young devascularization may be done preoperative by GNRH for 3 months.

II-Submucous fibroid:

- Usually symptomatic causing bleeding, pain, polyps & inversion
- **Diagnosis:**
  - ⭑ **Closed cx**: sound, HSG & hysteroscopy
  - ⭑ **Opened cx**: felt PV & seen (Speculum) & its origin known by sound
- **TTT**: abdominal or vaginal myomectomy (polypectomy +D&C) or hysteroscopy

III-Broad ligamentary fibroid

- **1ry** arises from muscle fibers in broad lig = very rare or
- **2ry** arises from lateral border of cx or body = more common
- **Dangers:** are due to lateral displacement of ureters
- **TTT**. Usually hysterectomy, rarely myomectomy

IV-Intravenous leiomyomatosis:

- Fibroids are found in pelvic veins due to direct spread or arise from smooth muscles of vessels → metastasis (lung)

V-Leiomyoma peritonealis disseminate: fibroids are found on peritoneum & omentum (benign lesions)

ENDOMETRIAL HYPERPLASIA

- **Definition:** Proliferation of the endometrium (glands, blood vessels & stroma) by the effect of **unopposed estrogen** كلمتين مهمين جدا
- **Risk factors:**
  - **Age**: any age but more at 50 y
  - **Smoking:** Decrease as it's an enzyme inducer → ↑ Catabolism of Estrogen
  - **Lynch II syndrome:** Hyperplasia & adenocarcinoma in breast, gall bladder, intestine, ovary, endometrium, hereditary nonpolyposis colorectal CA (HNPCC)
  - **High social class white Race**
  - **Hyper-estrogenism:** PCO, nulliparity, obesity, Early Menarche, late menopause
- **Symptoms**
  - Short periods of amenorrhea followed by prolonged painless vaginal bleeding
  - Postmenopausal bleeding.
- **Signs:** Enlarged uterus
- **Investigation**
  - **Biopsy** → fractional curettage (**diagnostic**), jet irrigation suction aspiration biopsy, suction biopsy, **hysteroscopic guided biopsy**, Pipelle biopsy.
  - **TVUS:** increased thickness > 5 mm in postmenopausal female
- **Pathology:**

⇨ **Simple hyperplasia (previously cystic glandular hyperplasia)**
- **Hypertrophy of endometrium** (Swiss cheese), ↑ glands size
- Normal epithelial /stromal ratio. **Malignant potentiality is 1%**

⇨ **Complex hyperplasia (adenomatous hyperplasia):**
- Multi layering, budding, back to back crowded glands with no stroma in between
- ↑Epithelial / stromal ratio and no secretions. **Malignant potentiality is 3%**

⇨ **Simple or with atypia:**
- As simple + atypia (large dark nucleus, thick irregular nuclear membrane with multiple nucleoli + little cytoplasm). **Malignant potentiality is 8%**

⇨ **Complex with atypia:**
- Malignant potentiality is 30%, 20% coexisting carcinoma & 50% regression rate even if untreated

oral M

N.B.

Arias-Stella Reaction

- pathology :- Focal Atypical endometrial hyperplasia
  1- cellular enlargement, hyperchromatosis, pleomorphism.
  2- The nucleus is exfoliated in the lumen of gland
  3- polyploidy (in adenoca either Diploidy or Aneuploidy)

- Cause :- Excessive Secretory changes (↑ P + E)

- D.D. :- it's associated with
  1- pregnancy :- normal, ectopic, abortion, VM, twins
  2- endometriosis
  3- Artificially by OCPs or gonadotrophin

- **Treatment:**
  - **Young :**
    - **Simple hyperplasia:**
      - Progestins (as mirena or OCPS with P dominant).
      - Induction of ovulation if there is infertility (in need of pregnancy).
    - **Complex or atypical hyperplasia:**
      - D &C (therapeutic) + treatment of the risk factors to be followed up after 3-6 months by U/S
      - If bleeding persists → TAH + BSO
  - **Old patient:** (pre or post menopausal)→TAH + BSO

CANCER ENDOMETRIUM

- **Causes:** malignant tumor of the endometrial lining of the uterus
- **Incidence:** 1st most common 75 / 100.000
- **Risk factors**
  - **Age:** 60 years (postmenopausal; related to E_1)
  - **Smoking:** ↓ risk, as it's an enzyme inducer → ↑ Catabolism of Estrogen
  - **Past history:** + ve
  - **FH:**
    - **Lynch II syndrome**: adeno-carcinoma in breast, gall bladder, intestine, ovary, Endometrium, hereditary non Polyposis colorectal carcinoma.
    - **High social class** (low parity, late marriage, no lactation, white Race (hereditary & familial factors)
  - **Premalignant condition:** Endometrial hyperplasia
  - **Unopposed estrogen** ↑ mitotic activity in the endometrium:
    ↑ endometrial carcinoma, but this don`t occur with normal levels of progesterone
    - ↑ **E** من جوه: Nullipara, PCO, obesity, early Menarche, late menopause ☺ estrogen secreting tumor
    - ↑ **E** من بره: ERT, Tamoxifen if > 5 years.
  - **Cancer corpus syndrome** = CA end + obese + DM + HTN

Factors leading to relative increase of endometrial carcinoma:

1. Increased life span (expectancy) → increased exposure to estrogen
2. ↑ economic status: late marriage, ↓ number of pregnancies + ↓ prolactin (lactation)
3. Increased estrogen therapy → postmenopausal HRT

Pathology

- **Site:** any site but fundus carries the worst prognosis (send to para-aortic LN)
- **Macroscopically:**
  - **Localized form** → mass, ulcer or infiltrating mass
  - **Diffuse form** → the whole uterine cavity is affected
- **Microscopically:**
  - **Adenocarcinom** (60%): Papillary (poor prognosis), secretory, Mucinous (good prognosis) & ciliated
  - **Adenoacanthoma** 20%: adenocarcinoma + benign squamous metaplasia
  - **Adenosquamous carcinoma** 5% adenocarcinoma +squamous carcinoma
  - **Rare types**: Squamous cell carcinoma (rare), carcino-sarcoma
  - **According to Broader's classification**
    - **G1**: (well differentiated) glands + solid cell "0 – 25 %"
    - **G2**: (moderately differentiated) glands + solid cells "25 – 50 %"
    - **G3** : (poorly differentiated) solid cells > 50%
- **Spread: Generally late > 80% are diagnosed in stage 1A G1**
  - **Direct** to uterus, vagina, bladder, ureters, Rectum
  - **Lymph** (late, LN affection is 20% at time of presentation)
    - **Lower** 1/3 as Cancer Cx
    - **Middle** 1/3 to internal iliac LN
    - **Upper** 1/3 para-aortic LN
    - **The cornu:** inguinal LN along the round ligament
    - **Sub-mucosal lymphatic** to vagina
  - **Blood**:-
    - **Through pampiniform plexus** to reach the ovaries
    - **Through paravertebral plexus** to reach the brain (rare)
    - **Through pudendal plexus** → vagina (junction of lower 1/5 & upper 4/5)
    - **Systemic** veins to LLBBKA

Lymphatic Spread of The endometrium

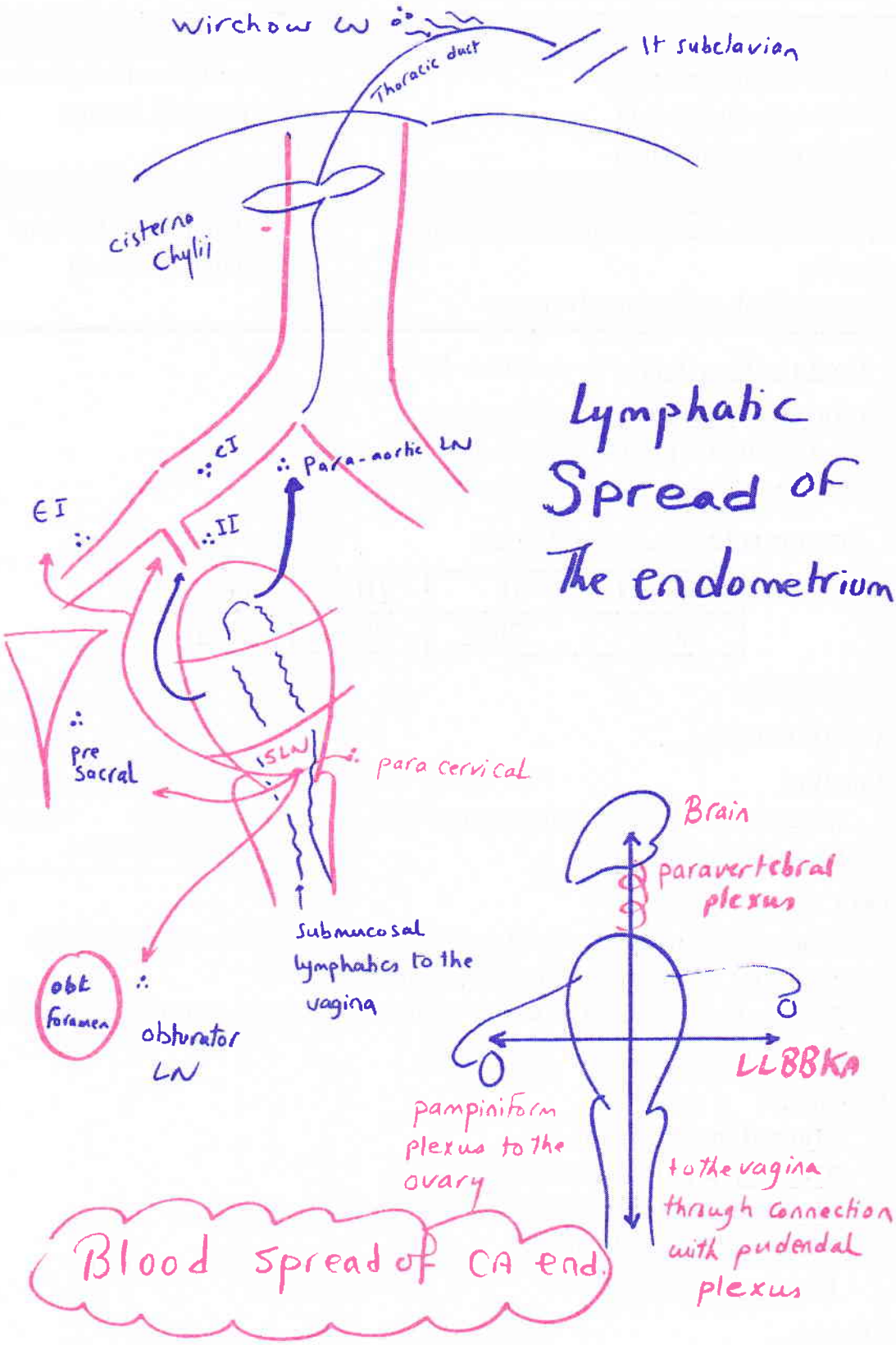

Blood Spread of CA end.

FIGO staging 1988 : to determine line of therapy & prognosis

Stage I (G1,2,3)	Stage II (G1,2,3)
A: limited to endometrium B: < 50% of myometrium C: > 50% of myometrium	A: endocervical glands B: cervical stroma
Stage III (G1,2,3)	**Stage IV (G1,2,3)**
A: serosa, tube & ovary (+ve peritoneal cytology) B: Vagina C: pelvic lymph nodes involvement	A: Bladder & Rectum B: Distant spread

Prognostic criteria: D–A-S-H-L-M

Causes of death (Never cachexia):

- Infections (peritonitis = commonest cause)
- Hemorrhage, Uremia, metastasis.

Prognosis (5year survival rate):

Stage I	II	III	IV
90%	70%	50%	15%

Symptoms

- **Asymptomatic.**
- **Bleeding**
  - Irregular (5%)or Post-menopausal 80%
  - Contact bleeding

Any case of post-menopausal bleeding is considered CA endometrium until proved otherwise)

- **Pain**
  - **Simpson pain:** intermittent colicky pain felt by the end of the day.
  - **Somatic:** infiltration of nerves, bones.
  - **Visceral:** dysuria, dyschasia, constant lower abdominal pain due to pyometra
- **Discharge**
  - **Mucoid** in congestion.
  - **Mucopurulent** in infection.
  - **Muco-sanguinous** infiltration of vessels.
  - **Watery**: Bladder Fistula.
  - **Feculent**, rectal fistula.
- **Masses**
- **Urinary & rectal symptoms**: pain, bleeding & discharge (in fistula)

FIGO : international federation of Gyn & obst.

وده الصح

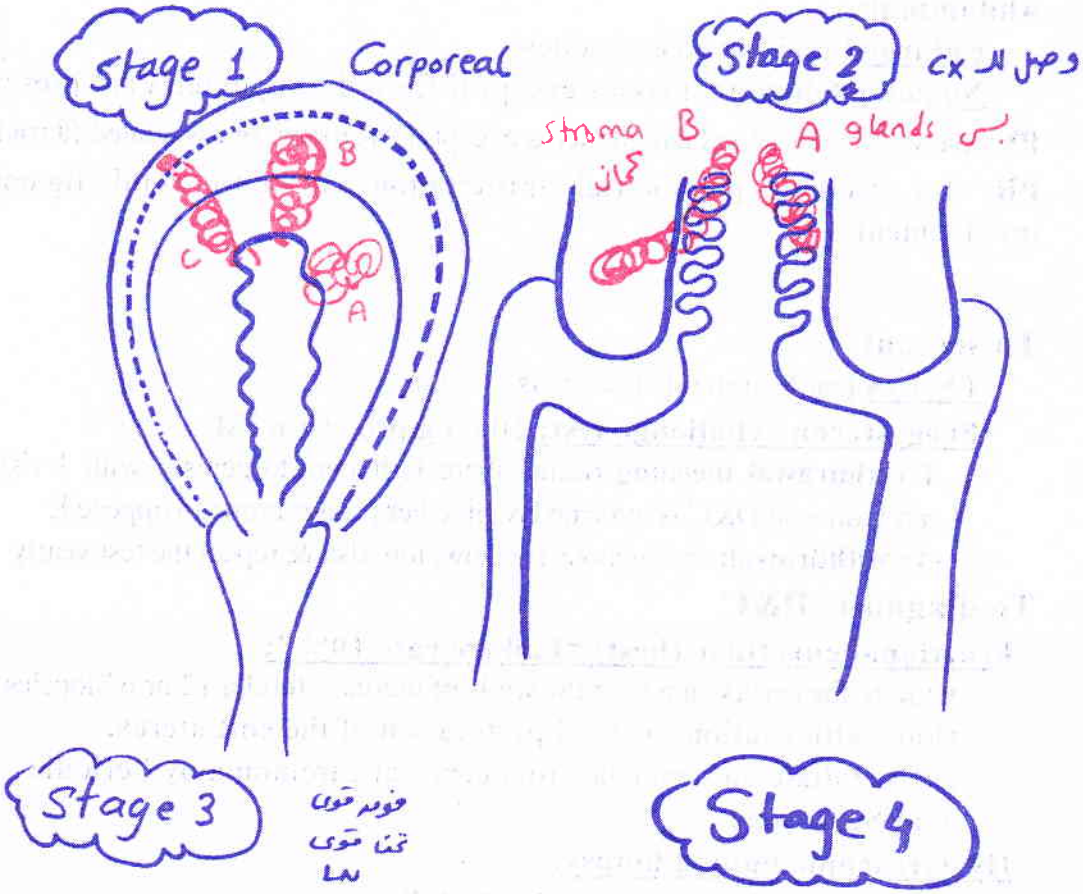

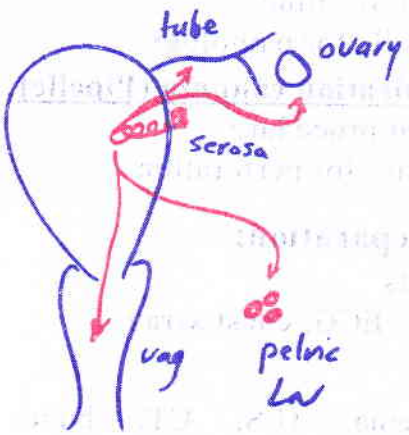

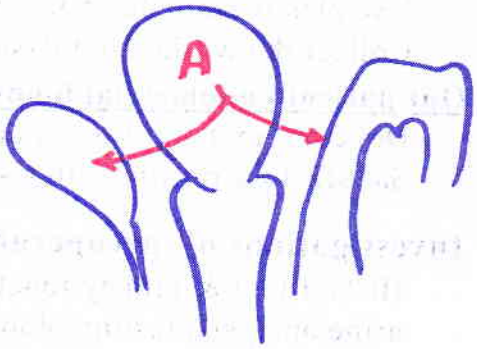

B :- LLBBKA

« Distant »

Signs

- **General:**
  - **Obesity** (cachexia is rare), anemia, DM, HTN
  - **Jaundice**, Pleural effusion, uremia, lymph nodes enlargement (Wirchow)
- **Abdominal:**
  - **Enlarged** nodular liver, ascites
  - **No** pelviabdominal masses except if fibroid or pyometra are present
- **PV**: masses, fistula, blood (small uterus except if pyometra, or associated fibroid)
- **PR**: for rectum, parametrial infilteration & utero-sacral ligament involvement.

Investigation

- **To screen:**
  - **TV U/S** (endometrial thickness > 5mm)
  - **Progesterone challenge test:** 100 mg progestin IM
    - ☆ **if withdrawal bleeding** occurs there is hyperestrogenism with ↑ risk of carcinoma so D&C is indicated & give her progesterone to oppose E
    - ☆ **-ve withdrawal:** endogenous E is low, low risk & repeat the test yearly
- **To diagnose D&C**

1- **Fractional curettage (best) "Failure rate 10%":**
   - ☆ Curette the cervix first then the walls of uterus + fundus (2 or 6 biopsies)
   - ☆ Done with caution to avoid perforation of the soft uterus.
   - ☆ Differentiate endometrial from cervical carcinoma by Periodic acid Schiff test
2- **Hysteroscopic guided biopsy.**
3- **Suction biopsy "Failure rate 10 -20%"**
4- **Jet irrigation suction aspiration "failure rate 10 -20%"**
   - ☆ Use plastic cannula → inject 1-2ml of saline
   - ☆ Collect the washed out tissues & cells for pathology
5- **Out patient endometrial biopsy, Aspiration cannula (Pipelle)**
   - ☆ Done without anesthesia, outpatient procedure
   - ☆ Satisfactory results with less liability for perforation

- **Investigations of preoperative preparation:**
  - Hb%, Liver & kidney function tests
  - urine analysis, fasting blood sugar, ECG, chest x-ray
- **For staging & follow up:**
  - ⇨ **Radiology:** IVP, barium enema, U/S, CT, bone scan, lymphangiography
  - ⇨ **Endoscopy:** cystoscopy, proctoscopy, sigmoidoscopy

N.B. prognostic criteria

- **D**ifferentiation of Tr
- **A** age
- **S**tage of The Tr
- **H**istological Type
- **L**N affection
- **M**etastases

N.B. oral

Fractional Curettage

- Curette the cervix 1st without dilatation بدون جرة
- Then curettage of 5 parts of the uterus (posterior wall الاول ليه
  ثم
  antr wall
  ثم
  الجانبين side walls
  ثم
  fundus)

we have either 2 specimens < cx / corpus or
6 specimens (Cx, post, antr, sides <, Fundus)

- The isthmus (1 cm above the cx can be taken separately (ليه واستحق)
- Avoid perforation of soft uterus
- endo CA is differentiated from endocx CA by periodic acid schiff (stain mucus sec. cells)

D.D

- Symmetrically enlarged uterus
- Perimenopausal & postmenopausal bleeding

Treatment

- **Prophylactic :**
  1. Screening for uterine malignancy → TVUS with early treatment of hyperplasia
  2. Do not use unopposed estrogen
  3. D & C must be done for any postmenopausal bleeding
- **Active treatment:**
  1- **General**: hospitalization, bed rest, analgesics, sedation, correction of anemia
  2- **Specific**:

Stage I: TAH + BSO (the commonest stage)

> **Ovaries must be removed as :**
> - They may contain microscopic metastasis
> - Estrogen produced can stimulate growth of residual lesion

- **Radiotherapy (rare as TAH +BSO is usually enough)**
  - **Postoperative radiation:** only in high risk groups if
    i. **MAC:** tumor infiltrates >1/2 myometrium & LN involvement.
    ii. **MIC:** Grade II or III, papillary or clear (serous) cell carcinoma
  - **Results of radiotherapy** alone are less than surgery
  - Uterine & vag. vault (radium/cesium) + ext. irradiation 5000cGy

Stage II :

- **TAH + BSO + irradiation (preferred)**
- **Wertheim operation** ↑ morbidity & Mortality (DM, HTN & obese)

Stage III:

- **Radiotherapy** (internal & external) ± (TAH + BSO)
- Uterus & vagina are packed with radium or cesium + external irradiation

Stage IV (as recurrent or pulmonary lesions)

- **Palliative hormonal:** 80% are E dependent: Depoprovera 300mg/d for 3m
- **Palliative chemotherapy** platinum or taxol & **palliative radiotherapy**

3- **Palliative**: chemo/radio/surgery, treatment of pain, bleeding & fistulas

- Plan for treatment of end. Carcinoma

- Stage 1

  TAH + BSo ± Irrad.

- stage 2 → الافضل
  → Wertheim op هو ده

- Stage 3 Irradiation ± TAH + BSo

- stage 4 Palliative

- N.B. The biopsy have to be Ex for E+P Receptors
  - if +ve → progestins + anti E
  - if -ve → chemotherapy as platinum, endoxane, Adriamycin.

Uterine sarcoma (rare, 2% of uterine cancers)

Histological types

I- Pure homologous sarcomas: tumor is composed of tissues of uterine origin as

1. Leiomyosarcoma: **Mean age** 45 y, earlier than the other groups.
2. Fibrosarcoma, Endometrial stromal sarcoma (**Mean age** 50y)
3. Angiosarcoma

II- Pure heterologus sarcomas: tumor is composed of tissues foreign to uterus:

→ Chondrosarcoma, Osteosarcoma, Liposarcoma & Rhabdomyosarcoma

III- Mixed sarcomas:

A. Mixed homologous sarcomas
B. Mixed heterologus sarcomas
C. Mixed homologous & heterologus sarcomas

- **Clinical picture:** as endometrial CA, mean age at 55 years
  - Pelviabdominal mass (grows faster, softer, more fleshy than fibroids),
  - Bleeding, pain, pressure manifestation
- **Spread:** mainly by blood, direct, lymphatic & implantation
- **Diagnosis** depends on No of mitotic figures, >10/10HPF → malignancy
- **Prognosis**: poor 2YSR → 50% (0% will reach 5years) especially infiltrative type (better with circumscribed, pedunculated & those arising from a benign fibroids)

V- Sarcoma botryoids (embryonal Rhabdomyosarcoma): mean age is 2 years

- **Is a special type** of uterine sarcoma with rapid growth arise from cervix
- **Symptoms:** Vaginal bleeding or blood stained discharge & abdominal pain
- **Signs:** passage of polypoidal mass from anterior vagina or vulva or urethra

Treatment of uterine sarcoma (high recurrence 75%)

- **TAH+BSO:** (Radical surgery is not indicated as spread is mainly by blood)
- **Post operative:** radio-chemo therapy

Treatment of sarcoma botryoids

- **Chemotherapy** VAC is the main line for 6m
- **After Chemotherapy:**
  - **If resectable tumor:** surgery from TAH to radical surgery ± BSO
  - **If the tumor is unresectable:** HRT is used.

end. CA usually have a better prognosis than CA cx

على سبيل المثال

Due To :-

- Endometrial CA is usually well differentiated
- Slow growth
- Early detection (stage I_a G_1 at 80%)
- Away from infections
- Early symptoms → Early treatment
- Late LN affection.

NON-NEOPLASTIC CERVICAL LESIONS

Uterine polyps

- **Definition:**

  It a pedunculated tumor arising from columnar epithelium

  It hangs from uterus (corpus & cervix) & may comes out of cervix into the vagina

- **Types** هاسؤال مهم جدا:

Cervical	Corporeal
Mucous polyps (commonest cx swelling) • **Cause**: hyperplasia of endocervical mucosa due to chronic cervicitis • **Mac**: simple, soft, small grayish red • **Mic**: - Glands + loose CT stroma - Epithelium is tall columnar + goblet cells (mucus secreting), in multiple hyperplasic layers **Inflammatory polyps:** • **Bilharizial polyp**: granulation tissue, inflammatory reaction around ova +/- bilhariziasis of vagina &vulva → red, granular • **TB polyp**: rare, usually TB forms ulcer, it produces polyp similar to malignant polyp **Fibroid polyp**, **Malignant polyp** • Carcinoma, sarcoma (sarcoma botryoids, carcinosarcoma	**Adenomatous** : • Benign tumor of simple tubular end. glands • **Cause**: part of adenomatous hyperplasia • **Types**: - **Solitary** (localized) = adenoma malignum - **Generalized** (multiple) **Placental polyp**: • **Remnants** of incomplete abortion, parts of chorionic villi surrounded by inflammation → adherent to uterine wall • **symptoms**: occur after recent TOP • **DD** choriocarcinoma **Fibroid polyp** **Malignant polyp** • **Carcinoma**: endometrial carcinoma & choriocarcinoma • **Sarcoma** 1%: sarcomatus change in fibroid polyp, end. stromal sarcoma • **Mixed mesodermal tumor**; carcinosarcoma

- **Symptoms of uterine polyps:**
  - Asymptomatic
  - **Bleeding**: Irregular, meno/metrorrhagia, peri/postmenopausal, contact bleeding
  - **Pain**: colicky lower abdominal pain (uterus trying to expel it)
  - **Discharge**:
    - Leucorrhea due to pelvic congestion
    -
- **Signs**: May be felt or seen by speculum
- **Investigations**:
  - **To differentiate between cervical & corporeal polypi**
    1. Sound & pass it around the polyp :
       → If it passes around → corporeal
       → If not → cervical
    2. Hysteroscopy
    3. HSG
    4. Pelvic U/S (less important)
  - **Biopsy to exclude carcinoma**
- **Complications:**
  - Infection 2ry to trauma & ulceration,
  - Malignancy (rare), squamous metaplasia of epithelium
- **Treatment:**
  - **Smear** & **colposcopy** to exclude malignancy
  - **Polypectomy** +/- cauterization of polyp base +/- D&C, sometimes not easy.
  - D&C may miss the diagnosis as tumor slips away (better do **polypectomy** with polypectomy forceps), but it is important to exclude endometrial hypoplasia
  - Send for **histopathology** to exclude malignancy

Cervical ectropion

- Eversion of cervical lips due to cervical tears
- **C/P:** Asymptomatic, Mucoid discharge & Patulous Os.
- **Treatment:** if symptomatic → Trachelorrhaphy
- **Differential diagnosis:** Cx ulcers by trauma, infection TB, Bilhariziasis, syphilis, lympho-granuloma venerium & malignancy

oral

Q:- Causes of

- abn. vag. bleeding of cx origin
  - Cx erosion (ectopy) آكم وهمية الجديد
  - Cervicitis
- Cervical enlargement
  - Cong cx hypertrophy
  - Cx edema

وهناك اسباب مشتركة

- Endometriosis
- Cx abortion & pregnancy
- Cx Tumors
  - Benign
  - Malignant
  - polyps

oral

Q:- what are the Causes of erythroplakia?

1- ectopy
2- ectropion (eversion)
3- Ulcers:-
   - Malignant
   - Trophic ulcer in prolapse
   - inflammatory (T.B., Syphilis)

CERVICAL INTRAEPITHELIAL NEOPLASIA

Definition

- Replacement of normal cervical cells by cells with malignant criteria but without invasion of basement membranes
- Malignant criteria are:
  - **Architectural atypia**
    - ⇨ Loss of polarity (Pleomorphism)
    - ⇨ Loss of stratification
  - **Cytological atypia**
    - ⇨ Increase nuclear size & ↑ Nuclear / Cytoplasmic ratio
    - ⇨ Increased mitotic figures
    - ⇨ Increase nucleoli, irregular nuclear membrane

Risk Factors

- Age: 40 y.
- Smoking: ↑ (↓ Tr sup. genes, ↑ carcinogens in cervical mucus, ↓ immunity)
- Past history & family history: +ve
- Specific
  - **Multipara**; may be due to cervical trauma at labor
  - **Multiple partners** (due to infections or irritation by smegma)}. especially
    - If occurred at early age <18
    - With multiple partners: transmission of sexually transmitted diseases.
    - Uncircumcised males (smegma may be oncogenic).
  - **Infection**:
    - **HPV 16, 18** while 6, 11 are related to condyloma accuminata
    - **HIV**: decrease immunity, or associated sexually transmitted diseases.
  - **Low** classes & **Black** race (less in Moslems & Jewish: genetic, circumcision)

Pathology

- Site (multifocal ☺):
  - ⇨ Squamo-columnar junction (TZ) → 90%
  - ⇨ Endocervix → 10%
- Mac: nothing but in CIN III there may be superficial ulcers
- Mic: architectural & cytological atypia

Physiology of T. Zone.

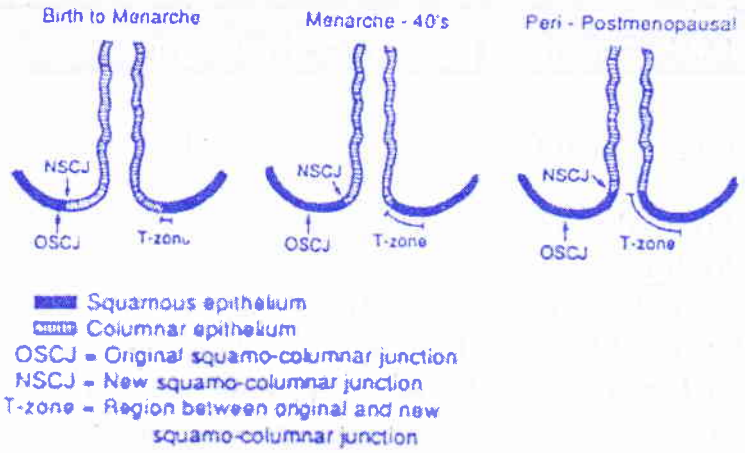

- The vagina & ectocx are covered by str. sq. ep.
- The endocx is covered by col. ep.
- The junction between them is called (OSCJ)
- ↑E → Stimulation of columar epithelium (ectopy) → NSCJ

  ↓E → metaplasia of columar into squamous ep

  ↓

  Life long metaplasia

- المنطقة الحارة T-Zone :- the zone from OSCJ to NSCJ = 1-3cm

  it's the most susceptible to CACX

  بس لازم يوجد HPV

- NSCJ :-
  - before puberty & after menopause: in cx canal
  - at birth & during CBP at Ext os
  - During pregnancy → ectocx

- **Symptoms:** Asymptomatic or contact bleeding at 40 years
- **Signs:** No signs but CIN III → Superficial ulcer
- **Investigations** مهمه جدا

1- PAP smear (papanicolaou smear) سئله فقط

Indications:

- **Routine screening:** starting at 18 year old & once sexual activity starts.
- **For low risk:** every 3 years
- **For high risk:** every 1 year
  1. Multiple partners, HPV- HIV, Smoking
  2. **Subtotal hysterectomy** due to benign lesions
- **After CIN:** every 2 m → 2 years, Every 3m → 3 years then every 1 year
- **Infection**: candida, trichomonas, Gardnerella vaginalis, chlamydia, HSV, HPV
- **Hormonal pattern** & ovulation

Advantages (ideal screening test)	Disadvantages
1- Simple, cheap, noninvasive 2- Accurate (98%) 3- Early diagnosis 4- Office procedure (no anesthesia)	**False +ve**: previous surgery, HPV & immature metaplasia. **False –ve**: infections, high SCJ, poor technique or cytologist اهم سبب

Procedure:

- **Precautions:**
  - **Patient**: not **menstruating** & no **douching** or **intercourse** for 24 hours.
  - **Doctor**: Use vaginal speculum with no lubricants + no PV.
- **Collection** by Ayer's spatula (wood) or Rolon (plastic)
  - **By cervical end:** rotate 360^0 at the external os, Endocervix cells
  - **By vaginal end:** scrap the lateral vaginal wall.
  - **Use brush cytology:** to take cells from the endocervix.
- **Spread** on slide, **fixation** by 95% alcohol & **stained** by PAP stain → Mic ex.

Results: abnormal results is seen in CIN, vagina (VAIN), vulva (VIN)

Management of abnormal PAP smear:

- **Atypical cells** (treat infection for 6 w) & **CIN I** (treat RF for 6 m) then repeat:
  1. **If normal** → repeat after 6 month
  2. **If still atypical** → colposcopy & colposcopic directed biopsy (CDB).
- **CIN II & III** → colposcopy & CDB

Accuracy of PAP test :- Cx (98%), body (50%), FT (20%)
ov (10%)

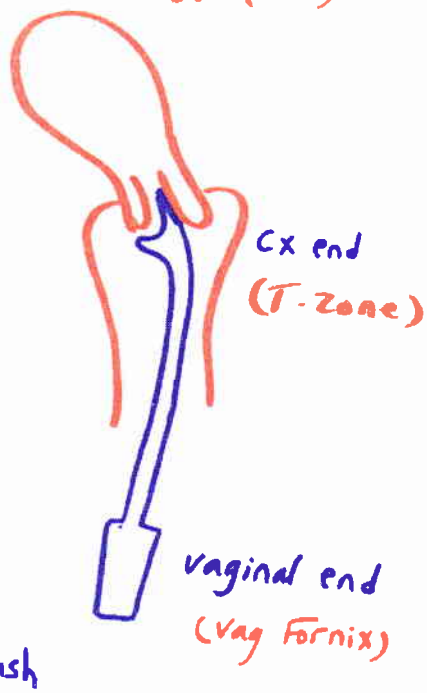

endocx brush	T. Zone	vag Fornix

Brush
(For endocx)

N.B.

- No abnormal smear without colposcopy.
- No suspicious cx without smear oral
- " " " " colposcopy even if the smear is -ve.

* Criteria of malignancy:-
  - raised edge, irregular contor.
  - Abn. blood vessels.
  - Aceto-white areas with acetic acid
  - Yellow areas by Schiller iodine

2-Colposcopy (6-40 x), or colpomicroscopy (270 x)

- Done in case of abnormal PAP smear or suspicious cervix
  1. Shows abnormal epithelium
  2. Abnormal vascular pattern (punctuate, spaghetti, coma shaped or mosaic)
  3. Paint with acetic acid 3%, abnormal areas → acetowhite
  4. Paint with Schiller or Lugol's iodine:
     a. **Normal glycogen** containing epithelium stains brown
     b. **Abnormal areas** (Ectopy or CIN) → yellow unstained (no glycogen).

3-Biopsy (confirmation):

1. Colposcopic directed Biopsy
2. Punch Biopsy, excision biopsy, 4 quadrant biopsy.
3. Cone biopsy: removal of a cone of cx
   a. Diagnostic & therapeutic
   b. +Ve PAP -ve Colposcopy
   c. Unsatisfactory colposcopy: (non visualization of squamocolumnar junction)
   d. +Ve endocervical curettage
4. LLETZ & LEEP (Loop Electrosurgical Excision Procedure)

Classifications of CIN:

Bethesda system	PAP	Dysplasia	CIN
Normal	I	No	
Infection	II	Inflammatory atypia	
Reactive change (pizzar cells)			
Atypical squamous cells	II R	HPV	
Low grade sq. intraepithelial neoplasm (LSIL)	III	Mild	CIN I
High grade sq. intraepithelial neoplasm (HSIL)	IV	Mod Severe Severe dysplasia(CIS)	CIN II CIN HI
Sq cell carcinoma	V	Sq cell carcinoma	

Grade	Malig. Cells in	Progression to CA	CIN may regress or persist unchanged or progress to invasive carcinoma
CIN I	Deep 1/3	0 – 25%	
CIN II	Deep 2/3	25 – 50%	
CIN III	The whole thickness	75 – 100%	

- Colposcope :- Criteria of malignancy

Dyes

green filter

Abn. vasular pattern

punctate

Comma

Spagetti like

mosaic

- Unstained area by iodine
- stained area by acetic acid (aceto white)

Types of biopsies

Ring Biopsy

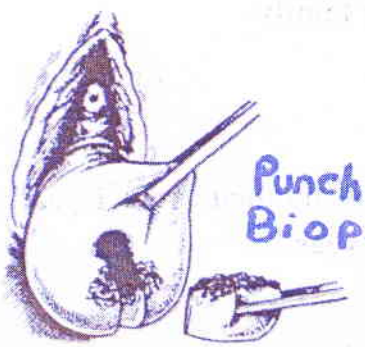

Punch Biopsy



CONE BIOPSY

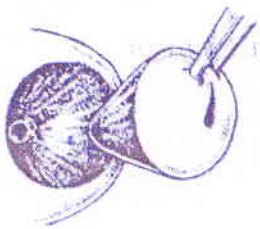

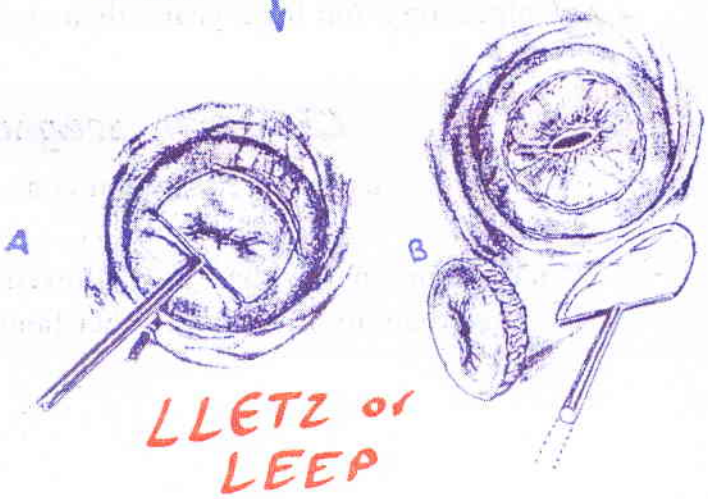

LLETZ or LEEP

Treatment:

- **Prophylaxis** اهم نقطه Treatment of risk factors.
- **Active treatment** ندمرها او نشيلها او نشيل كله :
  - **Local destruction:** cryo, cautery, Laser → 95% cure
  - **Conization: Complications:** Hge, infection, stenosis and patulous os
  - **Micro-Conization:**
    - Large loop excision of transformation zone (LLETZ) or (LEEP)
    - Destroy epithelium to a depth at least 5mm

Indications of conservative surgeries

I - Young patient, not completed her family
II- Expert colposcopist
III- Lesion is exactly demarcated & not extending in cervical canal
IV- Strict follow up by cytology & colposcopy

- **Total hysterectomy**
  - **Lowest recurrence rate < 1%**
  - **Indications:**
    a. Associated pathology as fibroid
    b. If the patient is old or complete her family.
    c. No safety margin with Conization

- **Follow up:**
  - PAP smear/2m for 2years, every 3m → 3 years then every 1 year
  - Colposcopy/ 6m for 2 years, then every 1 year

CIN with pregnancy

- **Investigations:** as non pregnant but cone biopsy is better avoided.
- **Treatment:**
  - Continue pregnancy then VD followed by treatment or
  - CS hysterectomy if completed her family

CANCER CERVIX

- **Incidence:**
  - **It was 35\100,000** but now **15\100,000** due to routine PAP smear
  - **2nd most common** after endometrial carcinoma
  - **Some say**: 3rd most common genital cancer after cancer endometrium & ovary.
- **Risk Factors (as CIN):**
- **Pathology:**
  - **Site**: 90% ectocervix & 10% endo-cervix☺ الارقام مهمه جدا.
  - **Mac**:
    - **Endo-Cx**
      - **Early:** no visible lesion
      - **Late:** barred shaped cervix
    - **Ectocervix:** cauliflower (commonest) or infiltrating (worst) mass, ulcer.
  - **Mic**:
    - **Squamous cell carcinoma (scc)**
      - **Large cell non keratinized scc:** best prognosis
      - **Large cell Keratinized scc:** intermediate prognosis
      - **Small cell keratinized scc:** poor prognosis
    - **Adenosquamous.**
    - **Adenocarcinoma:** risk factors as endometrial CA & not cervical CA سبحان الله

☆ **According to Broader classification:**

Grade 1: undifferentiated cells are <25%
Grade 2: undifferentiated cells are 25-50%
Grade 3: undifferentiated cells are 50-75%
Grade 4: undifferentiated cells are >75%

☆ **It arises from** endocx, producing glandular elements

☆ **It includes** a bulky endophytic growth with a barrel shaped cx

☆ **Some authors believe that** ☺ there is a lower survival rate because:

A. **Barrel shaped large mass** → under irradiation to this area

B. **Higher incidence of local recurrence** compared to SCC, so some do extrafascial hysterectomy with irradiation due to large size

⇨ **Spread:**

- **Direct:**
  - **Upwards & downwards**: body of uterus & vagina
  - **Anterior & posterior**: bladder & rectum (edema, ulcer, hge & fistula)
  - **Laterally**: ureters, parametrium (dangerous & commonest cause of death)
- **Lymph (mainly embolization & rarely permeation).**
  - **1st relay**: paracervical, internal iliac, ext. iliac, presacral & obturator LN
  - **2nd relay**: common iliac (2nd relay)
  - **3rd relay**: para-aortic LN → poor prognosis → palliative treatment.
- **Blood** lung, liver, bone, brain, kidney & adrenal.
- **Implantation** on the vaginal vault.

⇨ **Stages:** To determine line of therapy &prognosis.

✱ **Methods of staging:**

- **PV , PR , recto-vaginal examination**
- **EUA** (antibiotics are given before, for 5 d to treat associated parametritis)
- **X-ray** (IVP , Barium enema), **cystoscopy & proctosigmoidoscopy**

⇨ **I a: microinvasive Carcinoma:** - **Ial:** (minimal microinvasive) tumor is < 3 mm below the basement membrane - **Ia2:** tumor depth <5 mm & width <7mm (no lymphatic or vascular involvement or confluence of tumor masses) ⇨ **Ib:** Ibl the tumor is ≤ 4 cm Ib2 the tumor is > 4cm	⇨ **IIa:** reaching upper 2/3 of vagina ⇨ **IIb:** reaching the parametrium but not reaching the bone
⇨ **IIIa:** Lower 1/3 of vagina ⇨ **IIIb:** affection of pelvic bone, ureter & kidney (hydronephrosis/functionless kidney)	⇨ **IV(a):** affection of bladder & rectum ⇨ **IV(b):** distant spread

⇨ **Prognosis:**

- **I: 90% (LN affection 20%),**
- **II: 50% (LN affection 40%),**
- **III: 25% (LN affection 60%),**
- **IV: 5% (LN affection 80%)**

⇨ **Prognostic criteria:** DASH LM

⇨ **Causes of death:**

- **Uremia:** commonest cause (50%) due to bilateral ureteric affection
- Cachexia, infection, hge or metastasis or complications of treatment.

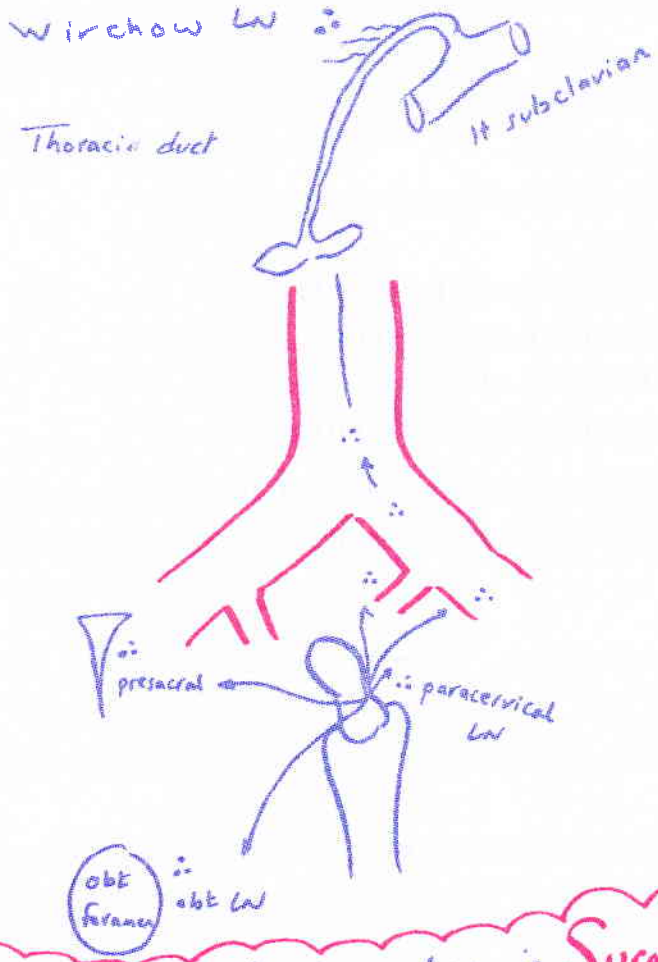

N.B. staging of CA endometrium 4 ov is **Surgical**
" " " CX is **Clinical** but
There is also an old surgical staging with accuracy > clinical staging by 20-40% اعلى

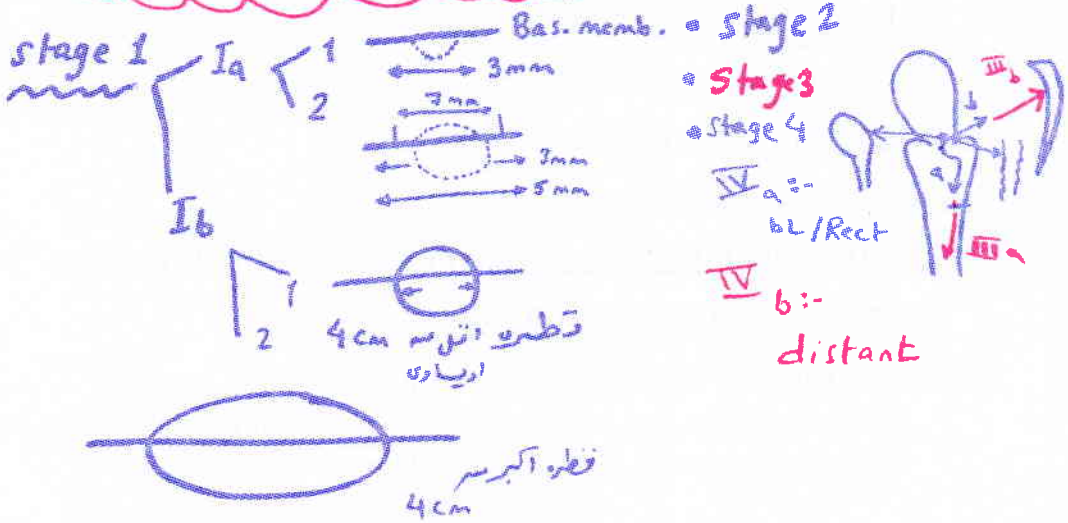

Symptoms:

- **Asymptomatic**: early stages (accidentally discovered)
- **Bleeding**: earliest symptom is contact, peri or post menopausal bleeding (more commonly CA endometrium).
- **Pain:** late. May be
  - **Somatic** (infiltration of nerve or bone)
  - **Visceral:**
    1- **Infiltration of bladder:** Dysuria
    2- **Infiltration of rectum:** Dyschasia
    3- **Infiltration of ureters:** loin pain
    4- **Pyometra & parametritis**
- **Discharge:** mucoid, mucopurulent or Muco-sanguinous
- **Masses, urinary & rectal symptoms:** pain, bleeding & fistula

Signs:

- **General**: Cachexia, anemia, uremia, jaundice, fever & metastases (Wirchow's).
- **Abdominal**: ascites, enlarged nodular liver, lymph nodes & tender loin
- **Vaginal**: masses, carter shaped ulcers, fistulae & barrel shaped cervix
- **P/R:** infiltration of the rectum, parametrium & uterosacral ligaments

Investigation:

- **To screen:** PAP smear & colposcopy اكتبهم بالتفصيل الممل
- **To diagnose: (biopsy الاهم)**
  - **Colposcopic** guided biopsy - 4 quadrant biopsy - ring biopsy
  - **Excision** biopsy - punch biopsy - cone biopsy (conization)
  - **Micro** conization (LLETZ, LEEP)
- **To know spread®☺** الاهميه القصوي
  - **IVP (for complications & staging)**, CT, MRI & Bone scan
  - **Examination under anesthesia**
  - **Cystoscopy** to see the bladder, Biopsy & P/R
    - Bullous edema due to lymphatic obstruction (is not IVa مهمه جدا)
    - Malignant masses, fistula (stage IVa)

محاضرة

Screening of CA CX (للدائل فقط) :-

- In vivo staining with acridine :- staining of DNA, RNA
- Enzyme test :- ↑ LDH or G_6PD in cervical tissue.
- Tumor marker :- CEA or Squamous cell Carcinoma antige.
- Cervicogram :- The cervix is visualized, 5 % acetic acid & 2 pics are taken by a special camera to colposcopy.
- DNA study :- Aneuploidy 45, 47, ... not polyploidy.

Differential diagnosis

- **Causes of contact bleeding (bleeding following PV, coitus, or douching)**
  - A. **Carcinoma of** vagina, cervix, body.
  - B. **Cx** Ectopy, erosion & ulcers
  - C. **Cx. polypi** (especially mucous polyps & fibroid polyps)

- **Ulcers of the cervix:**
  - A. **Chancre** rounded ulcer with punched out sharp edges +ve test for syphilis
  - B. **Bilhariziasis** multiple, dirty irregular shallow floor, +ve bilharizial tests.
  - C. **TB** single or multiple, undermined edge, yellow floor
  - D. **Herpes:** multiple, small, grayish, painful
  - E. **Cervical Ectopy**
  - F. **Trophic ulcer** in prolapse: cancer cervix is rare with prolapse.

- **Causes of cervical masses ;**
  - A. **Polyp of the cervix** بالتفصيل
  - B. **Retained products of conception**.
  - C. **Cysts** = dermoid, mesonephroid & endometriosis
  - D. **Benign tumor** = squamous cell papilloma which is potentially malignant.
  - E. **Ch.uterine inversion**

- **Barrel shaped cervix:**
  - A. Cx fibroid, Endocervical carcinoma
  - B. Cervical abortion, ectopic (cx. Pregnancy)
  - C. Chronic hypertrophic cervicitis
  - D. Retained products of conception

Plan of management اهم حاجه في الموضوع

- **CIN:** TAH or conization
- **Ia1:** TAH or conization (in Ia + the patient has no children + strict follow up).
- **Ia2:** extended hysterectomy
- **Ib IIa:** radical hysterectomy or irradiation or both
- **IIb IIIa IIIb:** irradiation
- **IVa:** inoperable but if there is no lateral spread → exentration
  - **If bladder is infiltrated:** Anterior exentration (Radical hysterectomy + bladder removal + urinary diversion).
  - **If rectum is infiltrated:** posterior exentration (Radical hysterectomy + rectum removal + colostomy + Hartman's pouch)
  - **If both:** total pelvic exentration + wet colostomy
- **IVb:** palliative

Treatment Best results by combined treatment (surgery + radiotherapy)

Prophylactic treatment:

- Routine screening of all females
- Avoid the risk factors & treatment of premalignant conditions,
- Strict follow up by colposcopy & smear for all treated cases.
- Recently, FDA approved quadrivalent HPV vaccine as a prophylaxis for all ♀.

Active treatment:

- **General:** hospitalization, bed rest, treatment of anemia & infection

- **Surgery & irradiation:** look the table
- **Chemotherapy:** OH urea (cell cycle specific) or Platinum (non specific)
- **Combined surgery & irradiation :**
  - **Preoperative:** shrinks tumor size to become operable
  - **Postoperative:** if +ve lymph nodes
- **Combined chemotherapy & radiation acting through:**
  - **Synchronization** of cells into a radiosensitive phase of cell cycle
  - **Inhibition** of repair of sublethal injury due to radiotherapy (radiosensitizer)

- **Palliative treatment:**
  - **Palliative surgery:**
    - **Exentration** + urinary diversion or colostomy
    - **Surgery for pain:** intrathecal anesthetic injection
    - **Intractable fistula:** uretero-colic anastomosis
  - **Palliative irradiation:** to ↓ tumor bulk or its metastasis, through:
    1. **Suppression of mitosis**
    2. **Chromosomal damage**
    3. **Endarteritis obliterans**
  - **Palliative medical treatment:**
    - **Analgesics** up to morphine
    - **TTT** of hemorrhage, anemia, ulcer, infection

	Surgery	Irradiation
Indication	1. CIN 2. Ia, b, II a, IV a	1. I b, II a, b, III a, b, IV b, palliative. 2. Preoperative & postoperative
Contra indication	• Advanced stage • Unfit or refusing surgery	• Young age, Infection, Adhesions • Fibroid, ovarian cyst • Adenocarcinoma

Surgery	Irradiation
Advantages	
• Remove the tumor bulk • Suitable for young patients: - No vaginal stenosis - Ovaries can be preserved • Avoid the disadvantages of irradiations	• Low 1ry morbidity <1% & mortality • Avoid disadvantage of surgery
Disadvantages	
Mortality rate is >1% 1. **Anesthesia, Infection, injury:** ureteric (fistula 2%), bladder, rectal, intestinal, lymphocyst (due to lymphadenectomy) 2. **Hge:** ▪ **1ry:** intraoperative hemorrhage ▪ **2ry** due to infection ▪ **Reactionary** due to slipped ligature • **Wound:** infection, burst abdomen hernia	1. Premature menopause 2. Stricture & adhesion (intestine, ureters & vagina) 3. Irradiation cystitis: dysuria, hematuria fistula 4. Irradiation proctitis: dyschasia & fistula 5. Irradiation sickness: nausea vomiting & haematemisis
Types	
1) Total hysterectomy 2) Extended hysterectomy (uterus, cervix & vaginal cuff) 3) Radical hysterectomy (RH): as above + pelvic ligaments, parametrium, pelvic LN. Either abdominal (Wertheim) or vaginally (Schauta). **NB:** 1. RH + excision of bladder = anterior exentration 2. RH+ excision of the rectum= posterior exentration 1+2 = total exentration	1) **Tele-therapy & brachy therapy** {alone is not enough as radiation effect ↓with distance so teletherapy usually precedes or follows brachytherapy} 2) **Preload or after load (better)** 3) **Cesium (better) or cobalt** 4) **Technique** ▪ Paris: small dose for long period ▪ Manchester: Medium ▪ Stockholm: ↑ dose for short period 5) **Calculation of the dose** (by dosimeter) 8000 rad at point A (2cm lateral & above lateral fornix) & 5000 rad at point B (5cm lateral & 2cm above lateral fornix) 6) **Method of irradiation:** 1- GA, lithotomy, uterine sounding. 2- Dilatation of Cx & insertion of cesium (pellets, tandems) + colpostat or vag. pack to avoid spread of cesium

oral Complications of hysterectomy acc. to timing:-

- **Intra-operative:-**

  Anesthesia, hemorrhage, injuries.
  بالنزف

- **post-operative:-**

  - 1st day :- reactionary Fever & hemorrhage
  - 2nd day :- intestinal distension
  - 3rd day :- urine retention
  - 5th day :- DVT, 2ry hemorrhage
  - 7th day :- Lung Collapse
  - Later :-
    - wound compl
      - abd: infection, dehiscence, burst abd
      - vag: infection, hematoma, granuloma
    - organ removal
      - uterus: psych.
      - ov: menopausal symp
      - ur: lymphocyst
    - 2 Miscellaneous
      - adhesive I.O.
      - Fistulas

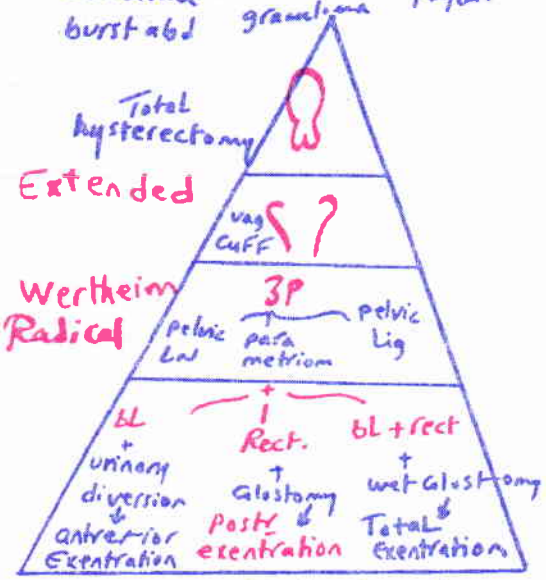

Types of hysterectomy

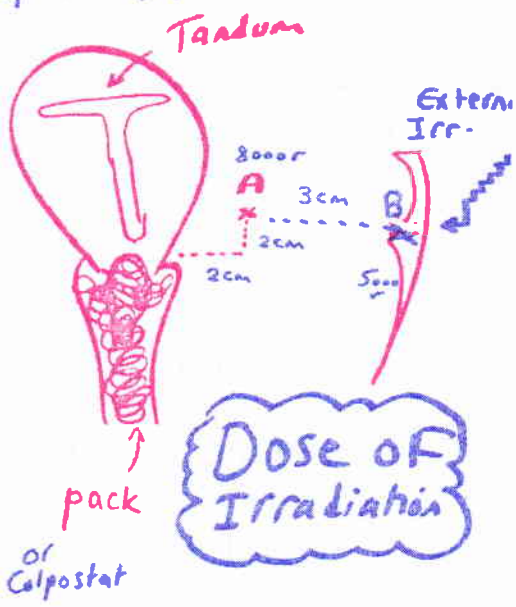

Some other conditions (HRPS)

- **Histopathological surprise**
  - Cancer cervix in histopathology
  - **Treatment**: irradiation
- **Recurrent cancer cx. (In 35%)**
  - **Site:** local 1/4, regional 1/4, remote 1/2
  - **Manifestations of recurrence of malignancy:**
    - Cytology +ve after therapy
    - Ulcer in cervix or vagina
    - Ascites, tumor mass in abdomen or pelvis
    - Edema, Pain, bleeding, bloody discharge
    - Supraclavicular or periaortic lymph nodes
  - **Treatment:** irradiation if recurrence after surgery Or Surgery if recurrence after irradiation.
- **Barrel shaped cx**:Treatment: extra fascial hysterectomy
- **Cancer cervix during pregnancy 1/3000**
  - **C/P:** Bleeding with pregnancy
  - **Investigations during pregnancy:** PAP smear, colposcopy, conization is better avoided

	1st trim.	2nd trim.	3rd trim.
Surgery	Radical hysterectomy en toto	Radical hysterectomy en toto	CS Wertheim
Irrad	Irradiation before or after evacuation	Hysterotomy Then irradiation after 2 w	C.S Then irradiation after 2 w

- **Stump carcinoma 1%**
  - **Types:**
    - **True** (after 2 years after hysterectomy)
    - **Coincidental** (before 2 years)
  - **Poor prognosis:**
    - **Difficult irradiation** (difficult external due to adhesions, no internal)
    - **Difficult surgery** (due to adhesions)
    - **Early spread**
  - **Treatment:**
    - **Prophylactic** (total hysterectomy, PAP smear)
    - **Active** (Surgery - Chemotherapy - Radiotherapy)

• Recurrence of CA Cx :-

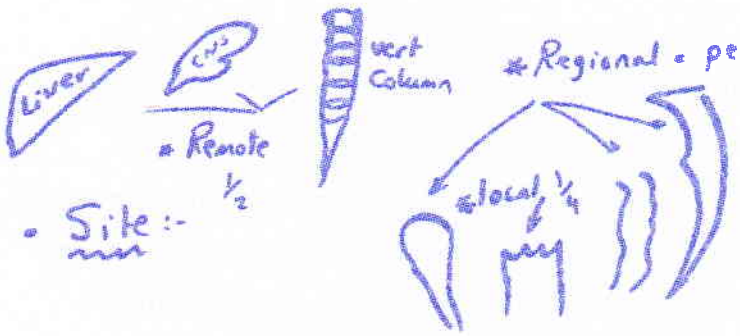

Central recurrence
اصح من
Prognosis
Than
Lateral recurrence

• Site :-

• incidence : 1/3 of cases.

• Stump Carcinoma :-

hysterectomy

coincidental — 2 years — True.

عيب دكتور

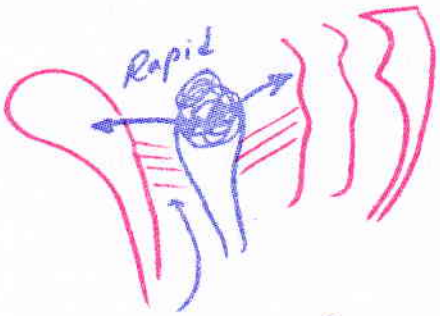

poor prognosis

difficult Surgery & irradiation

BENIGN OVARIAN NEOPLASM

Functional Ovarian Cysts

General characters

- Usually < 6cm.
- They are usually due to ↑ gonadotrophins
- Resolve spontaneously or with OCPS.

1- Follicular Cyst

- **Due to** continued growth of the follicles by exogenous gonadotrophins
- **Multiple and bilateral**: usually 2 - 3 cm but may reach up to 10 cm.
- **C/P**: Asymptomatic unless rupture or hemorrhage occurs inside it
- **Treatment**: ↓ spontaneously but oral contraceptive pills can also be used.

2-Theca Lutein Cyst

- **Causes**: V.M, choriocarcinoma, DM, Twins, induction of ovulation, OHS $.
- **C/P:** Asymptomatic unless complicated, may reach 15 cm
- **Treatment**: treatment of the cause, resolves spontaneously in about 4 months

3-Corpus Luteum Cyst

- **Usually during pregnancy**, single, unilateral & reaches up to 8 cm
- **C/P:** Asymptomatic complicated & disappears after 10th wk of pregnancy.

4- Luteoma:

- **There is hypersensitivity to ß hCG** → excess luteinization of theca cells
- **Occurs** in perimenopausal ♀ or during pregnancy, usually large & unilateral
- **Regress** spontaneously after pregnancy.
- **May be** associated with ↑ androgen secretion → maternal virilization & very rare female fetus virilization (as the placenta transforms androgens to estrogens).

5- Endometrial Cyst See endometriosis

6- Polycystic ovary: Look PCO

Difference between functioning non neoplastic and neoplastic cysts

The non neoplastic have the following:

1. Small in size, less <5-6cm if more, it must be removed
2. they are related to events of ovarian cycle
3. Following up: no ↑ in size & ↓ spontaneously (OCP for 3 m can be used)

• Types OF ovarian tumors:

- Functional
  طلع نتيجه لتبلك
  هرمونات
- Functioning
  بيطلع هرمونات
- True
  (new growth
  from The ovary)
  ovary مختلف من

FSH → Follicles

LH, HCG (if pregnant) → CL

Follicles	CL
• Follicular Cyst	• CL Cyst
• P C O	• Theca Lutein Cyst
	• Luteoma

+

Endometrial Cyst

True Benign ovarian neoplasm

	SIMPLE SEROUS CYSTADENOMA	PAPILLARY SEROUS CYSTADENOMA	MUCINOUS (PSEUDOMUCINOUS) CYSTADENOMA
Incidence	• 10%	• 5-10%	• 10 - 20%
	• Commonest ovarian tumors		
Size	• Small	• Moderate	• Huge
Laterality	• Unilateral	• Bilateral 30-50%	• Unilateral in 90%
Surface	• Smooth	• Thick wall covered with external papillae (exophytic)	• White glistening surface
Cut surface	• Cystic with few loculi (but often only one) • The secretions are watery and colorless	• Made of 2 or 3 loculi with intracystic papillae (endophytic) • The fluid is either clear or bloody.	• Made of multiple loculi • The fluid is glycoprotein like mucin (pseudomucin due to high content of neutral polysaccharides may be due to aging of the cyst)
Mic	• Ciliated columnar epithelium	• Ciliated columnar epithelium • With goblet cells • And spherical bodies in the stroma (psammoma bodies).	• Tall columnar epithelium with goblet cells. • Pseudomyxoma Peritonii may occur(see after)
Malig. potentiality	• Rare	• 30-50% become Papillary cystadeno-carcinoma	• 0.5% turns mucinous cystadenocarcinoma

Q:- What is The origin of ovarian Tumors ?

* epithelial Tumors (ectoderm):-
  - From celomic epithelium (surface epithelium of the ovary):
  - has the same embryonic origin of Mullerian duct so produce Trs similar to
    - tube (serous), cx (mucinous)
    - uterus (endometroid)
    - Bladder (Brenner)
    - Kidney (mesonephroid)

* Germ cell Tumors (endoderm)
  - Arise from ova (Theory of Auto Fertilization)
  - produces various embryonic products

* Sex Cord - Stromal Trs (mesoderm)
  - sex cords → granulos or sertoli
  - sex stroma → Theca or leydig & fibroblasts.

	BRENNER'S	FIBROMA	DERMOID CYST
Incidence	• Very rare • Age > 40y	• 5%	• 20%☺ ده الـصح • 40% كتاب القسم
Size	• Small	• Moderate	• Moderate
Laterality	• Unilateral	• Unilateral in 90%	• Usually unilateral
Surface	• Smooth	• Smooth lobulated with long pedicle	Smooth thick surface
Cut surface	• Usually found in the wall of mucinous cystadenoma	• Solid with whorly appearance.	• Cystic, 1 loculus containing thick yellowish sebaceous fluid, skin, CNS (ectoderm), tooth, muscles(mesoderm), thyroid, carcinod tissue (Endodermal)
Mic	• Columns of squamous or transitional epithelium with **COFFEE BEAN** appearance of the cells with occasionally calcium deposits	• Bundles of spindle cells with dense fibrous tissue	• Has a nodal point containing **ROKITANASKI TUBERCLE** (3 germ layers with ectoderm predominance)
Malig. potential	• Hardly turns malignant	• 0.5% turn malignant	• 1.5% become: ▪ SCC. ▪ Rarely melanoma or sarcoma
Others	• Secrets E→ precocious puberty, menstrual irregularities, post menopausal bleeding, endometrial hyperplasia & carcinoma	• May undergo Cystic or Hyaline or Fatty Degeneration . • Associated With Meig's Syndrome (see after)	• Commonest Ovarian neoplasm in young adult (20-30 yrs) and during Pregnancy. • The commonest tumor in front of uterus (in uterovesical pouch)

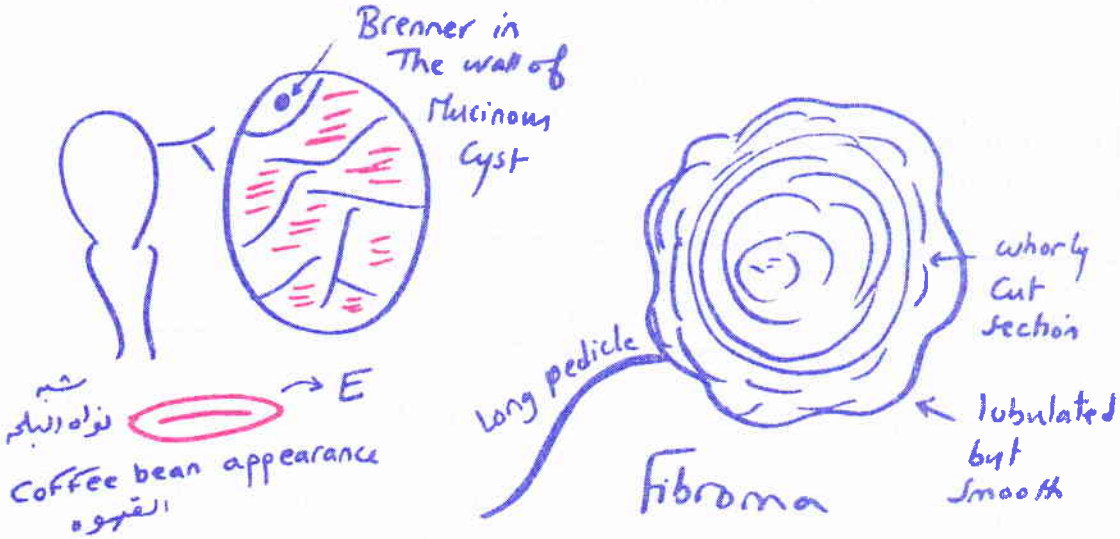

oral
هام - Types of Teratoma
جدا

- Mature (Benign)
  - Cystic (Dermoid cyst)
  - Solid
- immature (mal.)
  - highly specialized
  - x Struma ovarii
  - x Carcinoid

oral N.B. para - ovarian Cysts :-

- **Origin:-** mesonephric duct remnants
  - * Main duct → Gartner duct
  - * accessory tubules → Hydatid cyst of Morgagni & Koblet's tubules epo-oophoron & par oophoron.
- **Location:-**
  - * in the Broad lig
- **Size :-**
  - * usually small but may be large if FT becomes stretched over it
- **CIP :-** as any ovarian cyst

Meig's syndrome: **[ovarian fibroma + Rt hydrothorax + ascites)**

- It is formed due to mechanical irritation of peritoneum by heavy mobile tumor.
- Loss of Fluids from veins & lymphatics of the tumor.
- **Pseudomeig's syndrome** = ascites + RT hydrothorax+ other ovarian tumor rather than ovarian fibroma (Brenner, thecoma, multiple pedunculated subserous fibroids, ovarian hyperstimulation syndrome).

Struma ovarii: Benign teratoma which is made of thyroid tissue which may be functioning and causes hyperthyroidism

Pseudomyxoma peritonii:

- Due to rupture of the mucinous cyst or rupture of mucocele of GB or appendix.
- Epithelial cells of the cyst spread over the peritoneum → secret semisolid pseudomucinous fluid leading to abdominal distension, pain & vomiting.
- **Treatment**:
  - Surgical removal of the tumor and evacuation of the abdominal cavity + Chemotherapy + Intraperitoneal Radiotherapy:
    - Colloid phosphorus.
    - Colloid gold.
- Mortality is high (50%) due to intestinal obstruction and cachexia.

Symptoms:

- **Age:** 30-55 years old, but no age is immune
- **Often asymptomatic**
- **Abdominal swelling**
- **Pressure symptoms**, **Pain** if complicated
- **Menstrual symptoms or virilization:** if the tumor is hormone secreting.

Examination:

- **General examination**: No abnormality is detected
- **Abdominal examination**:
  - **Pelvi-abdominal swelling.**
  - **Palpation:** Mobile, with smooth surface & well defined edges
  - **Percussion:** the swelling is dull
- **P/V (or bimanual)** بالاحساس والحركه بعيد عن الرحم:
  - **The uterus** is felt separate from the swelling,
  - **The movement** of the cervix is not transmitted to the tumor

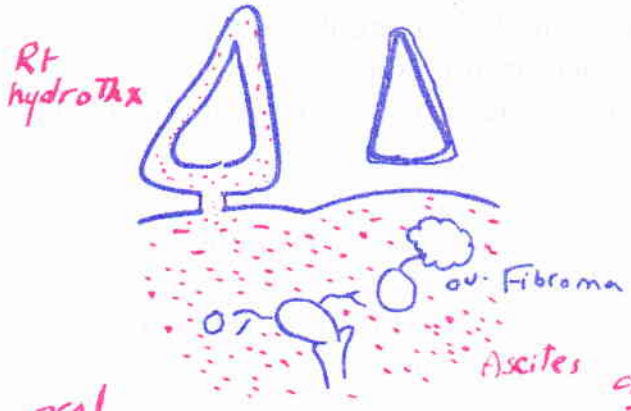

Meig's synd.
امريكى مات
فى الطائرة بسكتة
قلبية

oral

N.B. Carcinoid Tr {argentaFFin cells producing Serotonin (5HT)} is more symptomatic here than GIT Carcinoid as it bypasses The enterohepatic circulation
→ Flushing, headache, bronchospasm, & Diarrhea.

	Benign	Borderline	Malig.
MAC	Small	Large	Larger
	unilateral	May be bil	Bilateral
	less papillae	↑	↑↑
MIC	Single ep layer	↑	↑↑
	No mitosis	Few	Marked
	No invasion		present
	No metast.	rare	present

Differential diagnosis:

- Fetus, Fibroid, Fat (obesity), Fluid (ascites), Pseudocyesis.
- Feces & flatus due to intestinal obstruction.
- Full bladder: insert urinary catheter to ensure that the bladder is empty.

Investigations:

- **U/S:** Differentiate solid swellings from cystic swellings.
- **Laparoscope** is of great value to identify the nature of the small cyst.
- **X-Ray** to detect the presence of teeth in the cyst (dermoid cyst).
- **Laparotomy** to reach the final diagnosis.

Treatment of the benign ovarian neoplasm:

- **Mainly** surgical even if small asymptomatic tumor to avoid:
  - The possibility of malignant transformation
  - The occurrence of complications
- **Ovarian Cystectomy:** in benign tumors in young women
- **Ovariectomy:** Excision of the whole ovary including the cyst
  - **3 clamps** on the ovarian, infundibulopelvic ligaments & mesovarium
  - **3 things**: ex. other ovary, don't rupture the cyst & send it to histopathology
- **Pan-hysterectomy** is done for uni/bi-lateral benign ovarian tumors in ♀ > 45 y

Complications of ovarian neoplasm:

1-Torsion (Axial rotation, the commonest complication)

- **Definition:** axial rotation, maintained by lashing of blood vessel pulsations.
- **Predisposing factors:**
  - Moderate size, mobile tumors & long pedicle,
  - Pregnancy (esp. 2nd trimester due to upward displacement of the tumor)
  - Puerperium (the commonest time)
- **Precipitating factors:** sudden movement, fetal kicks, PV, external trauma
- **Types**:
  - **Acute torsion**: congestion, hemorrhage, rupture and necrosis of the tumor.
  - **Chronic torsion**: gradual ↓ blood supply → ischemia & release of angiogenic substance & adhere to a nearby organ (parasitic tumor)
- **Symptoms:** Acute abdominal pain + shock + vomiting.
- **Signs:** The tumor is felt very tense & tender.
- **Investigations:** US → adenxal swelling
- **Treatment:** Immediate laparotomy & excision. No untwisting to avoid release of toxic material & thromboplastin in general circulation → DIC.

N.B. ovariectomy X oophorectomy

removal of a macroscopically diseased ovary

removal of a macroscopically healthy ovary

Treatment

تجميعة

لازم تتعالج

Cyst

or

ovary

or

نشيل كل

TAH + BSO

ونشيل

Complication

تجميعة

تلف - تنزف - تقرقح

2I

Malignancy

2- Hemorrhage (internal or external in the peritoneum)

- **Etiology (3T):** torsion, tumors & trauma (kick - delivery)
- **Symptoms:** acute abdominal pain, fainting.
- **Signs:** the tumor becomes enlarged, tense and tender ± hemorrhagic shock
- **Treatment:**
  - Blood transfusion, fluids, O_2, Morphia
  - Immediate laparotomy with excision of the affected ovary

3- Rupture

- **Etiology (3T):** torsion, tumors & trauma (kick - delivery)
- **Pathological effects depends on the nature of the content:**
  - **Ruptured serous cyst** causes minimal irritation
  - **Ruptured mucinous cyst** causes pseudomyxoma peritonii
  - **Ruptured papillary cyst** causes implants with persistent ascites
  - **Ruptured dermoid cyst** causes aseptic peritonitis
  - **Ruptured infected cyst** causes septic peritonitis
  - **Ruptured malignant cyst** causes dissemination
- **Symptoms:** acute abdomen
- **Signs:**
  - Disappear or change in shape
  - Appearance of the fluid in the peritoneal cavity giving +ve shifting dullness
- **Treatment:**
  - Anti-shock measures + Immediate laparotomy
  - Ovariectomy & Peritoneal toilet

4- Infections

- **Causative organisms:** **E - Coli** or other pyogenic organisms
- **Route of infection:** nearby intestine, ascending from vagina or blood - borne
- **Symptoms:** acute abdomen + fever
- **Signs:** rapid pulse + high temperature with tender and rigid abdomen
- **Treatment:**
  - **Antibiotic** till the fever subsides
  - **Laparotomy** and Ovariectomy are done
  - **If the cyst is adherent to nearby organ**, do marsupilization (deroofing)

5- Incarceration: pressure symptoms > 4D *(dyschasia/dysuria/dyspareunia/deep pain)*

6- Complications due to malignant ovarian neoplasm as spread & cachexia

7- Pressure effects: Diaphragm → dyspnea.

N.B. Causes of Chocolate Cysts?

- Endometriosis
- Endometroid Tr.
- hemorrhage into any cyst

OVARIAN CYST DURING PREGNANCY

- **Effect of the tumor on pregnancy**
  - **During pregnancy**
    - **Early:** abortion, ectopic & incarceration
    - **Late:** malpresentations, nonengagement & pressure manifestations
  - **During labor**
    - **1st stage:** prolonged labor, large bag of forewater, PROM & cord prolapse
    - **2nd stage:** obstruction
    - **3rd stage:** retained placenta & post-partum hemorrhage.
  - **Puerperium:** sepsis

- **Effect of the pregnancy on the tumor:** ↑ **All complications**

- **Management:**
  - **During pregnancy**
    - **1st trimester:** wait as it may be (C.L cyst) if removed it will lead to abortion
    - **2nd trimester:** remove
    - **3rd trimester:** wait till labor
  - **During labor :**
    - **If no obstruction:** vaginal delivery followed by removal of the cyst
    - **If obstruction:** C.S + removal of the cyst
  - **During puerperium:** remove
  - **At any time suspect malignancy interfere**

1st Tri	2nd Tri	3rd Tri	puerperium
Wait	Remove	Wait	Remove

Labor

- obstructing → laparotomy → CS / Excision of the cyst
- not obstructing → VD Then laparotomy بعد كده

WHO Classification of ovarian Trs

حسب الحفظ

I- Epithelial Trs (80%)

1. Serous Tr
2. Mucinous Tr
3. Endometroid Tr

x each may be benign, Borderline or malig.

x each may be
- cystadenoma
- fibro adenoma
- cystadenofibroma

x Serous بالانواع زيادة
- papillary cystadenoma
- surface papilloma

4. Mesonephroid Tr (usually malig.)
5. Brenner Tr (usually benign)

II- Sex cord - stromal Tr 10%

9x Granulosa - stromal Tr
1. Gr. cell Tr
2. Gr Theca Tr
3. pure Thecoma Tr
4. Thecoma Fibroma Tr

bx Sertoli - leydig Tr (Androblastomas)
1. well differentiated
   - sertoli ± lipid storage
   - leydig
   - sertoli - leydig
2. intermediate diff.
3. poorly "
4. with heterologous elements (SCTAT): Sex Cord Trs with Annular Tubules

Cx Gynandroblastomas

III Germ cell Trs (10%)

a) undifferentiated → Dysgerminoma

b) poorly differentiated → embryoma, polyembryoma, embryonal CA.

c) Differentiated:
- embryonic → Teratoma
- Extra-embryonic
  - x Chorio CA
  - x Yolk sac Tr
- Mixed

IV Gonadoblastoma

germ cell Tr + sex cord / stromal Tr

V Soft tissue Tr

not specific to ovar
angiosarcoma

VI unclassified Tr

VII 2ry (Metastatic)

- Similar to parent Tr

or

- Krukenberg Tr

Cancer ovary

Incidence:

- 23% of the female cancers of the genital system
- 47% of mortalities of cancer of the female genital system

Distribution by age	Incidence/ 100.000	Nature
20% → < 40 years	- 40 y → 15	- 80% benign - 20% malignant (20% are 2ries)
60% → 40 – 60 years	- 60 y → 35	
20% → > 60 years	- 80 y → 55	

RF:

1- **Age:** any age
   - **In old:** epithelial tumors are more common
   - **In young:** germ cell tumors are more common
   - **In reproductive stage:** functional non neoplastic tumor
2- **Smoking & past History of other tumors:** increase the risk
3- **Family history:**
   - Sporadic cancer ovary 90-95%
   - Hereditary cancer ovary 5-10%
   - **Lynch II syndrome,** mutations in BRCA1 & II genes → CA breast & ovary.
4- **Premalignant lesions:** as papillary serous cystadenoma

- **Factors increase Cancer ovary:**
  1- Infertility & exposure to clomiphene citrate (incessant ovulation)
  2- High fat in diet, mumps oophoritis & talc powder exposure
- **Factors decrease cancer ovary:**
  1- OCP (**inhibits** ovulation), pregnancy & lactation
  2- Prophylactic oophorectomy in high risk groups
  3- Oophorectomy in females > 40 years

Pathology:

1ry :

- **Specific:**
  - Epithelial tumors
  - Germ cell tumors
  - Sex cord stromal tumors
  - Gonadoblastoma (from dysgenetic gonads)
- **Non specific:** soft tissue non specific to the ovary e.g. angiosarcoma

Epithelial malignant tumors

- **Serous cystadenocarcinoma (50% of malignant tumors):**
  - Contains psammoma bodies
  - CA 125 (carcinogenic Ag)
- **Endometroid CA :**
  - Resembles endometrial carcinoma OR associated with it
  - May arise from foci of endometriosis of the ovary
- **Mucinous cystadenocarcinoma (15% of malignant tumors):**
  - If ruptures: pseudomyxoma peritonii, adhesion & intestinal obstruction
  - Tumor marker: CEA (carcino embryonic Ag)
- **Mesonephroid CA (clear cell CA)**
  - Usually malignant & contains glycogen
  - Contains hobnail bodies (collapsed cell on nucleus with cytoplasmic projection)
- **Brenner Trs :**
  - Islands of transitional ep. with coffee bean appearance + fibrous stroma.
  - Bilateral in 5%
  - Secrets estrogen
- **Undifferentiated types, unclassified types & mixed types**

Sex cord stromal tumors

General characters of sex cords stromal tumors:

- Unilateral
- Lobulated
- With abnormal hormonal production
- Yellowish
- Moderate size

- **Granulose cell tumors:** secretes estrogen + coffee bean nucleus
  - **Call Exner bodies** (aggregated granulose cells around a homogenous material)
- **Thecoma fibroma tumors:** usually benign
  - **Secretes estrogen** → precocious puberty, menstrual disturbances, post menopausal bleeding, endometrial hyperplasia & carcinoma.
  - **Meig's syndrome** (with ascites due to peritoneal irritation + right hydrothorax due to pleuroperitoneal connections)
- **Leyding cell tumors: polyhedral cells** secrete androgens - Reinkes crystals
- **Sertoli cell tumors:**
  - **Columnar cells** secrete androgen with cleft nucleus
  - **CP** ↑ androgen→**defeminization** (amenorrhea, breast atrophy & **musculinization** (hirsutism, clitorimegaly, deep voice, ↑ muscle)
- **Gynandroblastoma:** secretes androgen + estrogen

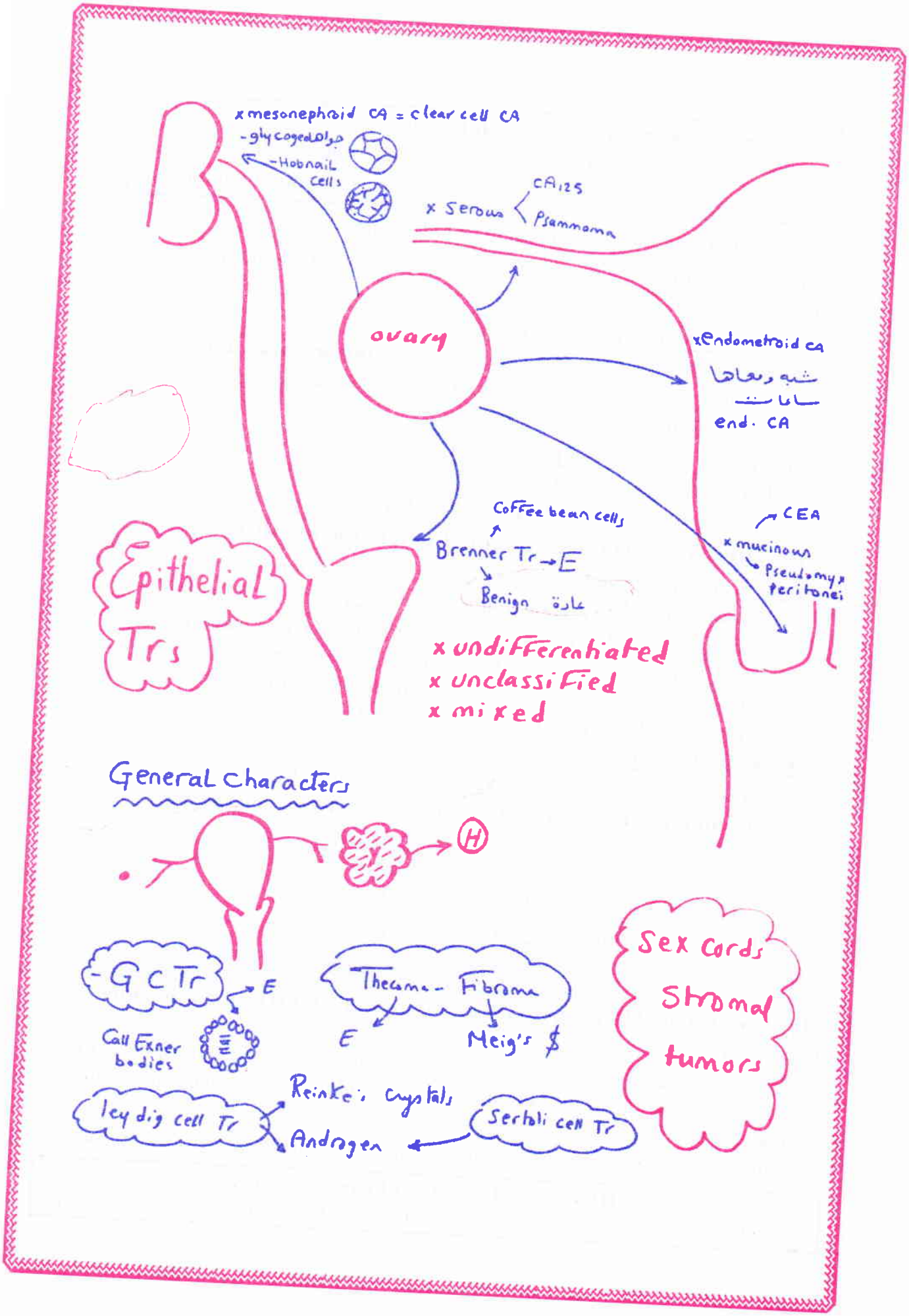
x mesonephroid CA = clear cell CA
- glycogen
- Hobnail cells
x Serous
CA125
Psammoma
ovary
x endometroid CA
شبه رحمها
سابا نت
end. CA
Coffee bean cells
Brenner Tr → E
Benign عادة
CEA
x mucinous
Pseudomyx peritonei
Epithelial Trs
x undifferentiated
x unclassified
x mixed
General characters
H
- G C Tr
E
Call Exner bodies
Theca - Fibroma
E
Meig's $
Sex cords Stromal tumors
Reinke's crystals
leydig cell Tr
Androgen
Sertoli cell Tr

Germ cell tumors

General characters of germ cell tumors:

- Unilateral, lobulated
- Rapidly growing
- Sensitive to irradiation
- Common in young age

1- **Embryoma**: the tumor contain embryoid bodies

2- **Poly embryoma**: contain embryoid bodies at different stages of differentiation

3- **Endodermal sinus (yolk sac) tumor**
   - **Extremely malignant** tumor of childhood → **tumor marker is α FP**☺
   - **Schiller - Duval bodies** (central capillary surrounded by simple papilla)
   - **Treatment:** surgery + chemotherapy

4- **Choriocarcinoma (non gestational):**
   - **Tumor marker** is HCG
   - **Treatment: platinum based** chemotherapy

5- **Immature teratoma: secrets AFP, LDH, but never HCG**

6- **Dysgerminoma** (commonest malignant germ cell tumor):
   - **From** dysgenetic gonads (with Y cell line)
   - **Tumor marker** LDH (lactate dehydrogenase), hCG (precocious puberty).
   - **MAC**: grayish pink with areas of hemorrhage & necrosis.
   - **MIC**: Large polyhedral cells surrounded by lymphocytes
   - **Spread by** lymphatic but never by blood

7- **Gonadoblastoma**:
   - **Malignant** in 50% of cases, occurs in dysgenetic gonads (y-cell line)
   - **Combination** of germ cell tumor & sex cord /stromal tumor

2ry (20% of ovarian neoplasm)

- **1ry :** Genital, extra genital (the ovary is a common site for metastasis)
- **1ry:** Overt, silent → **2ry:** Typical, atypical

Atypical (kruckenberg tumors)

{1ry is stomach 75% (upper GIT endoscopy is a must), colon, bladder, breast, cx}

- **Macroscopic**: Bilateral, solid, lobulated, spread by lymph or blood but not direct as the tumor is smooth with no adhesions + deep location of malignant cells
- **Microscopic**: Signet ring appearance (mucin displace nucleus to one side)

Histological grading of cancer ovary.

- It is classified acc. to undifferentiated cells into (G1: 0-25%, G2: 25-50%, G3: 75%)

- Auto Fertilization Theory

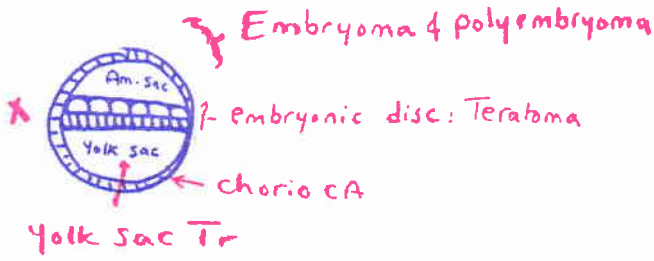

General characters

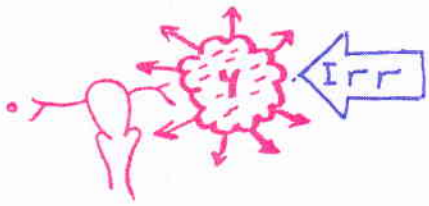

* Abn. gonads:- Dysgerminoma & gonadoblastoma

Tr markers

- **Antigens:**
  - × CA125 in all ep. Tr Except mucinous
  - × CEA, CA 19.9. in mucinous
  - × OCAA & OCA in ep. Tr.
  - × αFP in Yolk sac & other germ cell Trs
- **Hormones:**
  - × E in Functioning Tr
  - × HCG in germ cell Trs esp. chorio CA
- **Enzymes:** LDH in germ cell Trs
- **Receptors:** E Receptors in endometroid CA

	HCG	αFP
• Embryoma, • Dysgerm., • Chorio carcinoma	+	+
	+	−
• End sinus Tr	−	+

• ov Trs according to age

5% of ov Trs → 50% are malig.

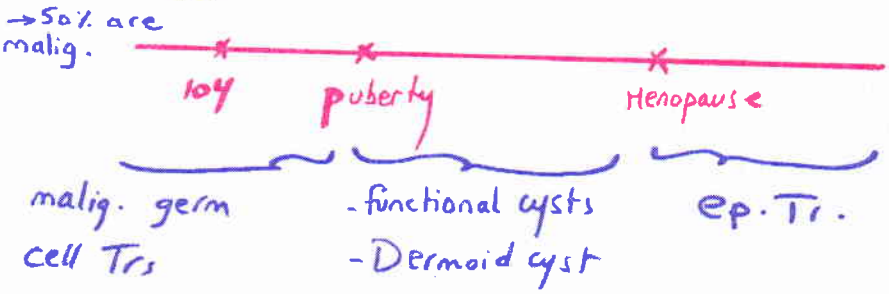

⇨ **Spread of Cancer ovary:**

- **Direct & blood** (LL **BB** KA)
- **Lymphatic** (Paraaortic, inguinal L.N & trans-fundal lymphatics to other ovary)
- **Implantation** (commonest way of spread of cancer ovary)

⇨ **Staging of Cancer ovary:**

I. Ovary (5YSR= 70%):	II. Pelvic (60%):
A: 1 ovary + NO◙ B: 2 ovaries + NO ◙ C: Ia or Ib + ◙	A: tube or uterus + NO◙ B: any other pelvic organ + NO◙ C: IIa or IIb + ◙
III. Abdominal (30%):	**IV. Distant (15%):**
A: omental microscopic implants B: MAC implants < 2 cm + no LN affection C: MAC implants > 2cm ± involvement of LN	Distant (including liver parenchyma, +ve cytology in pleural fluids or supraclavicular LN)
◙ **Means : rupture of capsule + external growth + malignant Ascites**	

⇨ **Prognostic criteria:** D-A-S-H-L-M.

⇨ **Causes of death:**

- Intestinal obstruction (commonest cause)
- Cachexia, Internal Hemorrhage, Infection, Uremia

♦ **Symptoms:**

- Asymptomatic (most cases)
- Symptoms are usually vague → late detection.
- **Bleeding:**
  - Irregular, due to abnormal hormonal production, metastasis & congestion
  - Post-menopausal
  - Amenorrhea (cachexia or bilateral ovarian destruction)
- **Pain**
  - **Somatic:** infiltration of nerves, bones.
  - **Visceral:** severe if complicated, dysuria, dyschasia., lower abdominal
- **Discharge:**
  - **Mucoid** in congestion.
  - **Mucopurulent** infection.
  - **Muco-sanguinous** infiltration of vessels.
  - **Watery:** Bladder Fistula.
  - **Feculent**, rectal fistula.
- **Masses, metastasis, fever, cachexia**

Lymph spread

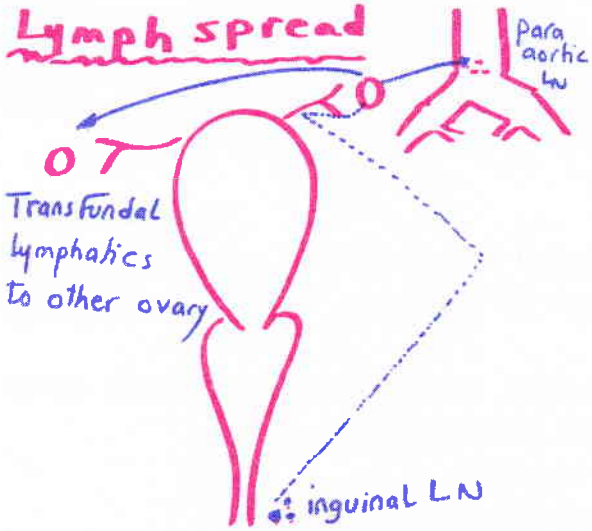

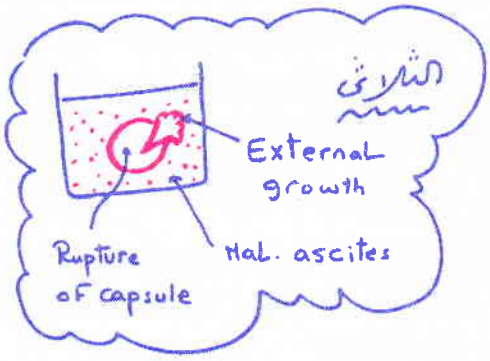

Staging of CA ovary

Stage 1 :- (ovarian)



Stage 2 :- (pelvic spread)

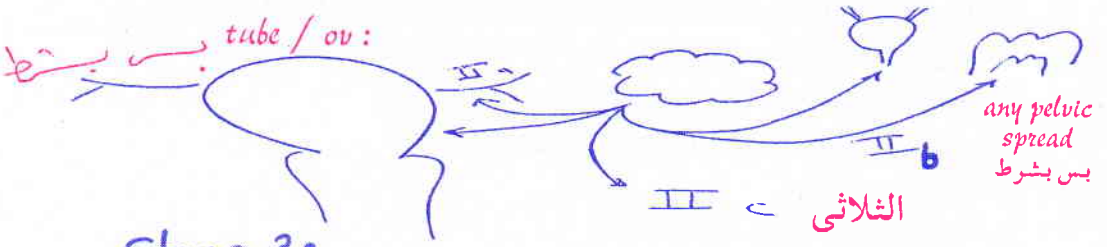

Stage 3 :-

Stage 4 :- Distant LL BB KA

- **Urinary & rectal symptoms**
- **Abdominal (most common):** Dyspepsia, discomfort, distension
- **Abnormal hormonal production:** precocious puberty, hirsutism

	Urinary	rectal
Pain	dysuria	dyschasia
Bl	hematuria	Bl/rectum
Disch (fistula)	urinary	rectal

Signs:

- **General:** Cachexia, Jaundice, Pleural effusion (Meig`s syndrome), uremia, lymph nodes, hormonal effects → estrogen, testosterone, thyroxin, serotonin)
- **Abd:** Enlarged nodular liver, ascites, masses (mobile or fixed, cystic or solid, unilateral or bilateral, tender if complicated)
- **PV:** Masses, fistulas, discharge, bleeding.
- **PR:** for rectum, parametrial, utero-sacral ligament.

Investigations:

To screen

- P/V
- Trans vaginal U/S
- CA 125

To diagnose:

- **Exploratory laparotomy:** midline subumbilical incision then take peritoneal cytology with exploration of the liver, under surface of diaphragm, intestine, omentum, L.N +
  - TAH + BSO
  - Omentectomy.
  - Selective lymphadenectomy
  - Frozen sections are done, don't allow cysts to rupture & close the abdomen by tension sutures.
- **Data suggesting malignancy on exploratory laparotomy :**

A. =Ascites (hemorrhagic) or +ve wash, adhesions &fixation.
B. =Bilateral ovarian swellings
C. =Consistency (solid or heterogeneous)
D. =DP nodules
E. =Enlarged para aortic LN
F. =Fungation outside capsule (exophytic)
G. =Great blood vessel on T. surface
H. =HNID
I. =Infiltration of omentum, gut

Final diagnosis = biopsy +histopathology

oral
N.B. Causes of Ascites with ov. Trs :-

1- obstruction of lymphatics in diaphragm
2- oozing & Transudation from the Tr
3- Associated Cachexia (hypoproteinemia)
4- Rarely hepatic nodules. (portal HTN)
5- pressure or renal vessels → ↓ UOP
6- Meig's & pseudo Meig's syndrome

oral
N.B. Causes of hydro Thorax with ovarian Trs?

1- Meig's & pseudo Meig's syndrome
2- Any case of Ascites due to pleuroperitoneal communications
3- 2ries to the lung & pleura.
4- obstruction of subphrenic lymphatics that drain the pleura

DATA SUGGESTING MALIGNANCY:

- **Symptoms:**
  - Extremes of age
  - Post menopausal bleeding
  - Rapid cachexia
  - GIT symptoms.
- **Signs:**
  - Tumor is bilateral, fixed, tender
  - Metastasis
  - Enlarged paraaortic L.N.
  - Nodule: Douglas pouch, liver.
  - Ascites, edema of lower limb.
- **Investigation:**
  - Blood: ↑ESR
  - +ve tumor markers
  - Laparoscopy, +ve cytology, biopsy.
- **During laparotomy:**
  - Bilateral, fixed tumor, enlarged L.N.
  - Hemorrhagic ascites,
  - Papillae.
  - Area of hemorrhage, infarction, necrosis & degeneration

oral ov

(HIND)

- **Others:**
  - **Cytology:**
    - Cervical (of little value) + ve in 10-20% of cases
    - Aspiration from peritoneum, ascites, peritoneum or cyst.
  - **2nd look laparotomy & laparoscopy**
  - **Radiology:**
    - Plain X ray :
      - **Abdomen:** teeth (dermoid), psammoma bodies (epithelial tumors)
      - **Bone:** metastasis
      - **Chest:** metastasis & pleural effusion
    - Barium study
    - IVP: course of ureter, hydroureter, hydronephrosis & renal function.
    - Mammography: for associated breast cancer

Treatment of CA:

- **Prophylactic:**
  - There is no high risk group (familial cases are a minority)
  - Most patients present late: stage III unlike cancer endometrium
  - There is no efficient screening program although we may do periodic bimanual examination, tumor markers CA125, TVUS +/- colored Doppler
  - Ovarian swellings, > 6cm or persistent, > 45y → prophylactic TAH+BSO.
  - COC in high risk groups
- **Active: (S C R)**

1. **Surgery :**
   - **Types of surgery:**
     - **Ia:** young, germ cell tumor, intact capsule, wedge biopsy of the other ovary ...no malignancy: unilateral sapling oophorectomy + follow up
     - **Ia old age , Ib , Ic** → TAH + BSO, peritoneal cytology, pelvic lymphadenectomy, & infracolic omentectomy
     - **After that:** cyto reduction (Debulking)
   - **Timing:**
     - **1ry:** before the chemotherapy
     - **2ry:** after the chemotherapy (6 months)
     - **Interval:** after 3 courses of chemotherapy
   - **Prognosis:**
     - Microscopic residual tumors: 60 %
     - < 2 cm residual tumors: 35%
     - > 2 cm residual tumors: 20 %

Treatment

تجميعه

Surgery

نوعها

- Ia : بشروط USO
- I كلها : إجبارى → غير كده
- بعد كده → Cytored.

امتى

1st CR — interval CR — 2nd CR

3m — 3m

Chemo — 6m

لو فشل

- Signs of mal.
- Spillage لو

Chemo

- نوعه
- inv
- Rec.

Radio therapy

- No Role
- Indications بس ف
- انواعها

- 2nd look laparotomy or laparoscopy
- ov. cyst during pregnancy

Oral

- what is optimal cytoreduction? Residual masses < 2 cm
- " " The aim of " ? remove larger lesions which are chemo resistant (low growth rates than smaller ones)
- what are The most imp. Post op. Compl of cytoreduction?
  - if larger lesions are left → oozing → Ascites
  - DIC (dilutional coagulopathy from excess fluid replacement)
  - ARDS, DVT, PE
  - hge (intra op or post op) اهم واحده

- **Signs of malignancy intra operative** e.g infiltration, ascites, adhesions
- **Spillage of the tumor is managed by:** Peritoneal toilet by distilled water, chemotherapy or intraperitoneal P 32

2. **Chemotherapy**
   - **Type :**
     1. Epithelial tumors: platinum
        a. Cis platinum (oto, nephro, neuro toxic)
        b. Carbi platinum (myelotoxic)
     2. Sex cord stromal tumors: progesterone
     3. Germ cell tumors:
        - **V** (vincristine) **A** (adriamycin) **C** (cyclophosphamide)
        - **P** (cis- platinum) **E** (etoposide) **B** (bleomycin)
   - **Investigations before Treatment:** CBC, LFT, KFT
   - **Recurrence after Treatment:**
     - **Resistant:** recurrence before 4 m: no hope
     - **Intermittent recurrent:** recurrence between 4 & 12 m
     - **Sensitive but recurrent:** recurrence after 12m:
       - **Treatment:** surgery, chemo, irradiation & taxol

3. **Irradiation:**
   - It has no role except in the treatment of dysgerminoma or when the residual part of the tumor < 2cm
   - It's replaced by chemotherapy even in dysgerminoma (very radiosensitive)
   - **External**: whole abdomen by moving strip 2.5 cm daily
   - **Internal**: in stage Ic or if capsule ruptures during removal → intraperitoneal instillation of colloid gold 198 or colloid P32 (better) → emit β particles which destroy malignant cells
4. **Palliative:** scheme
5. **2nd look laparotomy & laparoscopy** (dangerous & better avoided)
   - **Indications:**
     - Recurrence of the tumor
     - Advanced stage
     - Advanced age
     - Persistent high CA 125
6. **Follow up**:
   - **Tumor markers (CA 125)**
   - **Radiology**
   - **2nd look laparoscopy (dangerous) & Laparotomy:** Take multiple biopsies & peritoneal cytology, remove any residual tumor, proved to be unimportant

Oral تجميعات

- Cytology "smear" can be done from:-
  - Culdocentesis :- aspiration or lavage
  - peritoneal aspiration or washing.
  - Aspiration of cyst.

- The commonest:-
  - ovarian swelling → Follicular cyst
  - " neoplasm → serous cystadenoma
  - " malig. → serous cystadenoCA
  - " Tr with preg. → serous & dermoid cysts
  - " non neoplastic cyst with pregnancy → Corpus luteum cyst
  - " malig. with pregn. → Dysgerminoma
  - " Tr in D.P. → Endometriomas
  - " Tr in uterovesical pouch → Dermoid cyst

- Functioning ov. Trs

Sex cord – Str. Tr	Germ cell Tr	ep. Tr
• Feminizing / virilizing	• Struma, Carcinoid	• Brenner
• Gynandroblastoma	± dysgerminoma, chorioCA	(Cirr. of stroma)

- Solid ovarian Trs:-

Benign	malign.	functioning
- Brenner	- ov Carcinoma, Dysgerminoma	• Granulosa – Theca
- Thecoma, Fibroma	- Mal. solid teratoma	• leydig – Sertoli
- Benign solid teratoma	- Krukenburg	

EPITHELIAL DISORDERS OF THE VULVA

According to international society for study of vulvar diseases "ISSVD" 1989

- **Non neoplastic disorder:**
  - **Lichen sclerosis (atrophic).**
  - **Sq. cell hyperplasia (leukoplakia, hypertrophic)**
  - **Others:**
    1. **Psoriasis:** scaly lesion, Treatment: UVR, salicylic acid, C.S
    2. **Lichen planus:** Purple, polygonal not scaly, Treatment: CS
    3. **Reactive dermatitis:** Allergy, Treatment of the cause, CS
- **Mixed non neoplastic & neoplastic epithelial disorders**
- **Vulval intraepithelial neoplasia:**
  - **Vulva squamous intraepithelial neoplasia (VIN 1, 2, 3)**
  - **Non squamous intraepithelial neoplasia:** Paget disease & melanoma 5%
- **Invasive tumor**

Vulval dystrophies

- **Definition:** disorder of epithelial growth (dystrophy means poor nutrition)
- **Etiology:** unknown but theories
  - **Ch**ronic irritation, infection as candida (prolonged itching)
  - **A**utoimmune
  - **Lo**cal factors (**chalones**) which are epidermal growth inhibiting factors when ↑ → epidermal atrophy & when ↓ → epithelial hypertrophy.
  - **N**utritional (deficient Fe, vit B) & metabolic: DM,
  - **E**nvironmental
  - **S**ocial & familial
- **Types:** squamous cell hyperplasia (leukoplakia), lichen sclerosis & mixed type
- **Symptoms:**
  - Age: Postmenopausal female (leukoplakia can affect any age☺)
  - Asymptomatic
  - White or red patches, skin cracks & ulcers.
  - Pruritis, dyspareunia (due to shrinkage of vulva = kraurosis vulva)

- **Signs**:
  - **White well defined glistening patches**
    - Involve labia, perineum, perianal region, shrinkage of vulva
  - **Red area & Skin cracks**
- **Differential diagnosis of white lesions:**
  - **Lichen sclerosis** (commonest vulval white lesion) & **Leukoplakia**
  - **Cancer:** VIN or invasive
  - **Infections:** candida, condyloma
  - **Other vulval dermatosis:** psoriasis, lichen planus & contact dermatitis
- **Complications**: atypia may be present → progress to CA in 1-5%☺ حفظ

	Lichen sclerosis	Leukoplakia
Pathology	• Thin, dry & smooth • White (cellophane like)	• Well defined, Raised • White or Red patches
Inv	• **To exclude malignancy:** colposcopy, toluidine blue, biopsy • **To search for a cause:** swab for candida	
	• **Biopsy:** Inactive thin epithelium, hyperkeratosis, loss of elastic tissue	• **Biopsy:** hyperkeratosis, acanthosis, papillomatosis
Ttt	• **General:** ▪ Follow up to detect any malignant change. ▪ Treatment of the cause. • **Empirical treatment:** ▪ Analgesic. ▪ Block of nerves by injection of absolute alcohol. ▪ Corticosteroids. ▪ Division of nerves by circular incision around the vulva (lasts for 3-6m). ▪ E & emollients, testosterone (was considered standard treatment). ▪ Fungicides. • **Surgical treatment: as leukoplakia.**	• **General:** ▪ As lichen sclerosis • **Empirical treatment** Corticosteroids ✦local hydrocortisone 1% 1x3 (for 6 wk-6 m) ✦local clobetasol propionate 0.05% 1x3 (for 3m) • **Surgical treatment:** ☆Local destruction ☆Wide local excision ☆Simple vulvectomy

VIN

A-Squamous

- **Etiology:** Look CA vulva
- **Pathological types:**
  - **VIN I:** Malignant cells in lower 1/3
  - **VIN II:** In lower 2/3
  - **VIN III:** the whole thickness is affected but no invasion of basement membrane
- **Symptoms:**
  - **Any age** (around 40 years)
  - **Pruritis valve or Vulval pain**
  - **Discoloration** of the vulva
- **Signs: usually no signs**
  - It affects the urethral meatus, around the introitus, perineum, and groin.
  - There is change in the color {white becomes pink or erythematous or brown)} or change in contour {flat becomes raised (velvety or popular or macular)}
- **Investigations:**
  - **Colposcopy**: for vulva, vagina & cervix
    - Staining by **acetic acid** 3-5% for 5 min {acetowhite areas are abnormal}
    - **Toluidine blue** 1% {abnormal areas remain stained blue}.
  - **Biopsy**: cells with malignant criteria either VIN I, II, III (**usually multifocal**)
- **Treatment:**

1- Local destruction by cryo or LASER: Painful ulcer (best is CO_2 LASER)
2- Wide local excision: 5 mm safety margin
3- 10 Years follow up (Recurrence of invasive malignancy is 20-30%)
4- Simple vulvectomy

B- Non Squamous

- **Paget's disease (adenocarcinoma in situ)**
  - **Paget cell:** atypical apocrine cells, in the dermis, totipotent, large with a pale vacuolated cytoplasm {due to mucin} & dark hyperchromatic central nucleus).
  - **MAC**: Eczematous lesion, sharply demarcated, hyperemic with scaly areas (pathognomonic cake icing effect).
  - **Treatment**: Simple vulvectomy, 1-2% → underlying adenocarcinoma of apocrine sweat glands (in 100% of Paget disease of breast → underlying duct carcinoma).

- **Melanoma in situ 5%:** Treatment: Simple vulvectomy + Follow up
- **Bowen's disease of the vulva**
  - Clearly defined, unifocal raised scaly, red background, white hyperkeratotic islands with serpiginous edges.
  - **Investigation:**
    - **Biopsy:** Hyperkeratosis, acanthosis, papillomatosis, inflammatory infiltration
  - **Treatment:** treatment of the cause , Corticosteroids or Vulvectomy

Pruritis vulvae

- **Definition:**
  - Itching or tendency to itch the region of vulva
- **Cause**
  - **General:**
    - DM
    - Menopause
    - Parasites e.g. scabies
    - Jaundice
    - Leukemia
    - Uremia
    - Skin diseases
  - **Local:**
    - Vulval dystrophy
    - **Infection** e.g. Candida, Trichomoniasis
    - **Neoplasia**
  - **Psychosomatic**
  - **Idiopathic**
- **Symptoms**: History of DM or Jaundice
- **Signs**
  - **General**: Manifestations of DM, uremia, jaundice, leukemia
  - **Local**: Examination for Infection, malignancy, Ulcers
- **Investigations**
  - **General**:
    - Analysis for DM
    - Stool for: B, oxyuris
    - Blood Analysis

- **Local:**
  - Smear, Culture, Colposcopy,
  - Biopsy
  - Any old patient with long standing pruritis vulvae is cancer vulva until proved otherwise

Treatment

- **Treatment** of the cause
- **General:** Sedation, Antihistaminics, Estrogen in postmenopausal ♀
- **Local treatment.**
  - Calamine lotion
  - Estrogen
  - Corticosteroids
  - Anesthetics
  - Testosterone
- **In resistant cases:**
  - Biopsy to exclude cancer vulva.
  - Subcutaneous injection of local anesthetic or corticosteroids or alcohol.
  - Cicumvulval incision to cut nerve fibers (**Ball**'s operation).
  - ***Simple vulvectomy*** in vulval dystrophy

Ulcers of the vulva

- Trauma: infected perineal tear of episiotomy
- Miscellaneous: Behcet
- Inflammations:

	Shape	Edge	Base	Pain
Syphilitic	Rounded	Sharp	Hard	No
Herpes Genitalis	Multiple	Sharp	Superf	+
H Zoster	Unilateral	Sharp	superficial	+
Bilharizial	Irregular	Irregular	Superficial granular	+
TB	Irregular	Undermined	Yellow	+
Scc	Rounded	Everted	Indurated	+
BCC	Rounded	Rolled in	Indurated	+

EPITHELIAL DISORDERS OF THE VAGINA

Vaginal adenosis (Rare)

- Columnar epithelium replaces squamous epithelium → mucus secretion.

- **Etiology:**
  - Faulty differentiation or distribution of Mullerian duct tissue or DES exposure.
  - It leads to clear cell adenocarcinoma but spontaneous cure can occur.

- **Treatment**
  1- **local destruction:** cryo, laser → painful ulcers, best Co2 laser
  2- **Wide local excision:** 5mm safety margin.
  3- **10 years follow up** (recurrence of invasive mal 20-30%).

VAIN (rare)

- **Types**
  - VIN I: Mal cells in lower 1/3
  - VIN I: in lower 2/3
  - VIN III: whole thickness.

- **Symptoms:** **As** lichen sclerosis. Affects any age

- **Signs:** **No** signs

- **Investigation (Biopsy)**
  - **Cells with malignant criteria but no invasion of BM**
    - **Architectural atypia:** Pleomorphism, loss of stratification
    - **Cytological atypia:** large irregular hyperchromatic nuclei, mitotic figures

  Screening for vulval carcinoma:
  1. **Scrapping cells for cytology**
  2. **Toluidine blue dye 1%** decolorized by acetic acid 1% → areas retaining blue color are suspicious → biopsy (ulcers: false +ve results)
  3. **Colposcopic directed biopsy** as CIN but thick keratin → no vascular pattern.
  4. **Acetic acid 3%** show suspicious aceto-white areas

- **Treatment**:
  - **Unifocal lesion**: localized surgical excision (with safety margin)
  - **Multifocal**: 5% of 5fluorouracil cream or laser or cryocautery.

CANCER VULVA & VAGINA

	Cancer vulva 3-4%	Cancer vagina 1%
Age	70 y → 4% 4th genital malignancy	60 y
Smoking, PH, FH	+ve	+ve
Premalignant	VIN (low progression rate 20-30ys), Paget disease, dystrophies (in 50% of cases)	Vaginal IN, vaginal adenosis
Specific RF	Infection, HPV, HIV, chronic valvular pruritis	Infection, HPV, HIV, Exposure to DES
Site	Labia majora, clitoris then minora	Commonest in the upper posterior 1/3 of the vagina
Mac	Ulcer (kissing ulcer by lymphatics or direct spread or multifocal), fungating or infiltrating	Commonly mass
Mic	• Sq cell carcinoma, Adenocarcinoma, • Adenoid cystic cancer "Bartholin gland cancer" • Melanoma	• Sq cell carcinoma • clear cell adenocarcinoma (19 y), sarcoma botryoids "mean age is 3y"
Spread	• Direct • Lymphatic crossing, spread to inguino-femoral LN, clitoris send to LN of Cloquet → deep inguinal & external iliac → common iliac & para-aortic LN. • Blood: LLBBKA • Implantation	• Direct • Lymphatic: upper 2/3 as Cx, lower 1/3 as vulva • blood: -LLBBKA • implantation
Prog criteria	DASHLM	DASHLM
Stages & 5 y survival rate	• **TNM staging:** ▪ **T1:** confined to vulva or perineum < 2cm ✓ **T1a:** stromal invasion <1mm ✓ **T1b:** stromal invasion >1mm ▪ **T2:** confined to vulva or perineum > 2cm ▪ **T3:** reaches lower urethra, vag & anal canal ▪ **T4:** upper urethra, vag, rectum & bones ▪ **N0:** no LN metastasis - **N1:** unilateral LN affection - **N2:** bilateral LN affection	• Stage 1: in the vagina→ (5YSR 70%) • Stage 2: paravaginal tissue → 40% • Stage 3: lateral pelvic wall → 30% • Stage 4: → 15% - A: bladder & rectum - B: distant

oral N.B. ممكن تطنش

Types of vaginal neoplasms

- **Benign**
  - papilloma
  - Granuloma
  - Adenoma
  - Adenosis
- **Malignant**
  - 1ry
    - Carcinoma
      - VaIN
      - invasive
    - Sarcoma
      - adult type
      - childhood type (botryoides)
  - mets 2ry
    - esp ant. wall suburethral
    - esp from uterus (endometrial CA or chorio CA)

Lymph Drainage of The vulva & Butterfly incision

الزائد

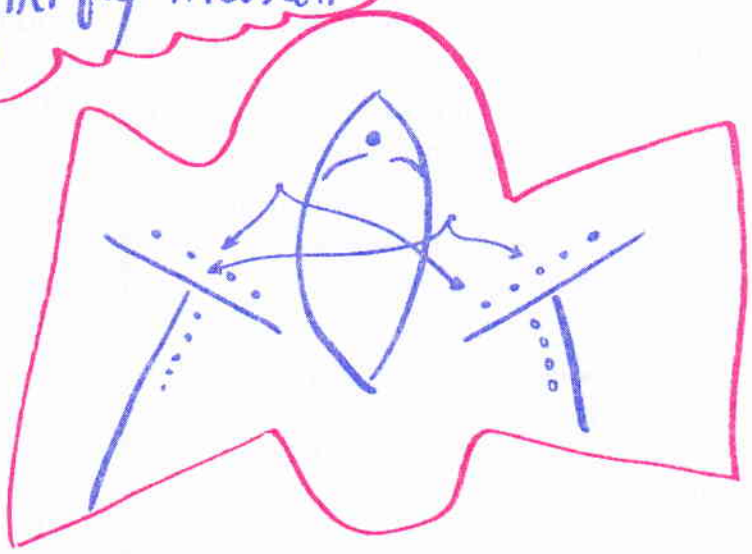

lymph. crossing لاحظ
to inguino Femoral LN

	▪ **M0:** no metastasis - **M1a:** palpable deep pelvic LN - **M1b:** distant spread • Stage 1 (T1 N0 M0) (Ia < 1mm- Ib > 1mm) → **90%** • Stage 2 (T2N0M0)→ **80%** • Stage 3 (any T3 or N1 M0)→ **50%** • Stage 4 (4a any T_4 or N_2 & 4b any M_1)→ **15%**	
Symptoms	General scheme	General scheme
Signs	General scheme	General scheme
Investigation		
To screen	PAP, colposcopy	
To diagnose	Biopsy, colposcopic directed biopsy	
For stage	Pre-operative & follow up	
Treatment		
• **Treatment of choice is** radical vulvectomy & bilateral lymphadenectomy (butterfly incision or triradiate incision) ▪ **Ia:** wide local excision ▪ **Lateral <2cm:** radical hemi-vulvectomy + unilateral lymphadenectomy ▪ **Lateral >2cm or midline:** - radical vulvectomy & bilateral lymphadenectomy ▪ **Advanced tumor**: staged operation → irradiation then lymphadenectomy then irradiation then radical vulvectomy ▪ **Radiation** - Adjuvant: postoperative for LN if ❋ LN are ≥ 4 +ve or LN of Cloquet +ve ❋ Tumor is > 4 cm or affection of (clitoris/urethra/vagina) - Curative (obsolete) minimal effect as the tumor usually radio resistant with soft vulva	1- **Radiotherapy** is the treatment of choice 2- **Surgery** ▪ **For small vaginal tumor** localized to upper 1/3 → radical hysterectomy + upper vaginectomy + pelvic LN dissection ▪ **In lower part**→ radical vulvectomy + bilateral groin lymphadenectomy + removal of the lower vaginal part ▪ **If the bladder or rectum is involved** → exentration is done.	

N.B. مراجعه فقط للعلم بالشيء

Q:- what are the complications of radical vulvectomy?

- 1st done by Passet (1912)
- The compl. are

Anesthetic
Compl as Cardiac arrest

Vascular
- Artery: hge بالزايد
- vein: DVT & PE
- lymph: lymphedema of LL & groins

Musculoskeletal
- Bone:- osteitis pubis
- Skin: Infections, ulceration.
- Nerve: parathesia over groin

organs
- Vulva: dyspareunia, disfigurement
- Vagina: stenosis, prolapse
- Ur. Retention
- CVS: H_2O & electr. imbalance

Mort rate is 2-4 % due to
- Hge
- infections
- DVT & Anesth. compl.

- Prognosis CA vulva x CA vag

CA vulva: Clitoris → احسن بدا → Extended to vag or urethra or anal Canal → Rapid spread

CA vag: اسوأ لانها Rapidly spreading

- Types of vaginal Sarcoma
  - Adult type:-
  - Childhood Type:- sarcoma botryoides at 3 yrs (grape like)

HAc: Mass of pinkish polypi
MIC: undifferentiated rhabdomyoblasts in Mykomatous tissue
III: VAC failed → radiotherapy failed → Vaginectomy + TAH + LN
Prognosis: bad (die in 2 yrs)

MASSS OF THE VULVA & VAGINA

Vulva

1. **Lipoma:**
   - **Origin:** fatty tissue of labia majora or mons pubis.
   - **Symptomatic,** resemble a hernia
   - Liposarcoma is rare
   - **Treatment:** excision & histopathology
2. **FIBROMA:**
   - Firm nodule on labia majora
   - **Ttt:**: Excision & histopathology
3. **Hideradenoma:**
   - **Histopathology:** Benign adenoma of vulval apocrine glands not connected to epidermis & capsulated
   - **C/P:** slowly growing 2cm in diameter, raised umbilicated
   - **Treatment:** excision & histopathology
4. **Chronic inflammatory swelling:**
   B, TB, HPV
5. **Edema of the vulva**
6. **Congenital hypertrophy of clitoris or labia**
7. **Urethral Caruncle**
   - Small < 1 cm, bright red, tender arises from the floor of urethra & protrudes from external urethral meatus
   - **Types:**Papillomatous, Granulomatous or Angiomatous
   - **Symptoms:** Asymptomatic, pain, bleeding, discharge, masses
   - **DD:** carcinoma of urethra
   - **Treatment:** Wedge excision + Treatment of the cause

Vagina

1. **Fibromyoma or Rhabdomyoma:**
   - **Origin:** CT element of the vagina
   - **C/P:** polyp or mass often within recto-vaginal septum
   - **Treatment:** Excision & histopathology
2. **Condyloma accuminata:**
   - **Due to** infection by HPV
   - **Macroscopic:**
     - Verrucous tumor in single or multiple clusters
     - Large growths may appear on ex, vulva & perineal skin
   - **Treatment:** Chemical cauterization with acetic acid
     - Cryo, laser, interferon
     - Avoid podophylline in vaginal lesions
3. **Papilloma**

Vulval cysts

1. **Bartholin** cyst & abscess (commonest)
2. **Inclusion dermoid cyst:**
   - The epithelium is embedded beneath the surface e.g. after episiotomy.
   - Asymptomatic if infected → abscess
   - **Treatment:** Excision or drainage & antibiotics if abscess.
3. **Endometrioma:**
   - In the labia at site of previous episiotomy.
   - **Diagnosed** by histopathology.
   - **C/P:** cyclic bleeding, dyspareunia.
   - **Treatment:** excision or hormonal
4. **Hydrocele of canal of Nuck:**
   - Cystic mass along the canal of Nuck
   - **D.D.:**
   - ***Bartholin's cyst:*** Bartholin is more posterior,
   - ***Hydrocele of canal of Nuck*** may extend to inguinal canal, if communicating with the peritoneal cavity → disappears on lying down.
   - **Treatment:** Dissection of hernial sac, high ligation & reinforcement of external inguinal ring
5. **Hematoma:**
   - Complication of episiotomy
   - Cystic, dark red, tense, tender
   - **Treatment :** antibiotics +
   - ***Small:*** evacuation, or conservative
   - ***Large:*** evacuation, homeostasis of bleeding vessel & drain

Vaginal cysts

1. **Gartner's cyst:**
   - Cystic dilatation of Gartner duct (remnant of Mesonephric duct)
   - **Site**: along ant. & lateral walls of the vagina, may extend to the paracervical tissues and displace the ureter
   - Single, usually small (<2cm) & unilateral
   - They contain mucin
   - **Ttt: Conservative unless enlarging:**
     - Excision.
     - Marsupilization: if reaching paravaginal tissues, to ureteric injury.
2. **Epithelial inclusion cyst:** The vaginal epithelium is buried under mucosa following trauma or episiotomy.

Sites: commonest site is the site of healed episiotomy on the posterolateral wall

Contents: cheesy substance (degenerated cells). The wall is stratified squamous

Treatment: Excision

3. **Endometrioma**
4. **Urethral diverticulum:**
   - Cystic swelling of the urethra. Pressure on the swelling → urine or pus.
   - **Urethroscopy** helps diagnosis.
   - **Treatment**: urethroplasty.
5.
   - Multiple cysts filled with gases due to non-specific vaginitis or T. Vaginalis
   - **Treatment**: of infections.

FAMILY PLANNING

Family planning

✱ **It includes**

1- Contraception
2- Sterilization
3- Treatment of infertility
4- Management of recurrent abortions
5- Counseling in recurrent fetal malformations

◈ **Pearl index (Raymond pearl):** failure rate among 100 ♀ using the method continuously for 12 months

$$\frac{\text{No of pregnancy X 1200 (No of months by 100 women in 12 months)}}{\text{Total months of exposure to pregnancy}}$$

⇨ **E.g. 500 ♀ used a method for 20 m during which 5 pregnancies occurred**

$$\frac{5X\ 1200}{500X20} = 0.6\ HWY$$

◈ **Perfect use rate:** failure rate during the first 12 months of use among couples who use the method perfectly (theoretical efficiency)

◈ **Typical use rate:** failure rate among average users in the first 12 months of use

◈ **No ideal method,** but the choice is tailored to the suit the couple

NON HORMONAL CONTRACEPTION

I-Natural methods

(No medical contraindications but failure rate 12-30 / 100 women per year)

Lactational amenorrhea method (LAM)

◈ **Idea:** lactation is used as a method of contraception

◈ **Mechanism:** suckling → ↑PRL → inhibits GnRH

◈ **Advantages:** NASER (from 10% to 90% especially in 1st 6 months)

- No preparations are needed & available from the 1st day
- Advantages of breast feeding for the mother & the neonate

◈ **Disadvantages:** no protection against STD & difficult بشروط قاسيه.

- Effective in the 1st 6 month postpartum
- Nearly fully breast feeding {6 times by day & 2 times at night}
- The patient has amenorrhea. Breakthrough bleeding makes it unreliable

oral

• Aim of contraception :-

لصالح

الأم — الطفل — الأسرة — المجتمع

Maternal sake

- Medical & obstetric reasons for prevention of pregnancy

for infant sake

Better health & Care ↓ ↓ Morb. & Mort.

For family sake

- Limitation of family size
- Birth spacing
- Delaying 1st child

بعض الناس (موضة)

For community sake

- Limitation of pop. out growth

• Methods

- **Non hormonal**
  - Natural
    - x LAM
    - x FAM
    - x adoption of Coital Tech.
  - Barrier.
    - chemical
    - Mechanical
  - sterilization
    - ♂ vasectomy
    - ♀ tubal ligation
      - laparoscopic
      - hysteroscopic
      - laparotomy
      - post colpotomy
  - IUCD
    - medicated
    - non med.
- **hormonal**
  - IUS
  - pills
    - COC
    - POP
  - injectables
  - implants

٤ نقط لهم لأى وسيلة

x Idea : فكرة عمله — x adv NASER

x Mech. : ازاى — x Disadv 2D

Fertility awareness method (FAM) = safe period

- **Idea:**
  - Prevent coitus at the fertile period of the female.
  - Sperm can live for 2-3 days while ovum can live for 6-24 hr

- **Mechanism:**

  1- **Calendar method:**
  - Record the length of the last 8 cycles.
  - Determine the fertile period:
  - **1st fertile day**= shortest – 18
  - **Last fertile day**= longest - 11

  2- **Cervical mucus assessment method:** (intercourse in dry days only) allowed in
  - The 1st 4 days following menstruation &
  - After 4 days after the peak of cervical mucus
  - E → profuse discharge = wetness.

  3- **Basal body temperature method:** intercourse is allowed in:
  - The 1st 4 days following menstruation &
  - After 4 days after rise in temperature.
  - Progesterone raises basal body temperature

  4- **Sympto-thermal method:** combination of the cervical mucus & temperature

- **Advantages**: **NSAER + no preparation**

- **Disadvantages:**
  - **Dose not prevent against STDs** & Difficult (needs couple cooperation)
  - **Signs of fertility** can't be relied on, so high failure rate 15 – 30/ HWY

Adoption of coital techniques

- **Forms:**
  - **Coitus interruptus** (withdrawal before ejaculation)
  - **Coitus interfemoris**

- **Disadvantages:**
  - Pregnancy is 20/HWY (some sperms may be present in secretions before ejaculation).
  - Less sexual satisfaction → neurosis, pelvic congestion, menorrhagia, leucorrhea & backache

Adv :-

- No Systemic side effect
- Available
- safe
- Effective
- Reversible

disadv :-

- Difficult
- Doesn't prevent against STD.

Mechanism of FAM

1- Calender method

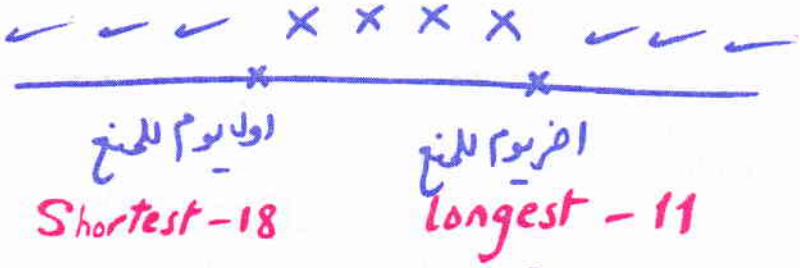

2- Cx mucus method (Billing method)

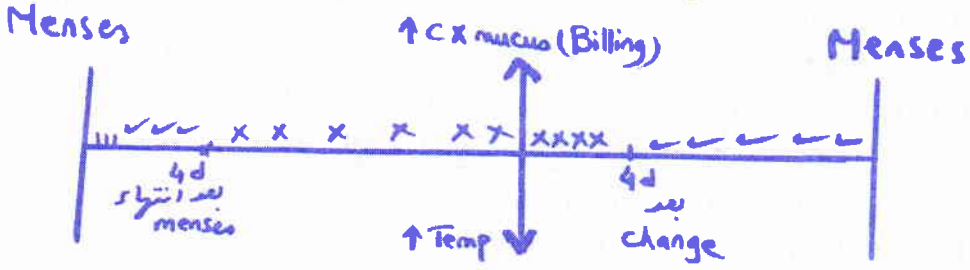

3- Basal body Temp. changes

II-Barriers

- **Idea:**
  - Preventing the sperm from reaching the ovum
- **Mechanism:**
  - Physical (barriers) or chemical (spermicidals) blocking the sperm from reaching the cervical canal
  - Spermicidals are usually added to the physical barriers to ↑ efficacy.

Male condom (male sheath, French letter)

- Formed of latex, 15 X 3.5 X 0.02-0.07 cm
- Damaged by heat or lubricants, failure rate 3 (perfect use) - 13 (typical use) /HWY

Non contraceptive benefits of male condom

1. Protection against STD, PID, CIN, VIN, VaIN
2. Treatment of immunological infertility.
3. Collection of semen by special condoms (spermicidal free).
4. Collection of urine & proper cystoscopy in case of vesico vaginal fistula
5. Can be used in cases of premature ejaculation.
6. It is used in clinics as a sheath for TVUS probes.

Precautions of condoms

1. Apply to erect organ.
2. It is applied before intercourse.
3. Withdrawal before erection is lost

Female condom: (Femidom)

- Polyurethrane, 17 X 8 cm, with opened end & closed upper end.

Diaphragms: (Dutch cap)

- Dome shaped, 50-95 mm in diameter.
- It is not removed before 8 hours to allow the spermicidal to act.
- It may lead to cystitis if large & compresses the urethra.
- Can be used in multipara & not used with prolapse (needs vaginal tone)

Cervical cap

- Cup shaped 22-31 mm in diameter.
- It is applied directly on the cervix
- Less effective in multipara
- Used if there is prolapse & diaphragm can not applied

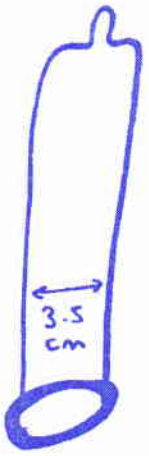

سمك

0.02 – 0.07

male condom

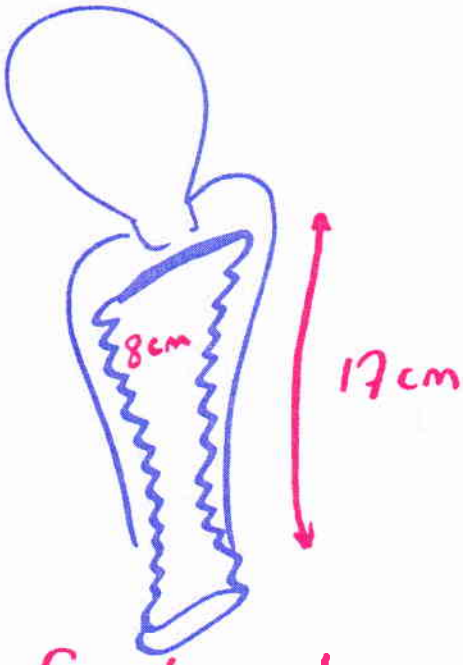

female condom

N.B. local clindamycin interfere with the action of latex products (condoms & diaphragms), ↑ Failure rate. يوسع ال pores ويعدى sperms

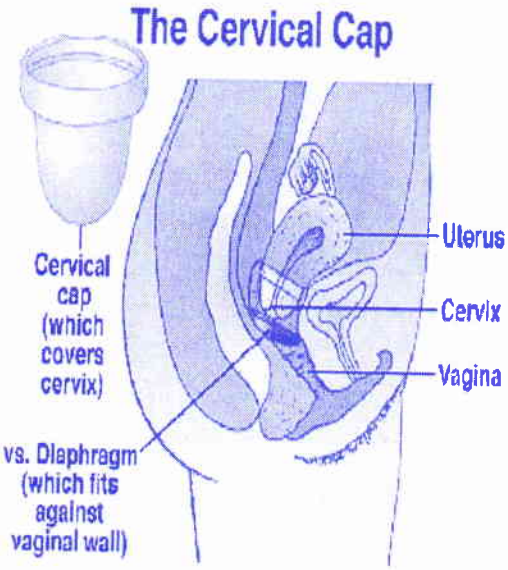

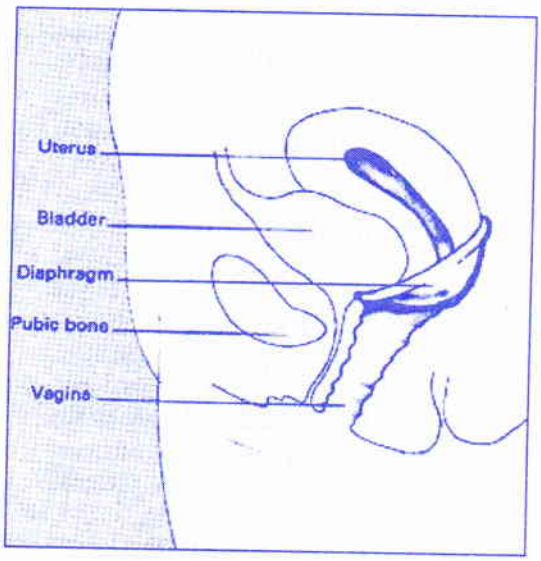

- **Spermicidals**:
  - Nonoxynol & octoxynol, added to other methods, failure rate 30/HWY
  - Used as suppository, jelly or aerosol (best distribution).
  - They act as detergents destroy the cell membrane + interfere with O2 uptake.
  - **Precautions of spermicidals**
    1- Apply for few minutes till spread.
    2- Intercourse within 2 hours.
    3- No douches after intercourse for 6-12 hours
- **Vaginal sponge:**
  - It is polyurethrane sponge containing nonoxynol & octoxynol.
  - It is easy to apply & remove
  - It is placed for up to 24 hrs in the vagina & removed 6 hrs from the last coitus.
  - Side effects: toxic shock syndrome if left long due to infection by staph aureus.
- **Advantages:** NASER + prevent against STDs
- **Disadvantages:**
  - Difficult, needs resupply & special acts that interrupt the coitus & ↓ sensation
  - May cause allergy + high failure rate 13 -20 %

III) Intra Uterine Device

- **Idea:**
  - It is a device made of polyethylene + barium (radiopaque to confirm the site) + 2 threads
  - Prevent implantation (NOT OVULATION)
- **Types:**
  - **Non medicated:** Lippes loop (double S shaped), Dalcon shield, Margulis coil, Ota ring, safe T coil (half life is indefinite)
  - **Medicated:**
    - Less pain, bleeding & better protection than non medicated.
    - **Copper** {Cu T200 (3y), Cu T380 (5y), cu 7}.
    - **Silver** (Nova T 7y)
    - **Progesterone (expensive)**
      - Mirena, Levonova for (5 y) → 52 mg levonorgestrel
      - progestasert for (1 y) → 38 mg progesterone
    - IUD with **antiPG OR antifibrinolytics**.

N.B. Toxic shock syndrome:-

- Cause:-
  - Tampon use → introduce staph aureus
  - St. aureus multiplicates in blood in tampon → exotoxin → C/P
- C/P :- (after 2nd day of menses)
  - FAHHR
  - Septicemia → LCF, RF, hemolysis, hypotension

Diarrhea, rash, DIC

- TTT :-
  - Resuscitation in ICU
  - Remove tampon
  - Antibiotics according to C&S from vagina & tampon.
    Methicillin or amoxacillin 1-2g/4 hr.
  - prophylaxis :- Tampons should be changed frequently (3-4 times/day) & external ones at night.

Mechanism

1. Aseptic endometritis
2. Uterine & tubal irritability → inhibit ovum transport & implantation.
3. Cu IUD (spermicidal, inhibits carbonic anhydrase enzyme which is necessary for implantation)
   - **Advantages**: it allows the use of smaller IUDs without ↓ efficiency
4. Progesterone (atrophic endometrium, thick cervical mucus)
5. Silver → ↑ half life of IUD by ↓ CU disintegration

Timing

- During menstruation or Emergency post coital
- Post partum or post abortive during the 1st day or after 4-6 weeks post partum
- Postinsertion follow up: the patient is examined next period & examination is then performed every 6-12 m

Contraindications (mainly local)

- Infections or liability to infection (DM, Rheumatic heart, immune-compromised)
- Bleeding or bleeding tendency or fibroids.
- Malignancy & malformations of the uterus
- Previous ectopic, suspected pregnancy.

Advantages

- **NASER** (failure rate is 1%, 0.2% in mirena) "no systemic side effects, available, safe, effective, reversible"
- **No special acts during sexual acts**
- **Long acting (10 y),** one decision method
- **Non contraceptive benefits** (treatment of DUB, endometrial hyperplasia, protects against PID, treatment of Asherman syndrome).

Disadvantages

1. **No protection against STD**
2. **Needs a doctor** for insertion and removal
3. **Pain:**
   - **colicky pain & backache:** reassure + NSAID
   - **Spasmodic Dysmenorrhea:** reassure + NSAID
   - **Congestive Dysmenorrhea:** Exclude infection + NSAID
   - **Post insertion pain & syncope:** Exclude perforation + NSAID
4. **Discharge:** mucoid or mucopurulent → Exclude infections

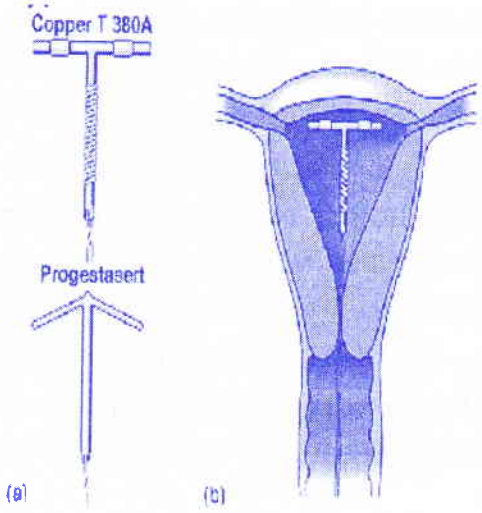
Copper T 380A
Progestasert
(a)
(b)

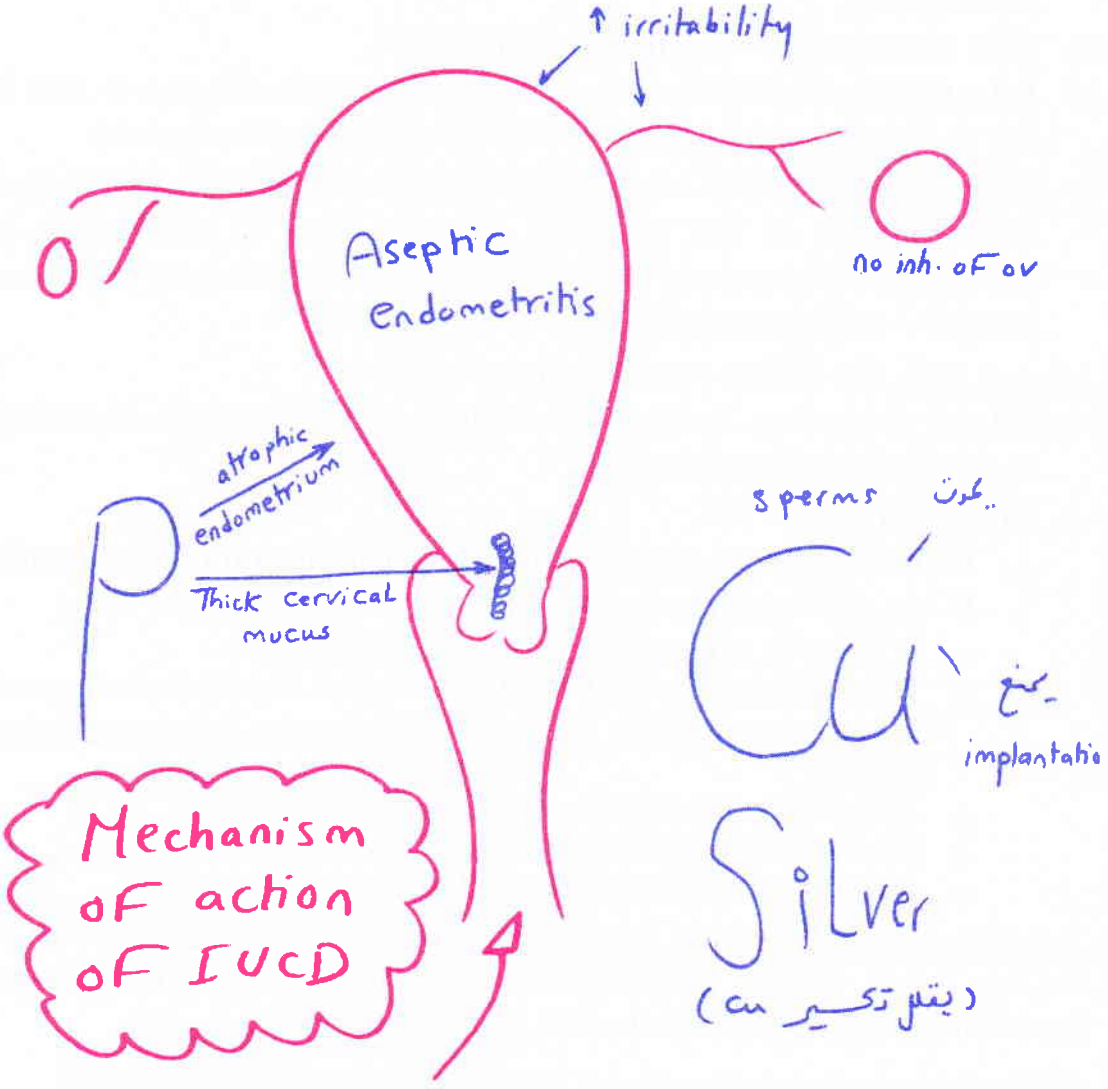
↑ irritability
Aseptic endometritis
no inh. of ov
atrophic endometrium
Thick cervical mucus
sperms يموت
Cu
يمنع implantation
Silver
(يقلل تكسير Cu)
Mechanism of action of IUCD

5. **Bleeding:**
   - **Post insertion** (exclude perforation & reassure)
   - **Menorrhagia** by 25-50% due to endometritis, ↑ PG & Leukotriens
   - **Metrorrhagia** exclude local cause, give antiPG & antifibrinolytics
   - **If bleeding is persistent**: use smaller or medicated IUD or change the method
6. **Perforation:** lack of experience & malformation of uterus (RVF, small uterus). It occurs at insertion (severe persistent pain + bleeding) or later due to gradual perforation (end of 1st month). Treatment: remove by laparoscopy
7. **PID (esp 1st month):** insert IUD by aseptic technique & not in a patient with risk for PID. Treatment: Antibiotics till fever ↓ then remove the IUD & use other method (previously actinomyces Israeli was common).
8. **Pregnancy:**
   - **Cause:** displacement, expulsion, uterine malformations & perforation.
   - **C/P: amenorrhea + confirm by βHCG /US**
   - **Intrauterine** (1-2%): the % of abortion & septic abortion is 50% if left & if removed 25% (remove IUD only if accessible threads)
   - **Ectopic** (1-2/ 10000): may ↑ incidence due to ↑ tubal infection & ↓ tubal motility or has no effect (relative ↑ as it is effective in preventing IU pregnancy but has no effect in preventing EP). Treat as Ectopic + avoid IUD later on.
9. **Missed IUD** the patient can not feel the threads
   - **Cause:** pregnancy, Perforation, Expulsion, Agglutination of threads to the fornix (commonest).
   - **Management:**
     1. **History taking & examination by speculum to find the threads.**
     2. **If not → Pregnancy test and U/S**
        - **If there is pregnancy:** manage as pregnancy
        - **If no pregnancy → IUD site** (X rays lat & AP views + sound, hysteroscopy, HSG). Uterine exploration by Bozeman forceps is tried.
        - **If intrauterine:** D&C or hysteroscopic removal
        - **Perforation:** removed by laparoscopy
        - **Expulsion:** insert another IUD or change the method
10. **Expulsion (50% in the 1st 3 month):** due to pregnancy, unfit (too small or too large), uterine malformations, bad technique of insertion or insertion immediately postpartum. It occurs usually with menses.
11. **Difficult removal or destruction of IUD:** D&C or hysteroscopic removal

Technique of insertion

Counseling: any client must know

1. Type of IUD, duration of action, failure rate
2. Self examination after each menstruation to feel threads
3. Warning signs as missing threads, severe pain, discharge or bleeding

Timing:

- **Postmenstrual** (cervix is still opened, sure no pregnancy) = interval insertion
- **Post abortion** by one week, **Postpartum** (1st 48 hours or after puerperium)
- **Postcoital contraception**

Mechanism:

1. **Anesthesia (no need)**, just 2 suppositories of anti PG 1/2 hour before
2. **Position:** lithotomy
3. **Bimanual examination**: for uterine size, position, any contraindication
4. **Cusco speculum**: sterilize cervix by antiseptic solution
5. **Grasp anterior lip of cervix** by volsellum
6. **Uterine sound**: for length & direction of uterus
7. **Two different techniques**

A. **The push-out technique:** for inert devices as Lippes loop

- The inserter tip just passes the internal cervical os and the piston then pushes the device inside the uterus
- The nylon threads are then cut 3 cm from the cervix

B. **The withdrawal technique:** Used for copper devices

- The inserter is introduced to reach near uterine fundus, then the outer sheath is withdrawn externally
- This technique reduces the incidence of uterine perforation

Follow up: the patient is examined after the next menses & then every year

Indications of removal:

1. When pregnancy is desired
2. If pregnancy occurs
3. If complications occur
4. Each device has a certain half life
5. After menopause usually by one year

Clinical importance of the threads

1- It is examined by the patient after every cycle to ensure that IUD is in place.

2- Easy extraction when needed if they are not felt, it is called missed IUD.

IV) Sterilization

- **Idea:** Non reversible method of contraception

- **Mechanism:**
  - **Male**:
    - Bilateral vasectomy to prevent sperms from reaching the semen.
    - It is less accepted in Egypt
    - Minor easy surgery done under local anesthesia
    - **Not immediately effective**
      - Need 12 weeks or
      - 20 Sexual intercourse or
      - 2 –ve semen analysis.
  - **Female** (Tubal ligation → closing, cutting & clipping, hysterectomy)
    - **Mini-laparotomy:** 2 – 3 cm incision above the symphysis pubis with resection of part of the tube (Pomeroy).
    - **Laparoscopy:** via diathermy or clips (Filshie or Hulka clip) or rings (Falope ring)
    - **Through posterior colpotomy or culdoscopy**
    - **Hysteroscopy:** occlusion of tubal ostia by cautery or silicon rubber
    - **During other operations or CS**
    - **Post partum ligation** via small infraumbilical incision,
      - **Disadvantage**: high failure rate due to increase vascularity which increases recanalization

- **Advantages:**
  - NASE "no systemic side effect, available, safe, effective (99.5% after one year & 98.1% in 10 y "due to recanalization"
  - Prevent against PID

- **Disadvantages:**
  1. Dose not prevent against sexually transmitted diseases.
  2. Irreversible
  3. **Risk of surgical complications** "Anesthesia, injuries, hemorrhage + wound complications" with high initial cost
  4. **Post sterilization syndrome** (menorrhagia & dysmenorrhea) "due to change the method of contraception especially OCP or due to congestion"

Timing:

- Immediately or within 1st 7 days after vaginal delivery
- During C.section
- At any time except between 7th day and 4-6 wks after delivery

Indications:

- **Failure** of other methods
- **Contraindication for pregnancy**: as severe medical disorders (as severe cardiac diseases) or liability to uterine rupture (as previous rupture uterus)
- **Couples who desire** a permanent method of contraception

Contraindications:

- Young patient
- Uncertain couple
- Marital problems or psychological instability.

Causes of failure:

- Ligation of round ligation
- Recanalization (especially post partum)

Sterilization reversal:

- For those who seek conception after they had surgical sterilization
- By removal of Falope band or Hulka clips or extraction of silicone rubber through hysterectomy or resection reanastomosis (tuboplasty).
- Success rate 10 – 40 % → ↑ incidence of EP
- ART can help in such cases

HORMONAL CONTRACEPTION

Estrogens used	Progestins used
• **Ethinyl estardiol** (EE2) • **Mestranol** (methyl ester of EE2)	• **1st generation:** ▪ **Estrane:** norgestrel, norethindrone, noresthisterone ▪ **Pregnane:** medroxy progesterone acetate • **2nd generation:** Levonorgestrel • **3rd generation:** ↑ affinity to progesterone receptors, ↓ affinity to androgen receptors than 2nd gen → ↑ potency. - **Norgestimate (Cilest)** - **Gestodene (Gynera)** - **Desogestrel (Marvelon)**

I) IUS

- The hormone releasing intrauterine systems are the most recent form of IUDs.
- It has "T" shape & contains progestin that is released directly into the uterus.
- The IUS is not a substitute for the copper-bearing IUD (much more expensive). It can be used if a woman has excess bleeding with a copper IUD.
- **Types:**
  - **Progestasert**: life span is for one year
  - **Mirena** (levonorgestrel-releasing system): life span is for 5 years
- **Mechanisms of action of IUS: In addition to the general mechanisms**
  1. Thick cervical mucus and so ↓ ascending infection
  2. Partial suppression of ovulation.
- **Advantages:**
  - ASER (failure rate is 1%) "less systemic side effect, available, safe, effective, reversible"
  - No special acts during sexual acts
  - Long acting (10 y)
- **Disadvantages:**
  - **General**: doesn't prevent against STD, difficult
  - **Disadvantages of progesterone only:-**
    - ↑ breast cancer, engorgement & mastalgia, decrease bone density
    - **Irregular menses** (don't use estrogen → becomes pregnant) , acne, hirsutism & alopecia, headache, migraine , mood changes
    - **Liability to ectopic (less than POPS)**
  - **Specific:** expensive

2) Pills

Combined Oral Contraceptives

OCPS are the most widely used hormonal contraceptive.

- **Types**
  - **Mono-phasic:**
    - **Each tab contains** the same dose of the hormones
    - According to the content of E it may be
      - **High dose** (50μg) as ovral or
      - **Low dose** with ↓ side effects of E (20, 30, 35μg) as micro-ovular, norminest fe (21 + 7 brown tab of fe)
  - **Biphasic: All tablets contain E+P** with doubling the concentration of P in the last 14 tab (e.g. Binovium but not available in Egypt).
  - **Multi (Tri)-phasic: Varying levels of E+P are given** for 21 days of the cycle. It is done to mimic the natural cycles → better tolerated & ↓ SE e.g. triovular (6 red, 5 white & 10 yellow tablets)

Tabs	6	5	10
EE2	30μg	40μg	30μg
P(Levonorgestrel)	50μg	75 μg	125μg

  - **Sequential pills**: 1st ½ of the cycle (E only) & 2nd ½ (E+P) → cancer endometrium (so not used now)

- **Mechanism of action:**
  - Inhibits of ovulation (-ve feed back on hypothalamus & pituitary)
  - Thickening of cervical mucosa (P effect)
  - Inhibits tubal motility (P effect)
  - Atrophic endometrium (P effect)
  - Inhibition of sperm capacitation (P effect)

- **Advantages:**
  - ASER "available, safe, effective (FR: 0.1/ HWY), reversible"
  - No special acts during sexual acts.
  - Extra contraceptive benefits
    - Improves anemia
    - ↓ Bleeding, PID, Benign breast disease
    - ↓ cancer endometrium / ovary,
    - ↓ Dysmenorrhea
    - ↓ Ectopic pregnancy, treat endometriosis

Mechanism of action of coc

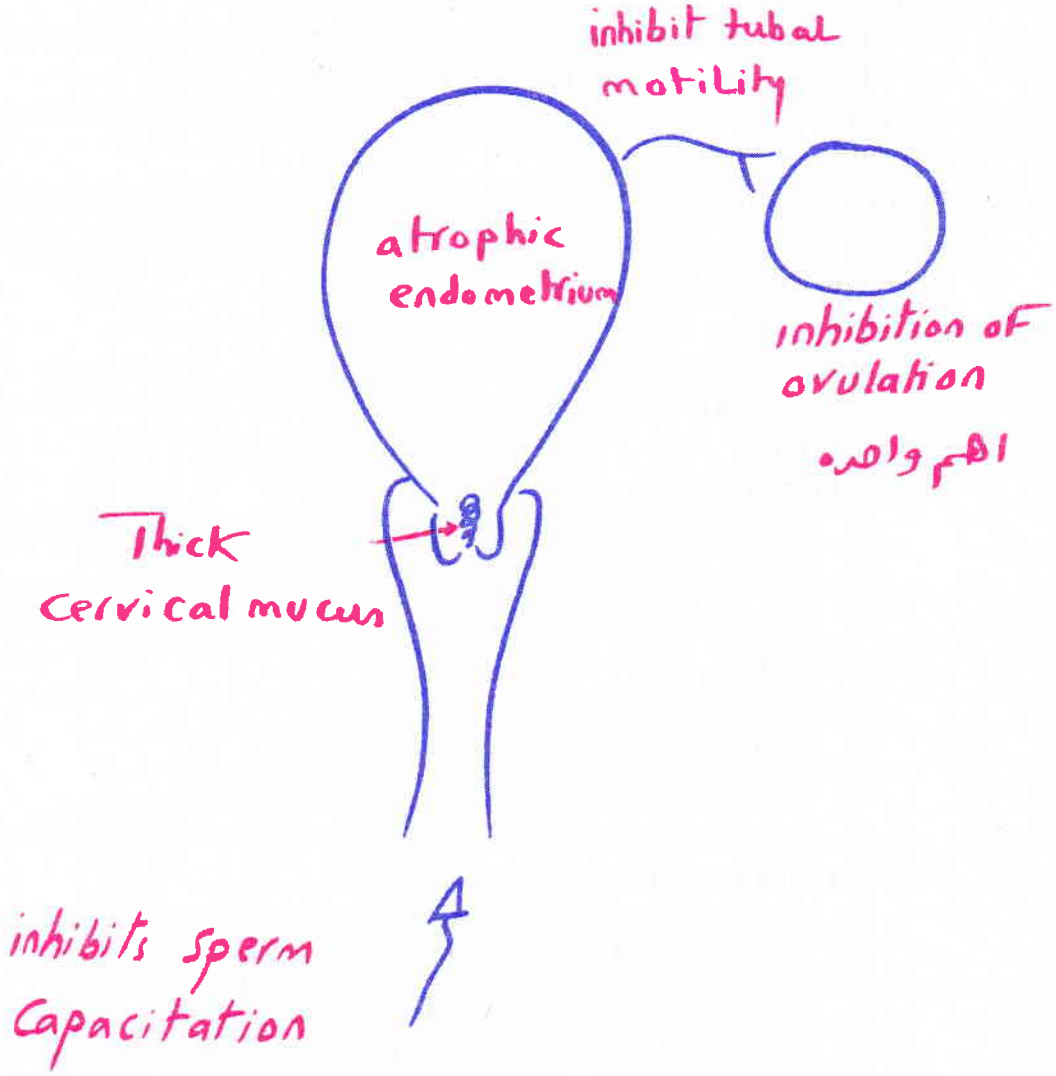

Disadvantages:

- **General**: doesn't prevent against STD, difficult
- **Disadvantages of progesterone + estrogen:-**
  - **Cornea:** change its shape (salt & water retention, important for lens users)
  - **CNS: P: headache, migraine, mood changes (in the 7 days free)**
  - **On CVS:**
    1. **E:** ↑clotting factors → ↑thrombosis
    2. **E+ P: ↑Water & salt retention→HTN & Astherosclerosis**
  - **Breast:**
    1. **E:** ↓milk production, may produce breast cancer (>10 y of use)
    2. **P: engorgement & mastalgia**
  - **Liver:** E: Cholestasis, stones & rarely Hepatic adenoma (1/200,000)
  - **GIT:** E: nausea, vomiting, diabetogenic (E is anti-insulin & lesser degree P), weight gain (salt & water retention, anabolic effect of P)
  - **Skin:**
    1. **E+P:** ↑ pigmentation (chloasma)
    2. **P: acne, hirsutism & alopecia**
  - **Menstrual:**
    1. **Amenorrhea:**
       a. If suspect pregnancy: US/BHCG if --ve restart pills after 7 days
       b. If you don't suspect pregnancy: continue
       c. If persistent after stoppage of pills > 3m = post pill amenorrhea
    2. **Spotting:**
       a. If occasional reassure
       b. If in the 1st half use pills with more E
       c. If in the second half use pills with more P
       d. Also may continue on 2 tab/d for the rest of the cycle
    3. **Breakthrough bleeding:**
       a. Stop the pills for 5 days then restart (+ packup for 14 d)
       b. If in the 1st half use pills with more E
       c. If in the second half use pills with more P
       d. Also may give 2-4 tab/d till bleeding stops then continue on 1 tab/d for the rest of the cycle
  - **Relation of COC to tumors:**
    A. ↑ **Incidence** of cancer cervix, cancer breast & hepatic adenoma.
    B. ↓ Fibroids, endometriosis, CA end/ovary & benign breast conditions.
- **Specific**: require resupply, incorrect use

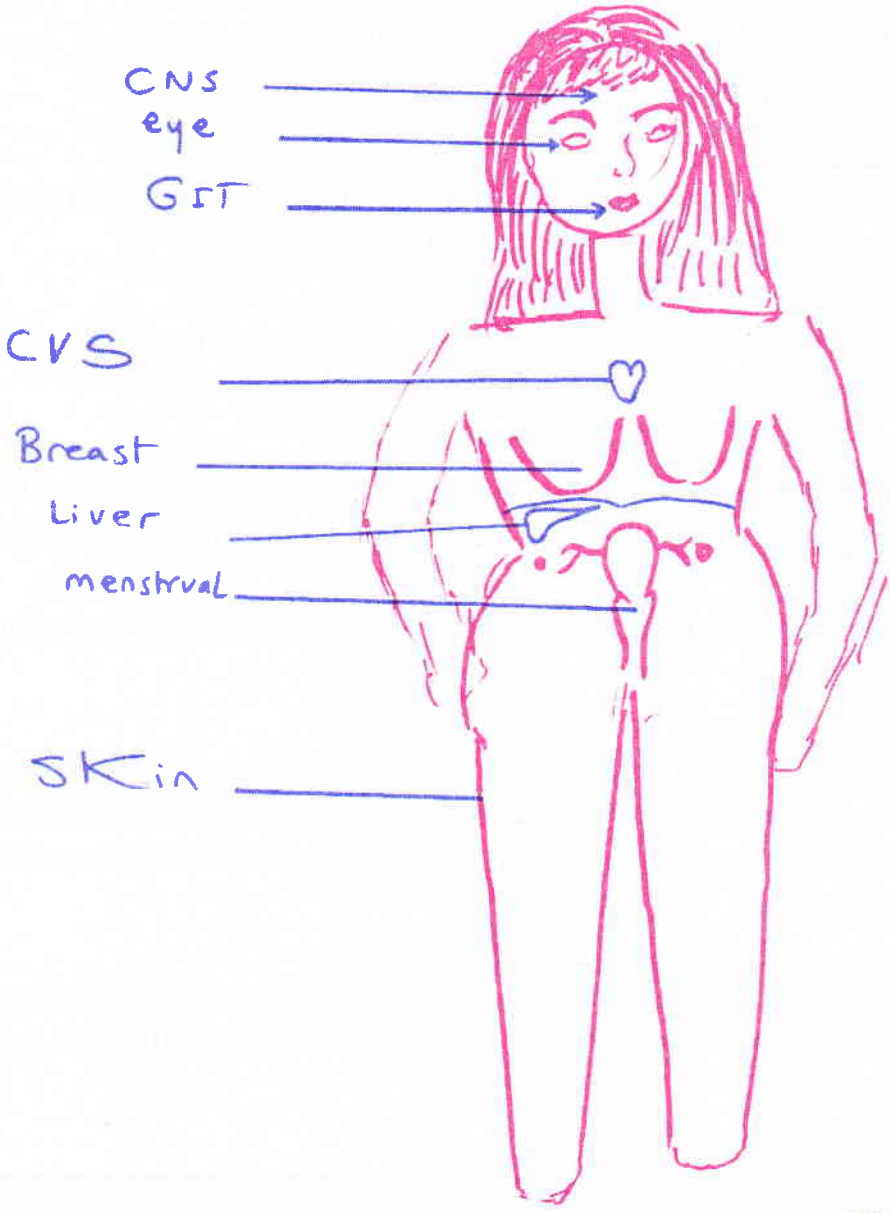

Disadvantages of COC

Danger symptomes (ACHES) اسألني عنها
جديده

Pill administration:

Choice of pills: better to use

1. **Low dose E pills** (less side effects with same potency)
2. **Triphasic pills** (more similar to natural cyclic hormonal changes)
3. **New 3rd generation** containing pills less androgenic side effects

Starting pills

- From 5th day of cycle. Take one tablet for 21 days then stop 7 days → menstruation (expected within 2-3)
- From 1st day of cycle→ better protection.
- Start after 4 w (1 m), after labor if non lactating, 1 w after abortion or EP.
- 28 packs contain 7 days iron.

Missing pills

- **If one pill**: take one as soon as remembered then next pill at its usual time.
- **If 2 pills**: take 2 pills as soon as remembered then take 2 pills at its usual time.
- **If > 2:** stop tabs then restart after 7 d + packup for 14 d or change the method.

Drug interactions

- Sedatives, tranquilizers, anticonvulsant, antibiotics as ampicillin & rifampicin & purgatives decrease the efficacy of the combined pills.
- The pills may reduce the effectiveness of anticonvulsant, hypoglycemia.

Teratogenic effects of the pills

- Progesterone taken during 1st trimester to treat threatened abortion may cause enlargement of the clitoris & fused labia minora in 1-2 % of children.

Contraindications of pills

Absolute	Relative
- **CNS**: Cerebral He, migraine - **CVS**: Coronary disease - **Liver**: • Failure, history of cholestasis during preg. • Acute hepatitis till liver function becomes normal for 6 m • Hepatic adenoma - Known or suspected **breast** cancer - Undiagnosed **vag** hge or amenorrhea (Pregnancy?)	- Epilepsy, headaches starting after use - HTN - Hyperlipidemia - Gall bladder disease - DM, smoking - Age > 35y - Sickle cell disease - Elective surgery - Lactation

Contraindications of pills

Absolute

* 

Relative

* DM



*

* 

* Age > 35 y

اكتب انت الناقص

Progestin only pills (POPS)

Types

- **Noresthisterone:** Micronor (350 µg)
- **Levonorgestrel:** Microlut (30 µg)
- **Lynestrenol:** Exlutone (500 µg)
- Pills are containing very small amount of progestins (minipills)
- POP is used for 35 days, daily at same time. If delayed > 3 h back up for 14 d

Mechanism of action:

1- Thick cervical mucus (most important)
2- Atrophic endometrium
3- Inhibit tubal motility & sperm capacitation
4- Suppression of ovulation (50% بس)

Advantages:

- **ASER** "available, safe, effective (failure rate 1-2%), reversible"
- **No special acts** during sexual acts
- **Can be used in**
  - Lactating
  - ♀ with contraindication of E: liver or CVS, diabetics, hypertensives, smokers, old & obese as no salt & H_2O retention, or androgenic side effects

Disadvantages

- **General:** doesn't prevent against STD, difficult
- **Disadvantages of progesterone only:**
  - Higher failure rate (1-2/ HWY)
  - Menstrual irregularities:
    - Use another type with higher P
    - Don't use E as it interferes with P on cervical mucus & endometrium
  - Ectopic pregnancy
- **Specific:** require resupply, incorrect use

Contraindications:

- Amenorrhea or suspected pregnancy
- Undiagnosed genital bleeding
- Previous ectopic pregnancy

Mechanism of action

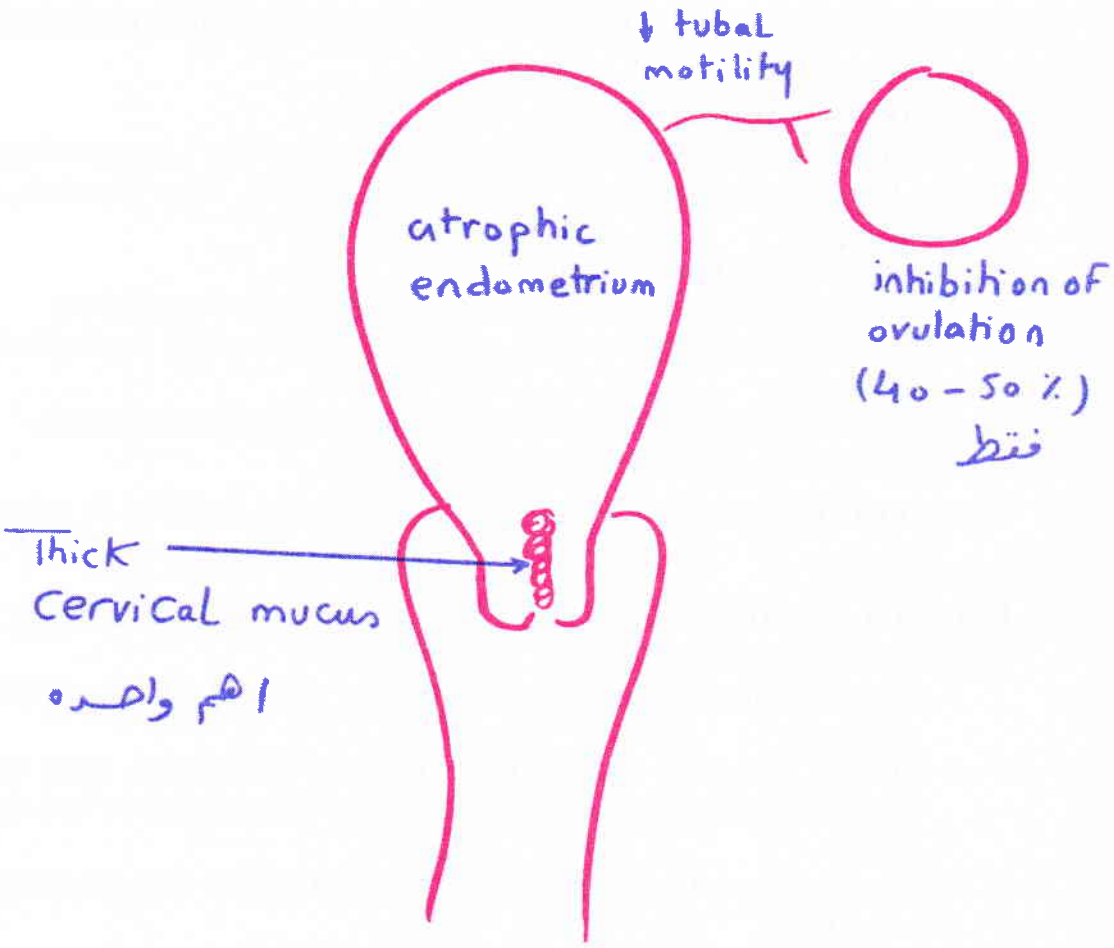

3) Injectables

- **Types:**

Progesterone only

- **Depot medroxy progesterone acetate (DMPA)**: 150mg (Provera) / 3 months
- **Noresthisterone – Enanthate:** 200mg (Noristerat) / 2months

Progesterone + Estrogen

- **Mesgyna**: DMPA 50 mg +5 mg Estradiol valerate / 1 month
- **Cyclofem**: DMPA 25 mg + 5 mg Estradiol cypionate / 1 month

- **Mechanism of action:** as COC (high progesterone can suppress ovulation)
- **Advantages:**
  - **Progestin only Injectables:**
    - ASER "available, safe, effective (99%), reversible", long acting
    - No E side effects, can be given for old, CVS, liver diseases, & lactating ♀
    - No special acts during sexual acts
    - Non contraceptive benefits (due to suppression of ovulation)
      - Endometriosis, precocious puberty, endometrial hyperplasia, carcinoma
      - Hirsutism, improves premenstrual tension & dysmenorrhea
      - Protects against PID (but not STD)
  - **Combined Injectables:** as (P only) but for shorter duration (1 month)
- **Disadvantage**
  - **Progestin only Injectables:**
    - Menstrual irregularities
      - **Amenorrhea, oligo/hypomenorrhea**: exclude pregnancy then reassure
      - **Heavy bleeding or spotting**: exclude pathology, give next injection before date or give combined injectables or low dose COC
    - Once started cant be stopped & return of fertility may be delayed (9 months)
    - Weight gain, no protection against STD
  - **Combined injectables:** as P only + E side effects (headache, breast tenderness)
- **Long term adverse effects & safety of injectables:**
  - **Progestin only injectables:**
    - DMPA doesn't ↑ breast cancer; Small ↑ reported is due to early diagnosis.
    - DMPA may ↓ bone density & could have ↑ risk of osteoporosis later in life
  - **Combined injectables:** P is safe, minimal E side effects.

3) Subdermal Implants

- **Method:**
  - Capsules of Progesterone are inserted under the skin (subdermal) of medial side of the upper arm in a fan shaped manner.
  - **Norplant** (6 cap → 36mg/cylinder) of levonorgestrel for 5 years
  - **Implanon (1** cap of etonogesterol for 3 years)
- **Actions:** as POP
- **Advantages:**
  - ASER " available, safe, effective (99%), reversible☺"
  - No special acts during sexual acts
- **Disadvantages**: as POP, headache
  - Minor surgery (difficult insertion & removal
  - Menstrual irregularities or amenorrhea (the cause of removal)

5-Others

- **LHRH nasal sprays**
- **Vaginal rings**
  - Either combined EE2 + levonorgestrel
    - Inserted 3 weeks & removed one week
    - Failure rate 0.5/ HWY
  - Progesterone only (levonorgestrel)
    - Used monthly or every 3 months
    - Less effective
  - Advantages:
    - Easy use
    - Less side effects (bypass 1st pass metabolism) & immediate reversibility.

General instructions

1- Tablets with low dose E (20, 30, 35 mg) are preferred to decrease side effects.

2- COC is taken daily preferably at night after meals for 21 days starting on 5th day of menses, tablet containing 3rd generation progesterone are started on 1st day.

3- The course is repeated after 1 week, withdrawal bleeding starts 2-3 d after stoppage.

4- If no lactation, give COC 2-3w after labor & immediately (or within 7d of abortion). If vomiting occurred, another pill is taken

5- Contraceptive pills can be used for years without a need to stop them.

Implants

Norplant
- 6 rods → 5 yr
- levonorgestrel

Implanon
- 1 rod → 3 y
- etonogestrel

Immunological methods

N.B. للماجستير

♀
- passive (Antibodies) or Active (Antigens) For Sperms / Zona pellucida / HCG

♂
- Vaccines against sperms

Male Contraception

N.B. للماجستير

Temporary

Non hormonal

- **Natural**
  - Coitus interruptus
  - Coitus inter Femoris
- **Mechanical**
  - Condom
- **Chemical**
  - Gossypol (القطن)
  - ↓
  - (⊖ enzymes in acrosomal cap & mitochondria)
- **Immuno-Logical**
  - Vaccines against sperms

hormonal

- P
- Danazol
- LHRH analogues

Post coital contraception (emergency contraception)

- **Definition:** Contraception after (unprotected intercourse or rape or rupture of condom especially at midcycle)

- **Methods**

  - Hormonal (FR 1-5%):
    - Given immediately or within 72 h (the morning after pill)
    - Larger doses → nausea, vomiting (add antiemetics)
    - Causes luteolysis & alter the endometrium

1. **Estrogens: EE2 (2mg/d for 5d) or premarine (20mg/d for 5d)**
2. **Estrogens/Progestin combinations:** EE 200ug & levonorgestrel 2mg (2 ovral tab then two after 12 h).
3. **POPs: e.g. Postinor (750 μg levonorgestrel) 2 tab.** Repeated after 12 hs
4. **Danazol (600mg & repeat after 12 h) & Mifepristone (600mg once):**

  - Surgical (FR 1%)

1- **Copper IUD:** post coital insertion within 72 h & up to 1 w (more effective)

2- **Post coital douching:** Not effective

3- **Menstrual Extraction:** by Karman cannula short period after the missed period (up to 3 weeks from the missed period)

Special group	Method (barriers & sterilizations can be offered)
Post-partum	LAM, progestin only methods, IUCD
40 years	Progestin only methods, IUCD, COC (low dose with no other risks)
DM	Progestin only methods, IUCD (↑ PID), COC (low dose can be used)
Cardiac	Progestin only methods, IUCD (↑ IEC), COC (avoided)
Newly married	P only methods, COC, IUCD (difficult insertion, ↑PID → avoided)
Lactating	Progestin only methods, IUCD, COC (avoided)

INFECTIONS

INFECTIONS

Natural barrier against infection

- **Vulva:** apposition of labia
- **Vagina**
  - Acidic pH
  - Str. Squamous epithelium
  - Absent glands
  - Apposition of its anterior & posterior wall
- **Cervix:** mucous → bactericidal
- **Uterus:** menstruation
- **Fallopian tubes:** ciliary movement towards the uterine cavity

Factors affecting efficiency of the natural barrier

1- General	2-Before puberty &after menopause
a. General ill health b. Chronic diseases c. Malnutrition d. Immunosuppressive drugs	a. Thin vaginal epithelium b. Decrease vaginal acidity PH (6-7) c. Absence of cyclic shedding of endometrium
3- During menstruation	**4-During puerperium**
a. No cervical mucus plug. b. Acidity is neutralized by the menstrual discharge.	a. The cervix is dilated b. Vaginal acidity is neutralized by the lochia c. Lacerations d. Placental site & clots (medium for infection).
After any instruments e.g sounding, IUCD, insufflation, D&C.	

Normal vaginal discharge

- ↑normal discharge = leucorrhea (may be used to indicate all abnormal vaginal discharge other than blood)
- **Causes of leucorrhea:**

  I. **Increased hormones (estrogen):**
     a) Puberty
     b) Premenstrual & midcyclic
     c) Pregnancy & puerperium (Lochia alba)

  II. **Pelvic congestion:** constipation, coitus interruptus, anorgasmia, pelvic diseases.

◈ Source of normal vaginal discharge:

	PH	Source
Vulva	Alkaline	Bartholin glands
Vagina	Acidic (4)	Serous transudation
Cervix	Alkaline (8.5)	Endocervical glands (cyclic ↑ by E)
Uterus	Alkaline	Endometrial glands (especially secretory phase)
Tubes	Alkaline	Goblet cells

◈ Normal vaginal flora

◈ Cocci			
Aerobes		Anaerobes	
G+ve	G-ve	G+ve	G-ve
- Staphylococcus - Streptococcus	- Non gonococcal neisseria - Pneumococci	- Peptococci - Peptostrept	- Vionella

◈ Bacilli			
Aerobes		Anaerobes	
G+ve	G-ve	G+ve	G-ve
- Diphtheroids - **Doderleins** (commonest)	- E.coli - Klebsiella	- CL	- Bacteroids: Fragilis, Bivins & Disens

◈ Others:

- ⇨ **Gardnerella. vaginalis: aerobic gram -ve coccobacilli**
- ⇨ **Candida albicans: gm +ve yeast like fungi**

Trichomonas isn't part of normal flora (MCQ)

◈ Causes of abnormal vaginal discharge:

	Vulva & vagina	Cervix	Uterus	Tubo-ovarian
Trauma	FB, pessary	ulcers	IUCD	Ligation
Infections				
Tumors: infected benign or malignant				
Miscellaneous	fistula	Ectopy	Fistula ROM, VM	Intermittent hydrosalpinx

Infections

Organs

Upper genital tract infections

- endometritis
- pyometra
- parametritis
- PID
- pelvic abscess

Lower Genital tract infections

- vulvo vaginitis
- Bartholinitis
- cervicitis

Organisms

STD

- Bact
  - gonorrhea
  - B. vaginosis
- Chlamydia
- Fungi: Candida
- protozoa: TV
- viruses:
  - HPV
  - HSV

Chronic granulomatous diseases

- Bilharziasis
- Syphilis
- TB

VULVO-VAGINITIS مهمه جدا

- **Classified into**
  - **Primary 1ry**
    - **Bacteria**: Gonorrhea, Syphilis, TB, **bacterial vaginosis (commonest)**
    - **Chlamydia:** lymphogranuloma venerium (LGV)
    - **Viruses:** HSV, CMV, HPV (condyloma accuminata)
    - **Fungal:** candidiasis
    - **Parasites:** Trichomonas vaginalis, Bilhariziasis, Scabies, Pediculosis, Oxyuris
  - **Secondary 2ry**
    - **Cervical& vaginal discharge**
    - **Urinary conditions:** incontinence, fistula, glucosuria, pyuria
    - **Rectal conditions:** Recto-vaginal fistula, complete perineal tear
    - **Chemical:** douches, sprays, perfumes
    - **Physical**: scratching, irradiation
    - **Traumatic**: foreign body, prolapse, neglected pessary

- **Vulvovaginitis in different age groups**

1- Prepubertal vulvovaginitis

- **Predisposing factors:** Thin vaginal mucosa +↓ E → ↑ PH →↑ infection
- **Causes:**
  - **Vulvovaginitis in infants**
    - **Congenital:** as fistula
    - Diaper rash
    - Infection from the birth canal
  - **Vulvovaginitis in children (commonest gynecological complaint)**
    - **Congenital:** fistula
    - **Trauma:** sexual assault, foreign body (commonest cause)
    - **Infections:** sexual abuse (STD), parasites (oxyuris, amoebiasis)
    - **Tumors:** sarcoma botryoids
    - **Poor hygiene:** wiping must be from front to back.
- **Symptoms:**
  - **Pain:** dysuria, soreness
  - **Discharge**
  - **History of the cause:** trauma, perianal erythema (parasites)

- **Signs:**
  - **Complete physical Ex**
  - **Pelvic Ex:** redness, edema, discharge
- **Investigations:**
  - **Smear:** gram staining
  - **Culture** for the discharge
  - **Foreign body:** PR, US, Xray, vaginoscopy (cystoscopy or nasal speculum)
- **Treatment:**
  1- Treatment of the cause
  2- If persistent or serosanginous look for a FB.
  3- Ice packs, sitz paths, topical CS & Oral antibiotics
  4- Lactic acid ± **HRT**

2- Senile vulvovaginitis

- **Predisposing factors:** Thin vaginal mucosa + ↓ E → ↑ PH → ↑ infection
- **Causes**
  - Candida rarely occur except (Glabrata) with HRT
  - BV is less common except in women confined to bed
- **Symptoms:**
  - **Pain** : dysuria, soreness
  - **Discharge**, **History of the cause**
  - **History of infection of ♂** + dyspareunia
- **Signs:**
  - **Complete physical Ex**
  - **Pelvic Ex:** redness, edema, discharge
- **Investigations:**
  - **Smear:** PAP smear, gram staining
  - **Culture** for the discharge
  - **Suspicious lesions**: biopsy
- **Treatment of the cause**
  1- Ice packs, sitz paths, topical corticosteroids & oral antibiotics
  2- Exclude malignancy + Lactic acid ± **HRT:** E (+ P if the uterus is present) daily or every 2 days for a month then twice weekly

3- Vulvovaginitis during childbearing period

A- Candida albicans (monilia, thrush):

- **Causes:**
  - **Organism**: Fungus **candida albicans (others c. tropicalis, c. krusei)**
  - **Mode of transmission**: from hands, towels, coitus, instruments
  - **Predisposing factors**: pills, pregnancy, DM, corticosteroids, antibiotics, AIDS
- **Incidence**
  - 30-35% of vulvo-vaginitis
  - 15-20% non pregnant
  - 20 - 40% pregnant women (↓ PH & ↑glycogen)
- **Symptoms**:
  - Discharge:
    - Thick (curd like) white, semisolid, soapy & odorless.
    - Usually premenstrual (↑ glycogen)
    - Increased glycogen & relieved by menses due to ↓ acidity
  - Itching, dysparunia & Infection of the ♂
- **Examination**:
  - Inflamed vulva: red, excoriated edema
  - Vaginitis may preclude the passage of the speculum
  - White patches: removal leaves slight bleeding, affection of crural folds
- **Investigations**:
  - **PH** < 4.5 (acidic ☺)
  - **LM:** fresh wet drop +10% KOH → hyphea
  - **Gram stain:** no pus cells, Doderlein bacilli are present
  - **Cultures:** Nickerson's or Sabouraud's (especially in recurrent cases to know the type & specific antifungal)
  - **Antigen detection:** microstix
- **Treatment**:
  1. Treatment of the predisposing factors + alkaline vag. douches (better avoided)
  2. Drugs:
     - **local: cream or pessary**
       - ☆ Mycostatin (Nystatin) 1x1x14
       - ☆ Clotrimazole (Canesten) 100mg 1x1x6
       - ☆ Miconazole (Daktarin)400mg1x1x3

- **Oral:** for virgins, recurrent, systemic infections not in pregnants or lactation
  - ☆ Ketoconazole (Nizoral) 200mg2x1x5
  - ☆ Fluconazole (Diflucan) 150mgonce
  - ☆ Itraconazole (Sporanox)1gm once
- **In case of recurrence:**
  - ☆ Treat the predisposing factors (e.g. DM)
  - ☆ Treat the husband
  - ☆ Avoid vaginal douches
  - ☆ Oral therapy + extend the treatment for 3 -- 6 weeks.

B- Trichomonas vaginalis:

- **Causes:**
  - **Organism**: Protozoal infection
    - ☆ Ovoid in shape larger than WBCs
    - ☆ Has 4 anterior flagella, undulant membrane, a long tail
  - **Mode of transmission**:
    - ☆ From hands, towels, coitus, instruments
    - ☆ Lives in swimming pools for 24 hrs
  - **Predisposing factors**: ↓ immunity, ↓ acidity, Antibiotic therapy, OCP
- **Incidence**: 5 -10% of vaginal infection
- **Symptoms**:
  - Discharge:
    - Start postmenstrual (↓ PH)
    - Profuse Greenish
    - Fishy odor, frothy
  - Itching, dyspareunia & Infection of the ♂
- **Examination**:
  - Red (strawberry/ angry) vagina, petechial hemorrhages (flea bitten vagina)
  - Greenish discharge, Cx is red
- **Investigations**:
  - **pH** > 5 (alkaline)
  - **Wet preparation**: pyriform motile
  - **Pap smear**: gram -ve,
  - **WBCS**, ↓↓ lactobacilli
  - **Culture**: Feinberg, Staurt`s, Diamond medium, Trichocele nutrient agar
  - **Colposcopy:** T shaped blood vessels on the cervix.

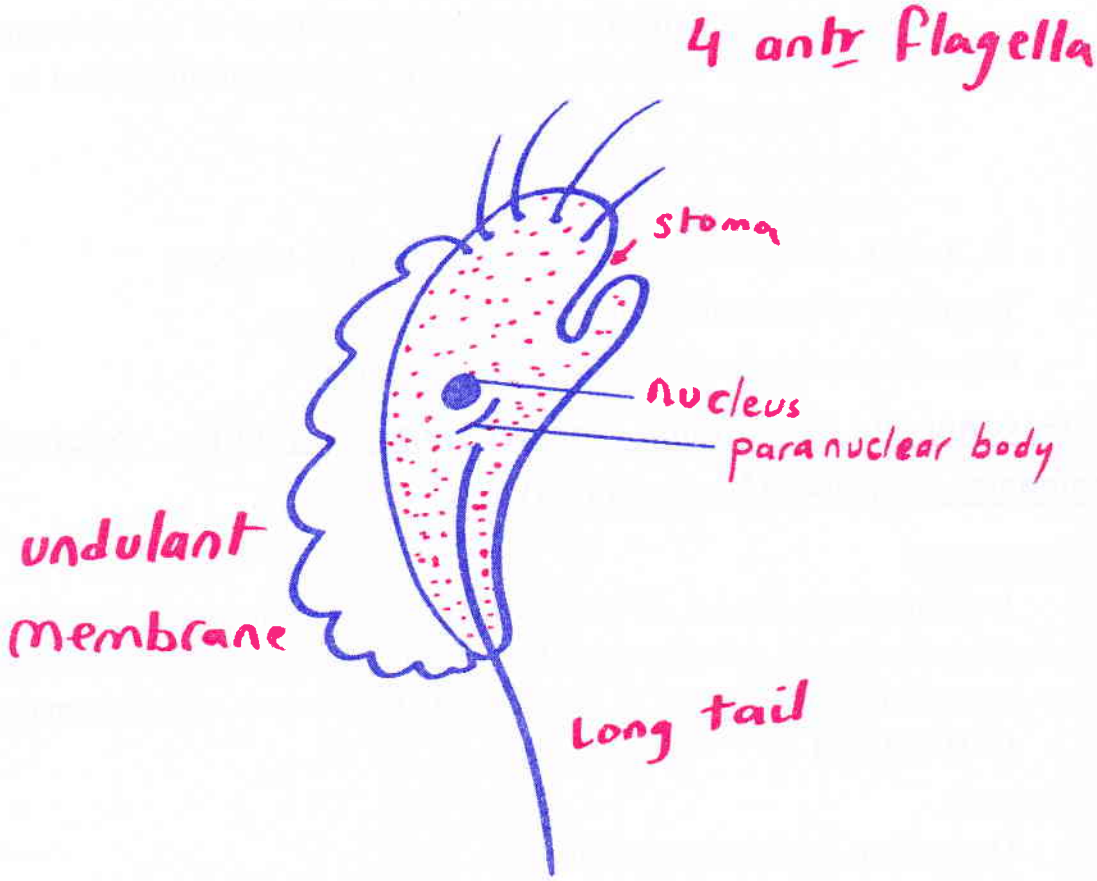

Trichomonas vaginalis
(Slanting eye app.
Mongolian eye app.)

- **Treatment**:
  - Treatment of the predisposing factors + acidic vag. douches (better avoided)
  - **Drugs**:
    - ☆ **Oral**
      - Metronidazole500mg 1x2x7
        - ⇨ **Adverse effects:** Nausea & vomiting is more common with the single dose, metallic taste, contraindicated in 1st trimester.
      - Tenidazole (2 g once) 4 tabs
      - Ornidazole (1.5 g once) 3 tabs
    - ☆ **Local**: metronidazole vaginal tabs (500 mg 1X1X10)
  - Treatment of husband, avoid coitus during therapy
  - In resistant cases, treat the predisposing factors

C- Gardnerella vaginalis (hemophilus vaginalis, bacterial vaginosis, non specific vaginitis):

- **Definition**:
  - It means replacement of normal vaginal flora (Doderlein bacilli) by other bacterial colonies mainly G.vaginalis, mycoplasma hominis, ureaplasma urealyticum & anerobes **in the absence of inflammation (osis not itis)**
- **Causes:**
  - **Organism**: Bacterial infection,
    - ☆ **Bacteroids, Peptostreptococci, mycoplasma, ureaplasma.**
    - ☆ **Gardnerella** (↑10 folds): vaginalis & mobilancus
  - **Mode of transmission**: From hands, towels, coitus, instruments
  - **Predisposing factors**: ↓ immunity, ↓ acidity (↓ lactobacilli), STD, IUD, Pills, uncleaniness.
- **Incidence**: 10 -25% population, 60% of vulvovaginitis☺
- **Symptoms**:
  - NO symptoms in 50%
  - Discharge دي المشكله الوحيده:
    - ✱ Excessive, grayish, no pus cells
    - ✱ Fishy odor due to formation of amines from amino acids by anerobes
    - ✱ Especially apparent after intercourse or menstruation

- **Complications**:
  - **Non-pregnant**: PID,UTI, wound infection after operations as vaginal cuff after hysterectomy
  - **Pregnant**: PROM, chorioamnionitis preterm labor.
  - **However**, there is no consensus اتفاق on prophylaxis
- **Examination**: Minimal inflammation (vaginosis not vaginitis)
- **Investigations (3criteria diagnose BV):**
  - **pH** > 4.5
  - **Whiff** نفس- هبو **test**: Fresh + KOH → fishy odor
  - **Clue cells:** obscured cell margins of vag epithelial cells (stippling) due to heavy organisms, demonstrated by:
    - **Fresh wet drop:** drop of saline + drop of vaginal discharge
    - **Gram stain:** gram –ve coccobacilli (hemophilus vaginalis)
  - Gray homogenous discharge no WBC's unless → gonorrhea, Chlamydia
- **Treatment**:
  - **Treatment of the predisposing factors**
  - **Acidic vaginal douches** (better avoided)
  - **Drugs**:
    1- Metronidazole 250 mg 1x3x7 or local gel
    2- Clindamycin 300mg 1x2x7 or local cream 2% 1x7 (↓ efficacy of condoms → pregnancy☺)
    3- Broad spectrum as ampicillin, tetracycline (500mg 1x4x7)
  - **Treatment of husband** is not recommended, avoid coitus during therapy
  - **In resistant cases**, treat the predisposing factors

Clue Cell



vaginal epithelium

Covered by The organisms

Bartholinitis & abscess	Bartholin cyst
▪ The gland is one of the 3 derivatives of the **pelvic part of the urogenital sinus** ▪ It is a racemose gland, lies on either side of **vaginal opening** between **perineal membrane** & vestibular **bulb** ▪ Each gland has a long duct 2cm that opens between the hymen & the labia majora.	
Causes	
• **Gonococci** • **Other** E.coli, proteus • **Mixed**	• **Obstruction** of the gland (columnar lining) or duct (transitional lining & more common) by infection, mucous, suturing in episiotomy. 1. **Congenital**: duct atresia or stenosis. 2. **Traumatic**: circumcision &lateral episiotomy .....Healing by fibrosis. 3. **chronic infection** ....fibrosis (commonest is Gonorrhea, next staph) 4. **Vascular**: edema of the tissues surrounding the duct e.g in pregnancy. 5. **Tumors** or hyperplasia of the epithelial lining of the duct
Clinical picture	
Symptoms	• **Pain**: - local & may impair walking - Dyspareunia - Throbbing pain in abscess • **Discharge**: if drained abscess
	• **Painless** swelling in the vulva • **It is the commonest vulval cyst**
Signs	• Tender swelling in labia • Skin is red edematous • Induration of the gland
	• Cystic non tender swelling in the posterior 1/3 of the labia majora
Complications abscess or cyst formation or chronic Bartholinitis (very common)	
Treatment	• **Antibiotics + hot foments** • **If abscess** → drain • **Helton's incision** in a Bartholin abscess to be followed later by marsupilization
	• **Excision**: if postmenopausal for fear of cancer • **Word catheter**: self retaining catheter with balloon) through a small incision for 2-3 weeks. • **Marsupilization:** do an elliptical incision & suture the edges to the surrounding. Easy and ↓ bleeding + Preserve the gland function



Bartholin
abscess
bulging in
The vagina

marsupilization لعمل
vag. مساحيه

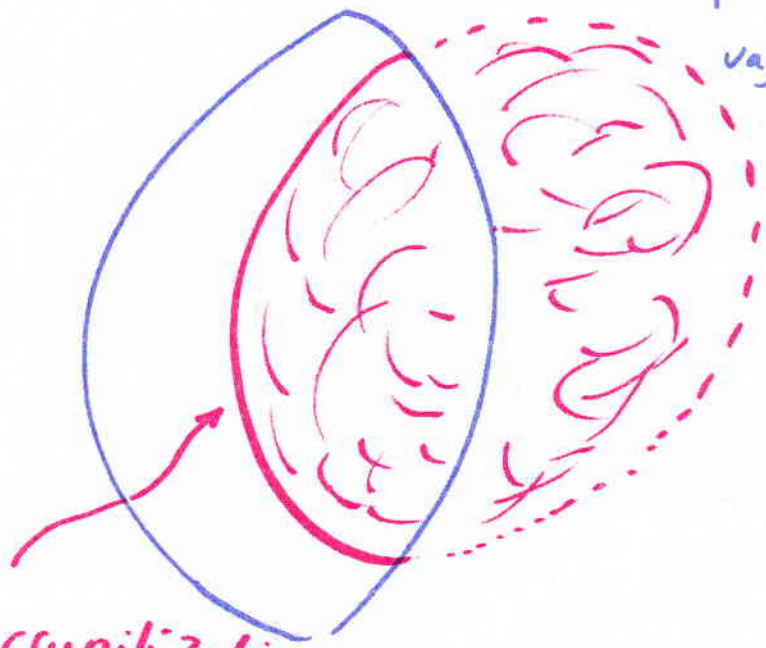

Marsupilization
= Deroofing

Cervicitis

Acute cervicitis

- **Organism:**
  - **Non specific:** as streptococci, staph, E coli, proteus
  - **Specific:** Gonococci, Chlamydia, monilia, trichomonas, viruses.

- **Route:**
  - **Obstetrics**: Following labor or abortion
  - **Gynecologic**: after D&C, cervical cauterization or loop application

- **Symptoms:**
  - **General**: FAHMR
  - **Local:**
    - **Contact bleeding**
    - **Pain:** backache, dyspareunia
    - **Discharge:** purulent

- **Signs:** **the** cervix is red exuding mucopurulent discharge & bleeds on touch

- **Investigations:**
  - **Cervical smear**
  - **Cervical culture**

- **Treatment:** Antibiotic (7-10 days) & antiseptic pessaries

Chronic cervicitis

- **Organism:**
  - **As acute (non specific & specific)** + Chronic granulomatous (TB, Bilhariziasis, actinomycosis)
  - **Commonest** genital infection & many of them are asymptomatic

- **Predisposing factor:**
  - **Follows** untreated acute
  - **Causes of chronicity:**
    1. Endocervical glands are **racemose** with difficult drainage
    2. No monthly shedding
    3. Deep location of the glands so difficult delivery of the antibiotics
  - **Mild** infection from the start: post (operative, abortive or partum)

Pathological types of chronic cervicitis:

- **Chronic endocervicitis**: normal cervix exuding mucopurulent discharge.
- **Mucus polyp**: hyperplasia of the endocervical epithelium: multiple small reddish polyps.
- **Chronic hypertrophic cervicitis**: swelling & hyperemia of cervix
- **Chronic atrophic cervicitis**: cervical stenosis
- **Nabothian follicle**: obstruction of the endocervical glands leads to multiple small retention cysts either bluish (full of mucus) or yellowish (full of pus).
- **Cervical erosion**: bright red areas (true ulcers).
- **Ectropion**: eversion of endocervical mucosa (due to bilateral cervical

Symptoms: (congestive الاعراض):

- Mostly **asymptomatic** & it affects many women
- **Pain (4D)**
  - **D**yspareunia, **d**ysmenorrhea (congestive)
  - **D**orsal pain (backache مميز جدا) due to affection of uterosacral ligament
  - **D**eep lower abdominal pain due to affection of parametrium
- **Contact bleeding**
- **Discharge** mucoid, purulent
- **Other complications:**
  - **Infertility** (hostile cx mucus), malignancy (HPV)
  - **During pregnancy:** PROM, abortion
  - **Spread** : locally & acts as a septic focus
  -

Signs:

- **Tenderness** on movement (jumping sign)
- **MP** discharge
- **Nabothian** follicles

Investigations:

- **Blood tests:** leucocytosis, ↑ ESR
- **Colposcopy**: exclude malignancy, evaluate pathological changes.
- **Cervical** smears & cultures for gonorrhea, chlamydia & exclude malignancy
- **Infertility**: post coital test

D.D of chronic cervicitis

- Causes of cervicitis.
- Causes of leucorrhea.
- Causes of contact bleeding
  - **Definition**: bleeding after
    - Coitus: Postcoital
    - PV
    - Douching
  - **Causes**:
    - Cervical inflammations or cancer
    - Vaginal inflammation & tumors
    - Uterine tumor bulging into vagina.
    - Investigations: smear & colposcopy → specific management.
- Causes of cervical ectopy.

Treatment

- **Prophylaxis**:
  - Avoid sexual promiscuity
  - Aseptic techniques (delivery, D&C, IUCD),
  - Prompt diagnosis & early treatment of acute cervicitis
- **Medical**:
  - Warm vaginal douches,
  - Antibiotic (2-3 m)
  - Antiseptic pessaries e.g. albothyl
- **Cauterization**: electrocautery, cryocautery, chemical, laser
  - **Mechanism**: open & drain deep infected glands, coagulate epithelium of cervical canal, slough separate at 10th day & epithelium regenerate. Avoid 3, 9 O`clock (avoid injury of descending cervical artery)
  - **Types**:
    - **Electrocautery**: coagulate unhealthy tissue + opens deep glands.
    - **Cryocautery**: by CO_2 or N_2 at -60°C for 2 – 4 minutes
      - ⇨ **Disadvantages**: profuse watery discharge (very common)
    - **Chemical cautery**: silver nitrate, $ZnCl_2$ using Fergusson speculum
    - **Laser therapy**: rapid healing, minimal fibrosis & less side effects
- **Surgery**:
  - Conization
  - Amputation
  - Rarely hysterectomy if extensive infection or there is coexisting disease
- **Exclusion of malignancy and treatment of complications**

Cervical ectopy

- **Definition:**
  - The stratified squamous epithelium of the ectocervix is replaced by columnar epithelium → red area (previously called erosion)

- **Causes:**
  - **Congenital**: ↑E → columnar ep. proliferation
  - **Hormonal** (OCP, preg):↑ E
  - **Inflammatory**: infection → destruction of stratified squamous epithelium, the area covered by columnar epithelium, it may be then covered by stratified squamous epithelium → formation of retention cyst → **Nabothian follicle**

- **Types☺:**
  1- **Simple** : smooth surface
  2- **Papillary**: with folds→ contact bleeding
  3- **Follicular**: crypts, cysts, follicles, lymphatic aggregation

- **Symptoms:**
  - As **chronic cervicitis** (discharge is mucoid)
  - It may be **asymptomatic**
  - **Contact bleeding**

- **Signs (by speculum examination):**
  - **Simple erosion (flat)**: Bright red area is seen around external surface
  - **Papillary erosion** ...velvety appearance
  - **Follicular** ...blue or yellow
  - **Differential diagnosis**: CIN

- **Investigations:**
  - As in chronic cervicitis.
  - **Smear, colposcopy & biopsy** to differentiate from malignancy

- **Treatment:**
  - **Asymptomatic or during pregnancy**: no Treatment☺ مهمه جدا جدا.
  - **Treatment of the cause** e.g. infection or change pills type.
  - **Exclusion of malignancy**.
  - **Local destruction**: cauterization (electro, cryo, chemical & Laser)

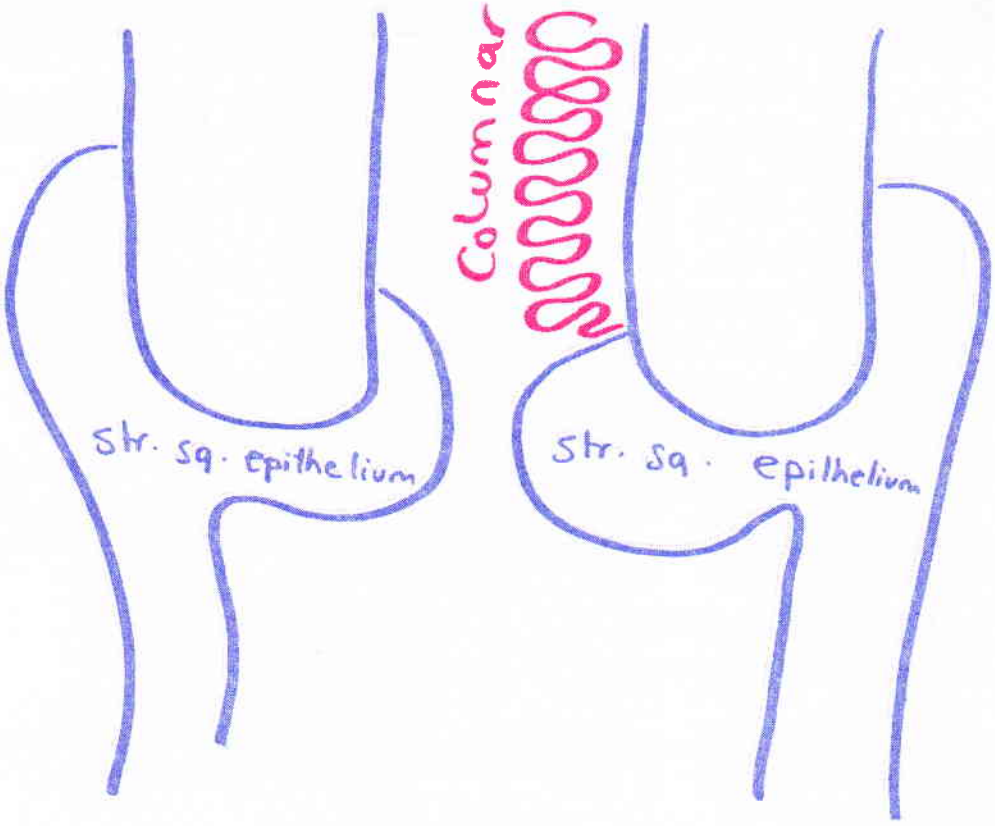

↑E or trauma

Ectopy

UPPER GENITAL TRACT INFECTION

	1- Pyometra	2- Acute endometritis	3- Chronic endometritis
Definition	• Retention of pus in uterine cavity. • **Acute**: Infection of retained products of conception • **Chronic**: CA endocx or endom, infected hematometra. (any case of chronic pyomtra is considered malignant till proved otherwise)	• Gonococci, Chlamydia. • **Other**: - E-coli, - Proteus postoperative & postpartum	• **Specific** - TB, Chlamydia. • **Non-specific:** - E-coli, proteus - Senile endometritis (no shedding)
Clinical picture	• **G**: FAHM. • **Abd**: abd pain, mass • **PV**: intermittent purulent discharge.	• **Pain**: local • **Discharge**: purulent. • **Microscopy**: - Lymphocytic infiltration	
TTT	• Antibiotics. • Ergometrin • D&C (drain & exclude tumors) • Hysterectomy.	1- Treatment of the cause 2- D&C. 3- If failed hysterectomy. 4- HRT in senile type	

4- Parametritis

- **Inflammation of the parametrium on one side or both side due to:**
  - Inflammation of cervix or vagina, infected LSCS.
  - Hysterectomy, infected intraligamentary hematoma
- **Symptoms:** FAHM + abd & back pain
- **Signs:**
  - **G**: toxemia.
  - **Abd**: pelvi-abd mass.
  - **PV**: fornices are obliterated.
    - Unilateral: pushes cervix to one side.
    - Bilateral: uterus within the mass, vulvar edema
- **Treatment:**
  - **Drainage**
  - **Treatment of complications:** extension to external inguinal ring, thighs, perinephric region, bladder or rectum.

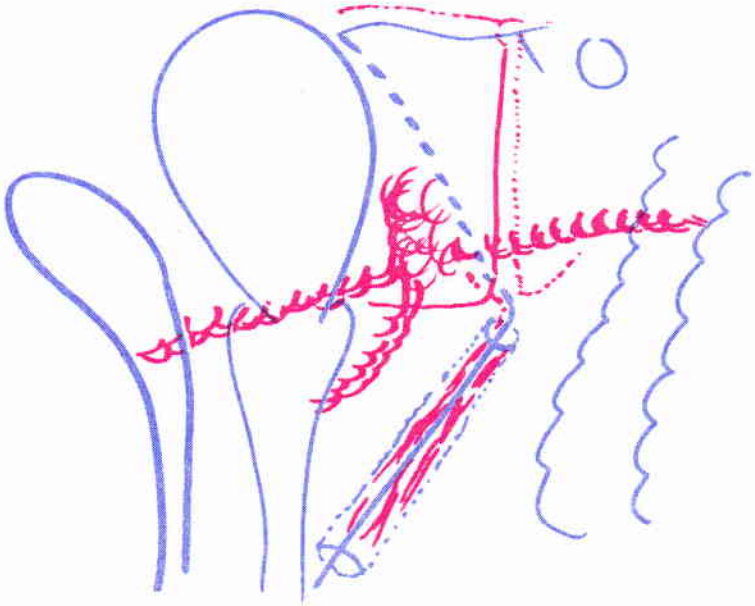

Sites of spread of parametric abscess (vag, bl, Rectum, inguinal region)

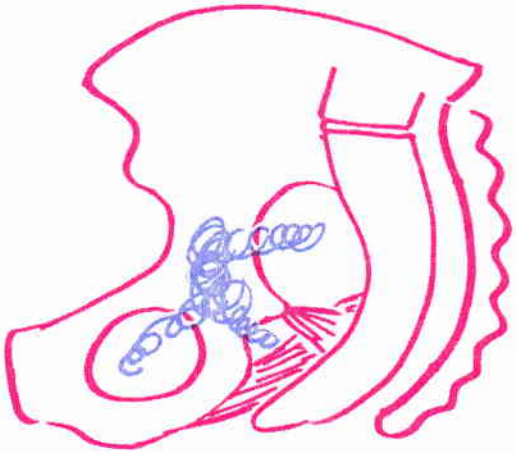

شبابيك Spread of parametric abscess through sciatic foramina to buttocks & obturator foramen to the thigh.

5- Pelvic abscess

- **Definition**: Abscess in Douglas pouch
- **Causes**:
  - **1ry**: not preceded by pregnancy, trauma, or surgery → better prognosis
  - **2ry**:
    - Post operative, postabortive, postpartum, post-ectopic (infected hematocele)
    - Extension from a nearby septic focus: appendicitis, diverticulitis.
  - **Usually** mixed organisms 1st aerobes then anerobes
- **History**
  - FAHM
  - Pain is more severe
  - 4Ds (urinary & rectal pressure symptoms)
- **Signs:**
  - **G**: Fever, rigors, tachycardia
  - **Abd**: cystic mass.
  - **Vag**: tender cystic swelling in DP.
  - **PR**: tender cystic swelling in DP
- **Investigations:**
  - ↑ ESR, TLC, CRP
  - U/S, Proctoscopy.
- **Treatment:**
  - **Prophylactic**: prevent puerperal, postabortive & surgical infection
  - **Active**:
    - **PID with no masses**:
      - Medical treatment for 48 hours initially, rest, fluids, Fowler position, antibiotics
        - If good response: continue
        - If no response or there is a mass (abscess) from the start: surgery
          - Conservative: unilateral adenexectomy or drainage.
          - Radical ....TAH + BSO if > 40 years.

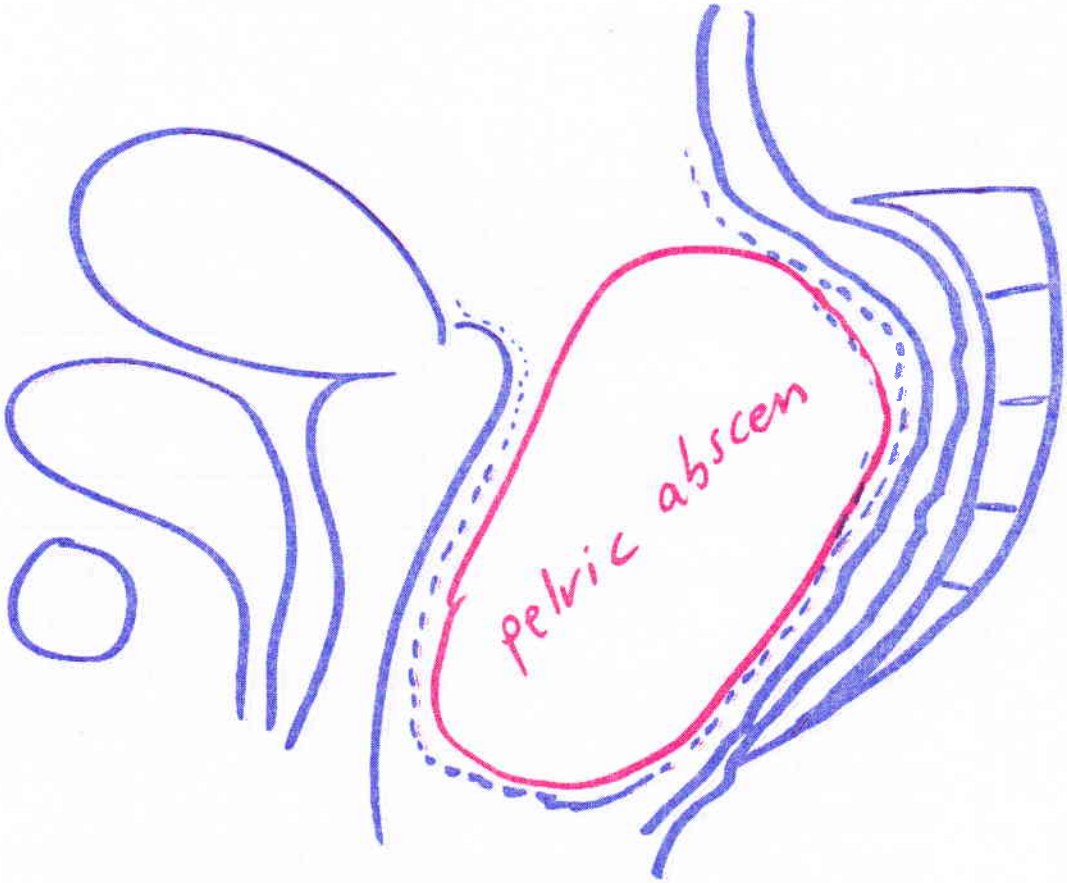

اوعى تنسى

4D's

6- Pelvic inflammatory disease اهم درس

- **Definition:**
  - Infection of the genital tract above the cervix (upper genital tract; uterus, tubes, ovaries & pelvic peritoneum)
- **Incidence**: 2 – 3 % of females
- **Etiology:**
  - **Organism:**
    - **Pyogenic organisms infection is usually mixed**
    - STD especially N. Gonorrhea (40 %) & Chlamydia (60 – 70%)

	N.gonorrhea	C.trachomatis
Onset	More acute Usually after menses	May remain silent for months
C/P	Acute pain +/- peritonitis	Milder
Comp	Diffuse exudate → tubal block	More damage but later on

    - Chronic granulomatous: TB, bilhariziasis
  - **Route:**
    - **Ascending** (endosalpinigitis) **as in gonorrhea & chlamydia**
    - **Lymphatic** (interstitial salpingitis) as in postabortive & puerperal.
    - **Blood** (all layers) as TB
    - **Direct** (perisalpingitis) **from a nearby septic focus as appendicitis.**
  - **Risk factors:**
    - **Promiscuity**
    - **Previous** PID, IUD insertion
    - **Recent** instrumentation "post abortive, HSG"
    - **Ascending** from lower genital tract infection
    - Young (<35y), non white race, low socioeconomic class
- **Types:**
  - **Acute**
  - **Chronic:**
    - Persistence or poor treatment of acute attacks
    - Chronic from the start
  - **Acute attacks on top of chronic PID**

Epidemiology كتاب القسم

- **It is disease of:**
  1. Sexually active woman
  2. Menstruating woman, as the blood is good medium for organism and a blood dislodge cx mucous which help ascending infection
  3. IUD users as the threads help ascending infection
  4. Females using douches especially around their menses as pressure at the cx mucous may facilitate the transport of infection

- **PID is rare in:**
  1. Pregnancy as gestational sac prevents ascending infection & increase blood flow during pregnancy help to wash the organism
  2. Female using barriers
  3. Female using COCS or progesterone → alter the cx mucous and endometrium and thus retarding the ascending infection
  4. Patient with tubal ligation

- **(Center for disease control) major criteria for diagnosis of acute PID:**
  1) Lower abdominal pain & tenderness of lower abdomen
  2) Cervical motion tenderness
  3) Adenxal tenderness

- **Minor criteria to diagnose PID:**
  1. Fever >38 °c
  2. Leucocytosis >10.500/cc
  3. Adenxal mass on pelvic examination or U/S
  4. Purulent material on culdocentesis
  5. Gram –ve intracellular dioplococci for the discharge

For diagnosing PID: the 3 major + 1 minor

- **Gainesville staging of PID** مهمه
  - **Stage 1**: endometritis – salpingo-oophoritis
  - **Stage 2**: TO cyst
  - **Stage 3**: TO abscess
  - **Stage 4**: ruptured TO abscess
  - **Stage 5**: lung spread

PID & contraception تجنبه

- IUCD
- Barriers
- COC , P
- tubal Ligation

Gainesville staging

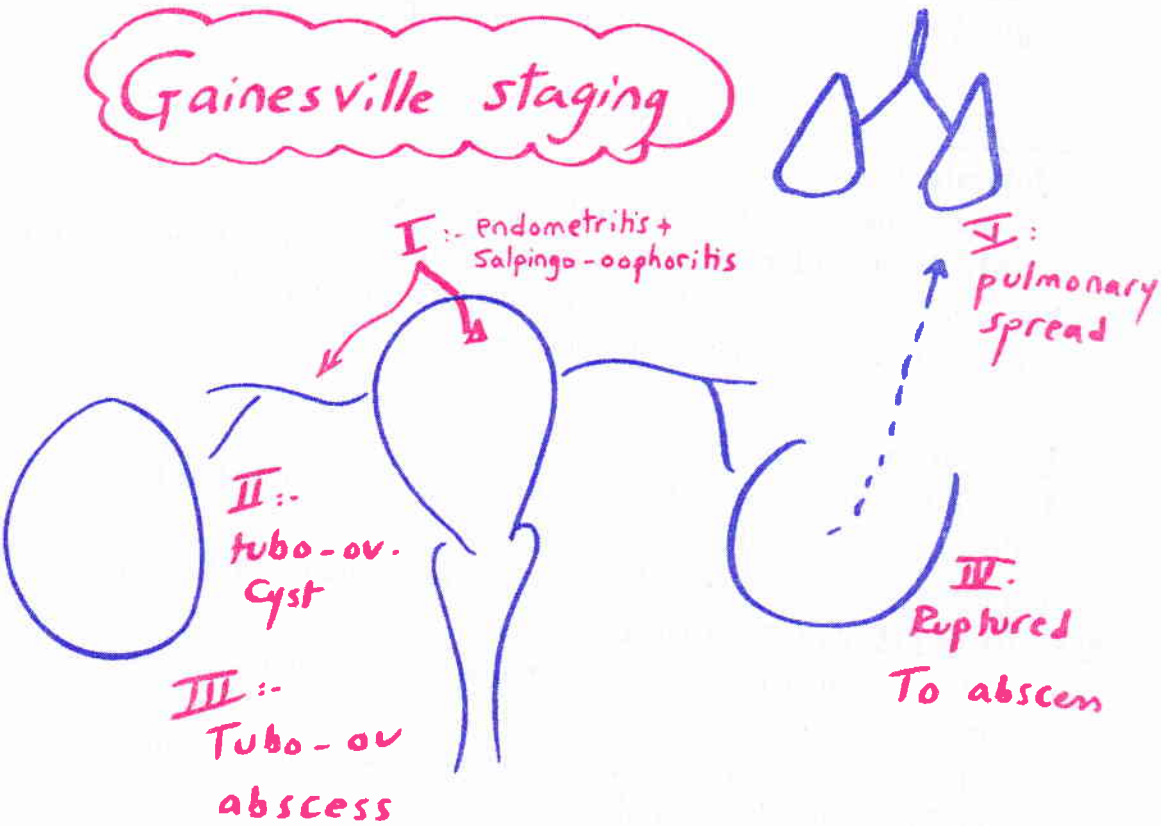

Acute PID

- **Pathology:**
  - **Acute endosalpinigitis:**
    - **Catarrhal** (low virulence with good immunity):
      - Acute mild infection of endosalpinx → serous exudate in lumen
      - Fate → complete resolution
    - **Suppurative**:
      - Acute pyosalpinx →pelvic abscess.
      - **Severe** infection of all layers → purulent exudate in lumen
      - Fate → chronicity & spread
  - **Acute perisalpingitis**: with adhesions to surrounding structures
- **Symptoms:**
  - **General:** fever, anorexia, headache, malaise
  - **Abdominal**: Acute lower abdominal pain
  - **Vaginal**: congestive symptoms; pain, bleeding, purulent discharge
- **Signs**:
  - **General:** Fever, rigors, tachycardia.
  - **Abdominal**:
    - **Tenderness**, rigidity, rebound tenderness
    - **Maximal tenderness** is 3 cm above midinguinal point (tubal point)
  - **P/V**: cervical motion tenderness (Chandelier sign), tender masses, tender adnexa, mucopurulent discharge
- **Investigations:**
  - **Laboratory:** ↑TLC, ESR, CRP
  - **U/S:** fluid filled mass (esp if pain prevents PV examination) & to follow up the size tubo-ovarian masses
  - **Laparoscopy**: (Gold standard in doubtful cases) inflamed tubes oozing pus.
- **Severity of PID by laparoscopy** مهمه
  1. Mild: erythema, edema, no spontaneous purulent exudates, tubes freely mobile
  2. Moderate: pus, erythema, & edema is more marked, tubes may not be freely movable & fimbrial end may not be patent
  3. Severe: Pyosalpinx, inflammatory complex or abscesses
  - **Culture** for the discharge, peritoneal cytology
  - **Endometrial** biopsy
  - **B-HCG** to exclude ectopic pregnancy
- **Differential diagnosis:** causes of acute abdomen

- **Complications**
  - Recurrence (20%), chronicity especially with chlamydia (very mild symptoms)
  - Ectopic pregnancy, Infertility
  - Chronic pelvic pain, menstrual irregularity
  - Spread: pelvic abscess, peritonitis, thrombophlebitis, septicemia.
- **Treatment:**
  - **Prophylactic**: avoid promiscuity, aseptic delivery & instrumentation
  - **Active (for both partners):**
    - ✱ **General:**
      - B → bed rest in Fowler position.
      - D → good diet
      - C → cold compresses
      - AN→ antibiotics
      - F → IV fluid
      - AN → analgesic
      - AN → antipyretics
    - ✱ **Antibiotic therapy according to CDC** المحاضرات و الكلام الجديد:

Oral regimen

Regimen A حفظ:

Ofloxacin 400 mg + Metronidazole 500 mg orally twice a day for 14 days

Regimen B:

Cefoxitin 2 g + probenecid 1g X 1 or Cefrtriaxone 250 mg IM X 1 (once) + Doxycyclin 100 mg orally twice daily for 14 days

Parenteral regimen

Recommended Parenteral Regimen A (RCOG, 2003)

Cefotetan (Cefotan) 2 g IV / 12 h or **Cefoxitin (Mefoxin)** 2 g IV/ 6 h + **Doxycyclin 100 mg orally or IV/12 h**

Parenteral therapy is stopped 24 h after drop of fever & oral Doxycyclin (100 mg twice a day) should continue to complete 14 days of therapy.

Recommended Parenteral Regimen B

Clindamycin 900 mg IV every 8 hours +
Gentamycin loading dose IV or IM (2 mg/kg of body weight)
Followed by a maintenance dose (1.5 mg/kg) every 8 h.

Parenteral therapy is stopped 24 h after ↓ of fever & oral Doxycyclin 100 mg / 12h or clindamycin 450 mg orally 4 times a day to complete a total of 14 days of therapy.

- **Indications of hospitalization:**
  - In severe cases
  - NP
  - Tubo ovarian complex or ruptured TO complex
- **Surgical:**
  - TOA: U/S guided aspiration or Laparoscopic aspiration
  - Rupture TOA: laparotomy: drainage & peritoneal toilet
  - Pelvic abscess: drain by laparotomy or posterior Colpotomy
  - TAH + BSO: if not seeking for pregnancy or very severe cases
  - Thrombophlebitis: **heparin**
- **Treatment of specific infections:**
  - **Chlamydia:** azithromycin 1 g single dose
  - **Gonorrhea:** single dose ceftriaxone 250 mg IM or cefixime 400 mg Ciprofloxacin 500 mg (oral)

Chronic PID

Pathology:

1. **Hydrosalpinx**:
   - **Catarrhal inflammation** → occluded fimbria → distension by serous fluid → pelvic pressure & pain, sometimes it escapes from uterine end → intermittent Hydrosalpinx → Retort shaped tube by HSG
   - It is liable to torsion, infection, rupture
   - **Tubo-ovarian cyst:** Hydrosalpinx communicating with ovarian cyst.
2. **Pyosalpinx**:
   - **Suppurative inflammation** → blocked tube (non visualized by HSG)
   - It is less liable to torsion, infection, rupture (adhesions).
   - **Tubo-ovarian abscess:** pyosalpinx communicating with ovarian cyst.
3. **Chronic interstitial salpingitis**, perisalpingitis with peri-tubal adhesion
4. **Salpingitis isthmica nodosum:** Multiple bilateral nodules especially in isthmus
   - DD: TB, bilhariziasis, gonococci, chlamydia, endometriosis, may be in normal FT
5. **Fitz-Hugh-Curtis S:** Perihepatitis + perisalpingitis (Violin strings like bands between the tube & liver)
6. **Tuberculous salpingitis (this PID can occur in virgins):**
   - Adhesive type (dry): thick, nodular tube with tubercles &calcification,
   - Exudative (ascitic type): thick agglutinated fimbria ,pale with caseation
7. **Bilharizial salpingitis:** interstitial & perisalpingitis, mucosa is not affected and no affection of fimbrial end → sandy patches, nodules, calcification

- **Symptoms:**
  - **Acute attack:** Recurrent
  - Pain: 4D
  - Cachexia
  - Discharge
  - Infertility
- **Signs:**
  - **General**: ill health, TB toxemia
  - **Abdominal**: lower abdominal tenderness, TB peritonitis, bilhariziasis (HSM)
  - **Vaginal:**
    - Cx motion tenderness, fixed RVF, tubo-ovarian complex
    - Vaginal discharge
- **Differential diagnosis**: chronic pelvic pain, endometriosis, cancer ovary, TB
- **Investigations**:
  - **To diagnose**: **Blood**: ESR, CRP, leucocytosis

    Culture: from endocervix, rectum (chlamydia, gonorrhea)

    US: masses & follow up of the size of the masses

    Laparoscopy: in doubtful cases & if no response for 72 h
  - **Etiology**: TB (chest X ray, tuberculin test)
  - **Complications**: as infertility → HSG, laparoscopy
- **Treatment**:
  - Prophylactic: Avoid risk factors + Proper treatment of acute cases
  - Medial
    - Analgesic, anti-inflammatory drugs, antibiotic in acute exacerbation
    - Treatment of TB {INH 5mg/kg/d, rifampicin 10mg/kg/day}
    - Bilhariziasis (praziquantel 40mg/kg/day single dose)
  - Surgical:
    - Salpingectomy or TAH BSO (if bilateral in old patient)
    - **Tuboplasty in infertility**
      - Adhesiolysis
      - Resection reanastomosis
      - Reimplantation
      - Tubal cannulation
      - If failed all these methods → salpingectomy (مهمه جدا) + ART

oral N.B. **D.D. of acute pelvic pain?**

1- Rupture :- Cyst, uterus

2- Torsion :- Cyst, uterus

3- Degeneration :- Fibroid

4- Distension :- pyometra, acute UR.

5- Vascular :- mesenteric, sickle crises, hge in a cyst

6- Obstruction :- intestinal or ureteric

7- inflammatory :- PID, UTI, Appendicitis

oral N.B. **D.D. of chronic pelvic pain?**

Def: pain > 6 mon.

Causes: Laparoscopy is a must

- Gynecologic
  - Cyclic
    - Dysmenorrhea
    - cryptomenorrhea
    - PMT ∅
  - Acyclic
    - Any pelvic pathology
- non gyn.
  - urinary : infl, Tr, stones
  - intestinal : infl, Tr
  - Musc. skeletal : disc prolapse
  - systemic diseases : SLE
- idiopathic
- Psychogenic

SEXUALLY TRANSMITTED DISEASES

1- **Bacteria: gonorrhea, Gardnerella vaginalis**
2- **Chlamydia**
3- **Fungal: candida albicans**
4- **Protozoa: Trichomonas vaginalis**
5- **Viruses: human papilloma virus, herpes simple**

Neisseria gonorrhea

- **Etiology:**
  - **Organism**: Gm –ve kidney shaped intracellular diplococcic
  - **Mode of infection**:
    - Intercourse, contamination from infected towels, instruments
    - During labor: neonatal conjunctivitis
- **Pathology:**
  - **Incubation period**: 3-7 days (male to female > female to male ☺)
  - More in black races with low social class
  - It affects only columnar epithelium
    - **1ry sites**
      - Urethra + Skene, Bartholin glands & endocx → angry red cervix + mucopurulent discharge (Sanger`s △)
    - **2ry sites**:
      - Rectum: proctitis
      - Pharynx after oral sex: pharyngitis,
      - Eyes: ophthalmia neonatorum /conjunctivitis in adults.
      - Tubes (PID), peritoneum (Fitz-Hugh-Curtis syndrome).
      - Vulvovaginitis (in Prepubertal or postmenopausal)
    - **Disseminated gonorrhea disease**:
      - Endocarditis, septic arthritis, meningitis, iridocyclitis & dermatitis
- **Symptoms**:
  - Asymptomatic
  - Lower abdominal pain, mucopurulent discharge, UTI, conjunctivitis
- **Signs**: Mucopurulent discharge + cervix is red hot eroded (angry red)
- **Investigations**:
  - **Smear:** gram – ve IC kidney shaped diplococcic
  - **Culture**: Thayer Martin or New York city media, chocolate agar
  - **Serology**: CFT
  - **Antigen detection**: ELIZA (Gonozyme) from 1ry sites.

Treatment:

- **Uncomplicated:**
  - **Ampicillin + probenecid**
  - **Procaine penicillin** 4.8 mu IM once + 1g **probenecid** (↓ renal excretion of penicillin)
  - **Tetracycline or erythromycins** 500 mg/6hrs for 7 days (in resistant cases, allergic to penicillins & associated chlamydia)
  - **Spectinomycin** 2 g single dose
  - **Ceftriaxone (Rocephin) 250 mg single dose IM**
- **Complicated**
  - **Medical:** Penicillin G 10 million U/day till improvement then ampicillin, tetracycline or erythromycin 500mg 1x4x7
  - **Disseminated G Disease**: crystalline penicillin 10.000.000IU IV then ampicillin or erythromycin 500 mg orally, ceftriaxone 1gm /6hrs for 5days, cefotaxime :1gm IM/8hrs for 5 days
  - **Surgery**: drain a Bartholin abscess or cauterization of chronic cervicitis

Chlamydia

Etiology:

- **Organism**: intracellular organisms
  - **Similar to bacteria:**
    - Contains DNA & RNA
    - Divides by binary fission
    - Sensitive to antibiotics
  - **Similar to viruses:**
    - Obligatory intracellular (needs tissue culture)
    - Intracellular inclusion bodies.
- **Mode of infection**:
  - Intercourse, contamination from infected towels, instruments
  - During labor: neonatal conjunctivitis

Pathology:

- **Incubation period**: 1-2 weeks.
- It remains **silent** for months or years
- It affects **5% of non preg females**
- **however** it is asymptomatic in 50%

- 15 serotypes
  - **A, B & C**: trachoma
  - **Chlamydia causing genital infection** (D – K):
    - Urethritis, Bartholinitis, cervicitis, peritonitis (Fitz Hugh Curtis), infertility, inclusion conjunctivitis.
    - **In pregnancy:** ectopic pregnancy, abortions, PROM, chorioamnionitis, preterm labor
    - **NN**: ophthalmia NN, pneumonia
    - **In males:** urethritis, epididymitis & conjunctivitis
  - **Lymphogranuloma venerium: L1 L2 L3**
    - **Single or multiple papules** → vesicles → pustule → ulcers → fistula + marked fibrosis
    - **Lymphadenitis**: Lymphadenitis (bubo): matted together with suppuration & sinus formation
    - **Chronic lymphangitis** → obstruction, edema, fibrosis, elephantiasis
    - **Proctocolitis** with diarrhea & fistulas

- **Symptoms**:
  - Asymptomatic
  - Lower abdominal pain, mucopurulent discharge, UTI, conjunctivitis

- **Signs**: Mucopurulent discharge + cervix is red hot eroded (angry red)

- **Investigations**:
  - **Smear** Cellular atypia, intracellular inclusion bodies
  - **Cx mucus** > 10 pus cell/oil immersion field
  - **Culture:** McCoy media (most reliable) but takes 2 weeks
  - **Antigen detection: ELISA** (most rapid)
  - **PCR, DNA probing** (reliable a tissue culture)
  - **Serology: MIFT, CFT**

- **Treatment:**
  - **Azithromycin:** 1gm single dose
  - **Tetracycline or erythromycin**: 500 gm 1 X 4 X 14
  - **Doxycyclin**: 100 mg 1 X 2 X 14
  - **Clindamycin**: 300 mg 1 X 3 X 14

Human papilloma virus

- **Etiology:**
  - **Organism:**
    - **DNA** papova virus, Now 100 types are present
    - **Low risk:** 6,11,42,43,44 → vulvitis
    - **Moderate risk:** 31,33,35,51,52 → CIN, VIN, VaIN
    - **High risk:** 16,18,54,56
  - **Mode of infection:**
    - Intercourse, contamination from infected towels, instruments
    - During labor: cord papilloma
- **Pathology:**
  - **IP:** 3 wks – 8 months
  - It is the commonest sexually transmitted virus
  - It forms genital warts & condylomas:
    - Condyloma accuminata (cauliflower masses): on vulva, perineum & anus
    - Flat & inverted condyloma: on cervix
    - Growth increases in pregnancy, COC, DM, immunosuppression.
    - Usually associated with other STD
- **Symptoms:**
  - **Warts** (condyloma accuminata in labia vulva, perineum & flat & inverted condyloma on cervix) ± 2ry infection
- **Signs:** Warty lesion may change into intraepithelial carcinoma
- **Complication:**
  1. Related to malignant & premalignant conditions of cx, vagina, vulva (16,18)
  2. Recurrence (it occurs in 6% of population & recurs in 60%)
  3. Neonate: may lead to laryngeal papilloma
- **Investigations:**
  - **Dot blot test** for DNA, RNA (fast non specific)
  - **Southern blot test** (specific)
  - **Smear:** koilocytes
    - Multinucleated, vacuolated cells with
    - Pronuclear halo
    - Amphophilic cytoplasm
  - **PCR, no culture**
  - **Colposcopy, PAP smear** to exclude malignancy
  - **Biopsy:** acanthosis, papillomatosis, hyperkeratosis (resembles malignancy)

D.D. of genital warts:

1- HPV (Condyloma accuminata)

2- Syphilis (Condyloma lata)

3- Chlamydia (Lymphogranuloma venereum)

4- Bilharziasis

- **Treatment:**
  - **Local destruction:**
    - **Chemical cautery:**
      - **Imiquimod 5 %** 3 times/wk for 16 wk can be repeated for an additional course
      - **Podofilox 0.5 %**: twice daily for 3 days followed by 4 days free (can be repeated 3 more times). Not in pregnants or vagina (toxic).
      - **Trichloracetic acid** 75 – 90% applied weekly 6 times
    - **Cryo, LASER or** electrocautery
  - **Surgery:**
    - **Simple** removal or simple vulvectomy
    - **Biopsy** to exclude CIN
  - **Other antivirals:** interferon,5FU, immunovir tablets
  - **In pregnancy**: C. section to avoid NN laryngeal papilloma
  - **Recently:** quadrivalent vaccine is available

Herpes Simplex

- **Etiology:**
  - **Organism**:
    - **DNA** virus
    - **Type I**: 20 – 25 %
    - **Type II:** commonest herpetic genital infections
  - **Mode of infection**:
    - Intercourse, contamination from infected towels, instruments
    - During labor: neonatal encephalomyelitis.
- **Pathology**:
  - **IP:** 5 – 7 days
  - Affects the vulva, perineum, vagina, cervix, urethra & oral cavity
  - Usually associated with other STD
- **Symptoms:**
  - **1ry infection:** occurs in a patient has no antibodies
    - **Generally**: FAHM (flu like)
    - **Locally**: painful vesicles that rupture leaving a shallow small painful ulcers + inguinal LN
    - **Fate**: heals rapidly & virus is dormant in sacral plexus (dorsal root ganglion)

- **Recurrent infection:** duration is shorter & milder → small vesicle on erythematous base with no general manifestations & no LN affection.

Complication:

- 2ry infection
- Urinary retention if involved sacral nerve roots (dorsal radiculitis)
- In pregnancy may lead to abortions & preterm labor
- On NN encephalomyelitis (elective CS unless ROM > 4 hr → considered already infected)

Investigations:

- **Pap smear** → multinucleated cells containing eosinophilic intranuclear inclusion bodies
- **Culture** on chorioallantoic membrane
- **Serological test** CFT for Ab/titre
- **Herpes antigen detection**

Treatment:

- **Symptomatic, antibiotics if 2ry infection**
- **Antiviral**: acyclovir 200 mg 3 times /d for 10 d (most used).
- **Recurrent**:
  - 200 mg 5 times /day or 400 mg TID or 800 mg BID Famcyclovir or valacylcovir for 5 days.
  - Interferon.
  - 70 % of women have a recurrence within 1 year
- **Women with multiple recurrences**: long term suppression with acyclovir 400 mg twice daily x 1 y

Chronic granulomatous diseases

1- Syphilis

- **Etiology:**
  - **Organism**: Treponema pallidum (a spirochete)
  - **Mode of infection**: Intercourse, transplacental

- **Clinical picture:**:
  - **Congenital:** abortion, IUFD, malformations
  - **Acquired:**
    - **1ry (9-90d):** hard chancre; painless single papule + rubbery mobile non tender LNs)
    - **2ry (6w-6m):** condyloma lata; raised grayish papules at mucocut junction + LNs
    - **3ry:** gumma
      - **Early latent** (within 4 yr of 2ry)
      - **Late latent** (>4y) neurosyphilis or cardiovascular syphilis

- **Investigations**:
  - **Dark** field ex. In 1ry &2ry → spirochete
  - **Serological:**
    - **Non specific:** WR, Khan, VDRL (+ve after 2 weeks from chancre, may be false + ve in some diseases in other diseases as SLE)
    - **Specific: TPIT, TPHT, FTA**

- **Treatment:**
  - **1ry, 2ry, latent (duration < 1 year)**:
    - Benzathine penicillin G: 2.4 mu IM single injection
    - Procaine penicillin 1million unit /d for 10 days
    - Tetracyclines, erythromycin, cephalosporins (500 1x4x15)
  - **If > 1 year** 2.4mu/w Benzathine penicillin for 3 successive weeks
  - **In case of allergy:** erythromycin or tetracycline (500 x 4 x 2 w)
  - **Neurosyphilis**: penicillin G 12-24 mu/d IV for 10 d then Benzathine penicillin 2.4mu/w IM for 3 successive weeks

Tuberculosis

Etiology:

- **Organism**: mycobacterium tuberculosis (human bacillus > mycobacterium bovis)
- **Mode of infection**:
  - post 1ry (1ry is usually lungs)
  - By blood (90%)☺, lymph or ascending (with semen) or peritoneal spread

Pathology:

- **Tubes 100%** → adhesive or exudative:
  - Perisalpingitis → military TB with adhesions
  - Interstitial salpingitis, salpingitis isthmica nodosum
  - Endosalpingitis
- **Uterus** (50%): tubercles, caseation, Asherman syndrome
- **Ovaries** (25%): granulomas, caseation & fibrosis
- **Vulva, vagina & cervix** (5%): polypi or ulcers (serpiginous outline, undermined edge, yellow floor, not indurated)

Symptoms (↑nowadays):

- Family history or endemic area.
- General: night fever, night sweat – loss of weight & appetite
- Abd: abdominal pain
- Vaginal: 1/3 of case: no abnormality
  - Menstrual:
    - Amenorrhea, Hypomenorrhea (↓general condition, anovulation, Asherman)
    - may be normal menses or even menorrhagia
  - Congestive symptoms: Pain, Discharge
  - Infertility (5% of infertile)
  - **Other**: vulval, vaginal, cervical lesion

Signs:

- **General**: chest lesions
- **Abdominal**: masses lymph nodes
- **Local**: tubercles in vulva, vagina & cervix fixed RVF, adenxal & DP nodules

Investigations:

- **General**:
  - ↑ TLC (lymphocytosis), ESR, chest X ray + renal inv
  - Tuberculin test significant if –ve.
- **Vulva, vagina & cervix**: biopsy from lesions

- **Endometrium:**
  - **Curettage**:
    - **Culture**: Lowenstein Jenesn or dorset egg media
    - **Zeil Neilson stain**: bacilli + excess lymphocytes
  - **US, Hysteroscopy**
- **Tubes:**
  - **HSG**: uterus (Asherman synd, calcifications), Tube rigid lead pipe, sausage shaped, hydrosalpinx, usually patent
  - **Laparoscopy** (sausage shaped, no pyosalpinx, tubercles, calcifications intestinal affection & biopsy)

- **Treatment:**
  - **Medical:**
    - INH (5mg/kg/d), Rifampicin (10mg/kg/d), Ethambutol (15mg/kg/d) ± Streptomycin (1g IM/d) for 6-9 months
  - **Surgical:** TAH + BSO (no tubal microsurgery) if:
    - No response to medical treatment
    - Enlarging mass, Perimenopausal bleeding.
    - Fistulas & sinuses or delay chest healing.

Schistosoma

- **Pathology**
  - Usually due to S.haematobium > mansoni
  - More common → perisalpingitis & interstitial salpingitis
  - Route: is communication between vesical, rectal & vaginal plexus
  - Types:
    - **Vulva:** polyps – ulcers
    - **Vagina:** polyps – sandy patches
    - **Cx:** polyps – sandy patches - nodules

-
  - Manifestations of urinary or GIT bilhariziasis
  - Infertility (uncommon), discharge, menstrual disorders
- **Signs**: Lesions in the vulva & vagina, Fixed RVF
- **Investigations**
  - Stool & urine ex: ova, CFT
  - Colposcopy, hysteroscopy, cystoscopy, laparoscopy → biopsy
- **Treatment**
  - Praziquantel 20-60 mg/kg single dose
  - Tuboplasty: good result with surgical excision of residual lesions

LEUCORRHEA

◈ White non infective vaginal discharge due to ↑ normal secretions or transudation.

◈ What are the normal defensive mechanisms of ♀ genital system?

Classification:

I) According to Cause:

A. ↑ normal secretion or transudation (True leucorrhea):

* Puberty, Premenstrual, Pregnancy, Puerperium (lochia alba), Pelvic congestion, Hormones especially Estrogen

	Trauma	Inflammatory	Neoplastic	Miscellaneous
Vaginal	F.B. or infected laceration	TV. + Monilia	Adenosis	Fistula
Cervical	Ulcers, polyps, erosions	Cervicitis	Infected tumors	
Uterine	F.B., IUD (leucorrhea & infection)	Puerperal sepsis	Infected fibroid, cancer body	Pyometra Pregnancy: ROM, V Mole
Tubal		Intermittent hydrosalpinx PID → Congestion		
Pelvic		Abcess:If evacuated or opens vaginally		

II) According to Etiology:

- General causes of pelvic congestion
- Physiological.
- Traumatic, Displacements, Inflammatory & Neoplastic

III) According to character: (causes of leucorrhea = causes of vaginal discharge)

1- **Whitish:** True leucorrhea (no Infection), Monilia
2- **Mucoid:** Vaginal adenosis, Virus cervicitis & Non-infective erosion.
3- **Serous (Watery):** ROM, VM, Urinary fistula, hydrosalpinx, early cancer cervix.

4- **Mucopurulent (mucous secreting gland is affected by a pyogenic organisms):** Mixed vaginitis, Non-specific cervicitis, Bartholinitis
5- **Purulent (any sever infection):** Gonorrhea, Vaginitis, Endometritis, and Septic abortion, pyometra, and PID & Pelvic abscess if open into vagina.
6- **Sanguineous:** Foreign body, Ulcers & Senile vaginitis, Polyps, Erosion, Ulcers of the cervix & Cancer of vagina, CX, Body.
7- **Yellowish or Greenish:** TV, Non-specific vaginitis.
8- **Offensive:** Trauma, Infection, Tumors & Fistula.

How to investigate a case of vaginal discharge:

⇨ **Age:** ☆ T. V & Monilia is common causes in adult. ☆ Bloody discharge after menopause may be due to malignancy. ⇨ **Marital status:** ☆ Post partum & post abortion infection. ☆ Gonorrhea after S.I. ⇨ **Menstrual History:** ☆ Congestive dysmenorrhea ☆ Pregnancy (VM) ⇨ **History of present illness:** ☆ Discharge → onset, course, odor, relation to menstruation. ☆ Associated symptoms: pruritis, dyspareunia, urinary or GIT symptom.	⇨ No intercourse or vaginal douches for 24hrs, also no lubricant is used during PV ⇨ Vulva is inspected for discharge, Bartholinitis, urethritis, the urethra is milked downward (Gonorrhea) ⇨ **Speculum Ex.:** discharge is obtained & examined for amount, character, color & odor. Vaginal wall is inspected for vaginitis, ulcers & tumors. ⇨ **Bimanual Ex.** Is done after speculum removal	1- Fresh wet drop method for TV. 2- Stained film for monilia (methylene blue) 3- Discharge collected from urethra, vagina & cervix are collected for bacterial EX. & culture & sensitivity. 4- Vaginal cytology (infection or malignant cells) 5- Biopsy from suspicious ulcers or tumors. 6- in infant X-ray for a F.B

Treatment:

- Treatment of the cause (gonorrhea, chlamydia, candida, TV, BV اكتب علاجهم)
- Local cleanliness of genital tract.